

Pyloric Sympathectomy: A Novel Way to Get Pylorus Relaxation? Report of Two Bariatric Cases

Victor Ramos Mussa Dib¹, Carlos Augusto Scussel Madalosso², Rui Ribeiro³, Paulo Reis Esselin de Melo^{4,5}, Fernando Fornari^{6,7} 

¹Victor Dib Institute, Manaus, Brazil

²Gastrobese Clinic, Passo Fundo, Brazil

³Lusíadas Amadora Hospital, Lisboa, Portugal

⁴Paulo Reis Institute, Goiânia, Brazil

⁵Alfredo Nasser University Center (UNIFAN), Goiânia, Brazil

⁶Faculdade de Medicina, Universidade de Passo Fundo, Passo Fundo, Brazil

⁷Faculdade de Medicina, Universidade Federal da Fronteira do Sul, Chapecó, Brazil

Email: victormussadib@gmail.com

How to cite this paper: Dib, V.R.M., Madalosso, C.A.S., Ribeiro, R., de Melo, P.R.E. and Fornari, F. (2024) Pyloric Sympathectomy: A Novel Way to Get Pylorus Relaxation? Report of Two Bariatric Cases. *Surgical Science*, 15, 381-395.
<https://doi.org/10.4236/ss.2024.156035>

Received: June 3, 2024

Accepted: June 17, 2024

Published: June 20, 2024

Copyright © 2024 by author(s) and Scientific Research Publishing Inc. This work is licensed under the Creative Commons Attribution International License (CC BY 4.0).
<http://creativecommons.org/licenses/by/4.0/>



Open Access

Abstract

Objective: This case report aimed to demonstrate a possible neuromuscular effect of pyloric sympathectomy on the pylorus motility, leading to its permanent relaxation, observed in two bariatric surgical cases, one primary and the other, revisional. **Background:** Pyloric sphincter is a physiological barrier to free gastric emptying. In sleeve gastrectomy and in Roux-en-Y gastric bypass revisions, that put the remnant stomach in transit, the pylorus can contribute to generate a high intragastric pressure, which could lead to acute gastric fistulas and/or chronic gastroesophageal reflux disease. The possibility of functionally relaxing the pylorus, promoting intragastric pressure reduction, could represent a protective maneuver against these complications. **Methods:** We describe herein a surgical maneuver applied in two cases of bariatric surgeries, with the intention of facilitating antrum-duodenal region exposure, in a sleeve gastrectomy and in a Roux-en-Y gastric bypass conversion to SADI-S. For this, a ligation of terminal peripyloric vessels was done, allowing a passage of a tape, which surrounded the pylorus, for its traction. In both cases, 30-day and 1-year endoscopic evaluations were done, to assess esophagitis signs, anastomosis healing and anatomical pouch aspect. A clinical evaluation was also done, to assess gastroesophageal symptoms (validated questionnaire). **Results:** In the postoperative endoscopic evaluations, no esophagitis were observed in any case and the gastric pouches had normal aspect, with the expected anatomical findings, compatible with the surgeries performed.

The anastomosis healed without problems, in the revisional case. Interestingly, in both cases, it was observed a complete pyloric sphincter relaxation, which lasted until 1-year endoscopic evaluation. There were no fistulas, nor esophagitis in any of these cases. Clinically, there were no symptoms of gastroesophageal reflux disease (validated questionnaire). **Conclusion:** The observation of a pyloric durable atomy, that followed peripyloric dissection and vessels ligation (arterial branches), with its concomitant sympathectomy, can represent a new way of decompressing gastric chamber, either in primary or revisional bariatric surgeries. This maneuver can be protective against acute fistulas and gastroesophageal disease. Additional studies are necessary to confirm this hypothesis.

Keywords

Roux-en-Y Gastric Bypass, Sleeve Gastrectomy, Sympathectomy, Bariatric Surgery

1. Introduction

Obesity is an epidemic worldwide and bariatric surgery is the best treatment for patients who have morbid obesity. Sleeve Gastrectomy (SG) is the most frequently performed bariatric procedure, surpassing Roux-en-Y Gastric Bypass (RYGB) in 2013 [1] [2].

Although SG carries the advantages of preserving the continuity of the entire gastrointestinal tract, reducing nutritional issues, it's alluded as a refluxogenic operation, leading to high indices of gastroesophageal reflux disease (GERD) [3] [4] [5]. The reduction in gastric complacency is one important factor related to GERD after SG. The pylorus can influence in GERD development, as it causes an intermittent barrier to free gastric flow, contributing to the increased gastric chamber pressure [6].

Concerning RYGB, it represents the second most frequently performed bariatric surgery in the world [1]. This technique has shown good long-term results, regarding weight loss and comorbidities control [7]. However, many authors have demonstrated high indices of failure, showing weight regain in superobese patients [8]. In such situation a revisional surgery is a plausible treatment alternative. There are many surgical options, but the most effective is conversion to BPD-DS or SADI-S [9]. These conversions are technically cumbersome, with relatively high incidences of complications, mainly related to the gastro-gastric anastomosis (GGA), a step of this operation [10] [11]. Again, the pyloric sphincter, sometimes spastic, could contribute to increase intragastric pressure, which could lead to gastro-gastric fistula occurrence.

In this article, two cases of bariatric surgeries are reported, one primary (SG) and other, revisional (conversion from RYGB to SADI-S, due to weight regain). In both cases, as a surgical tactic, the pyloric region was dissected, with terminal

pyloric arterial branches ligation, making it possible to encircle the pylorus with a tape, for field exposure purposes. It was observed, in the postoperative endoscopy of both cases, a complete and permanent pylorus relaxation, lasting until one-year follow-up. This finding can represent the effect of pyloric sympathectomy which is associated with pyloric blood vessels ligation. Opening the pylorus could diminish intragastric pressure and represent an important surgical step to reduce GERD related to SG and GGA fistulas, related to RYGB conversion to SADI-S. To confirm this hypothesis, further investigation is necessary.

2. Patient Consent

The patients signed a Free and Informed Consent Form (FICF) and were informed about the procedure they would be undergoing, which would be a Sleeve Gastrectomy and a RYGB conversion to SADI-S. All their queries about the procedures were answered, in the presence of a companion. It was explained about possible intra and postoperative complications, as well as the possibility of changes in surgical planning, in case of intraoperative unexpected findings or interurrences. An informed consent was signed by the patients, giving permission to use these cases details and images of the surgeries by the surgeon, for scientific purposes, preserving their identities. All the human data was performed, in accordance with the Declaration of Helsinki.

3. Cases Presentation

In this case report we present a tactical maneuver, that is a pylorus dissection through its vessels and adhesions ligation, followed by a passage of a tape, used to pull the sphincter to get an adequate surgical field exposure. In the first case it was used in order to facilitate the first antral staple shot, in a Sleeve Gastrectomy. In the second, the purpose was to improve the retro duodenal visualization for duodenal transection, in a RYGB conversion to SADI-S. In 1-year endoscopic postoperative evaluation it was found a wide open pylorus, in both cases.

3.1. Case One

A 32y female patient, with long lasting grade II obesity (BMI-37.7 Kg/m²), hypertension (controlled with Atenolol 50 mg) and moderate hepatic steatosis was submitted to sleeve gastrectomy in November 2022. The patient had neither gastroesophageal reflux symptoms (validated questionnaire) nor endoscopic signs of hiatal hernia or esophagitis, on endoscopic evaluation. No other diseases or comorbidities were found.

The surgical time was 50 min, the length of hospital stay was 18h and the postoperative period was uneventful.

One year after surgery she reached a BMI of 29.5 Kg/m², with no GERD symptoms or any other complaints.

Case One—Surgical Steps

- Patient, team and trocars position are demonstrated in **Figure 1** and **Figure 2**;

- Ligation of branches from the right gastroepiploic vessels, from 4 cm proximal to the pylorus until 2 cm distal to it;
- Retropyloric dissection, releasing the posterior distal 2 cm of the antrum, the pylorus and the 2 cm proximal bulb, dissecting adhesions and ligating vessels, branches from the gastroduodenal artery;
- Ligation of branches from right gastric vessels, from 2 cm proximal to the pylorus, until 2 cm distal to it;
- A retro pyloric and retrobulbar window is created, where a tape is passed around, to be used for traction (**Figure 3**);
- The tape is pulled to the right, while the assistant performs an antral wall counter-traction to the left, exposing the proper spot for positioning the first staple, 3 cm proximal to the pylorus (**Figure 4**);
- A sequence of six 60 mm longitudinal stapling (J&J Echelon GST) starts 3 cm proximal to the pylorus, over a 32Fr Fouchet tube, positioned in the small gastric curvature, until reaching the His angle, using decreasing cartridge heights, from distal to proximal (**Figure 5**);
- The remnant stomach is then released by cutting branches of right and left gastroepiploic vessels and freeing adhesions.
- The staple line of gastric pouch is oversewn with prolene 3-0;
- The remnant stomach is extracted inside an Endo bag through the left flank wound; The trocars are retrieved and the wounds are closed.
- A scheme of the surgery is shown in **Figure 6**.

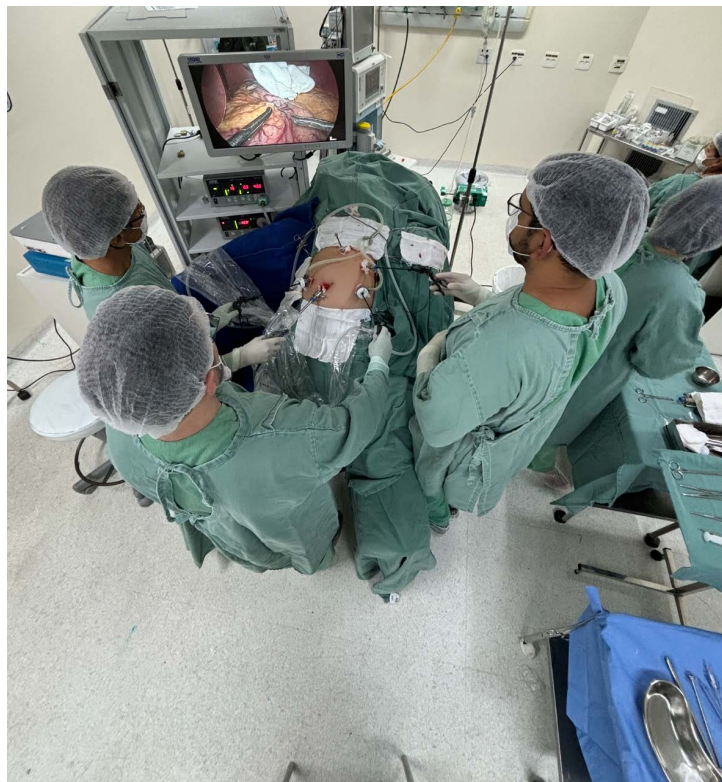

Figure 1. Team and patient position.

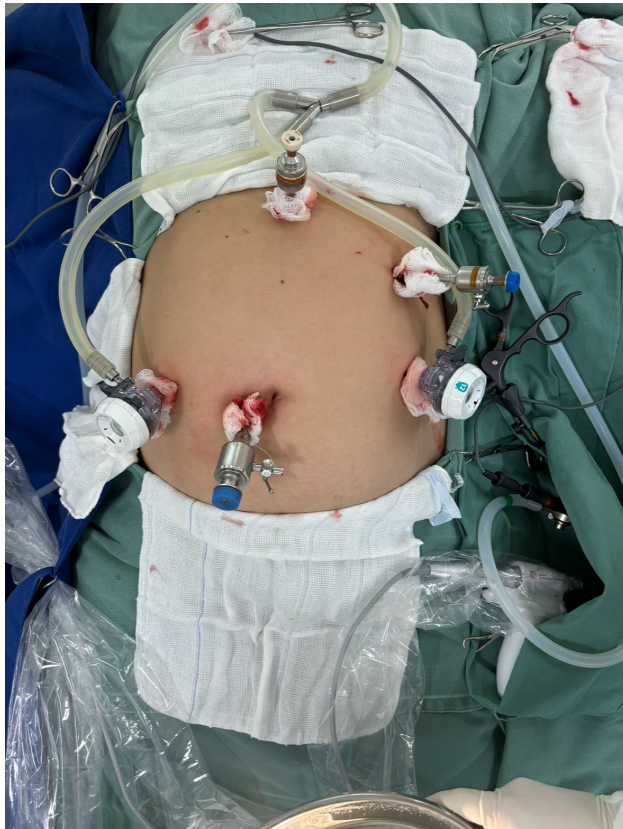

Figure 2. Trocars position.

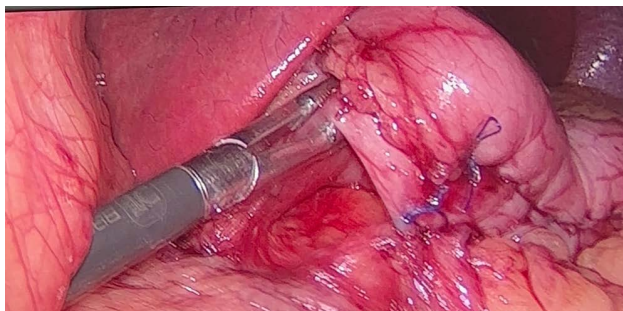


Figure 3. Retropyloric window.

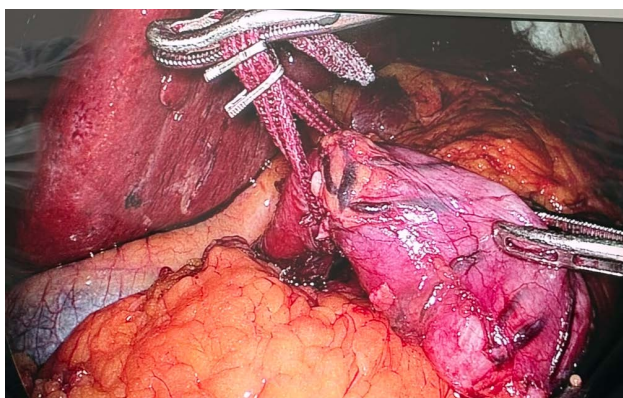


Figure 4. Bulb traction and counter-traction with a tape and a grasper.

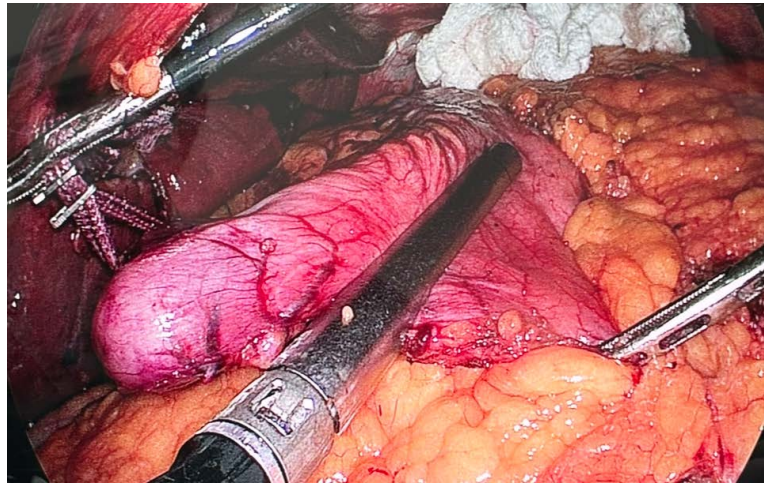


Figure 5. First gastric stapling.

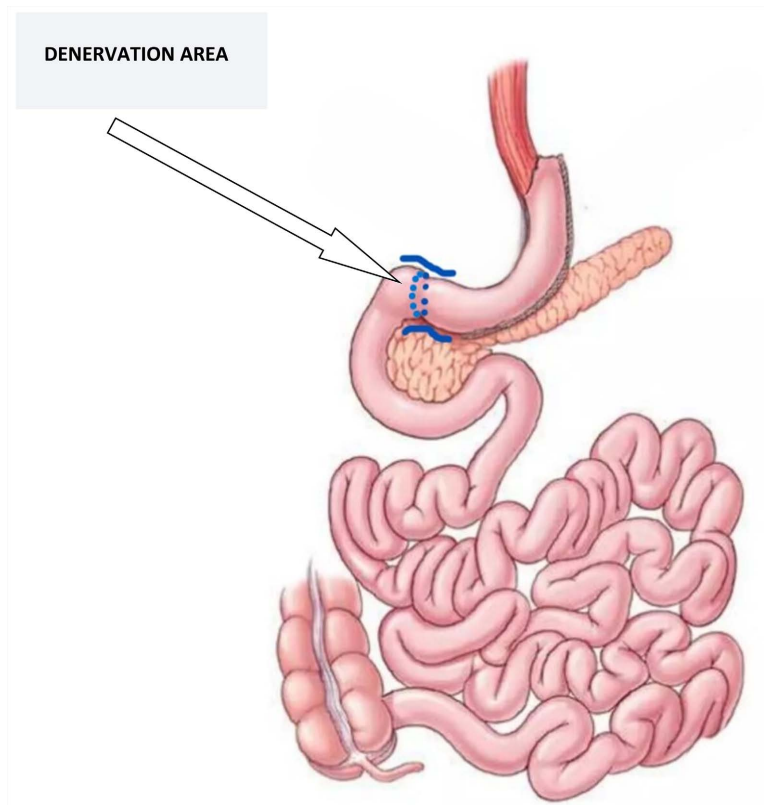


Figure 6. Surgical scheme of sleeve gastrectomy with pyloric sympathectomy.

3.2. Case Two

A 43y female patient was submitted to RYGB for a treatment of superobesity 8y before, with a BMI of 53.6 kg/m². She had moderate hepatic steatosis, sleep apnea and hypertension (Losartan 50 mg plus Atensin 100 mg). The nadir was reached 2y after surgery (BMI-37.4 Kg/m²), which lasted 1y, with comorbidities control, without pills. She started regaining weight, since then, reaching a BMI of 45 Kg/m², with comorbidities recurrence and return to medicines. After a 3

months multidisciplinary approach this patient was converted to SADI-S in January 2023. The surgical time was 185 min. She was discharged from hospital 48 h after the surgery and had an uneventful postoperative recover. One year after the surgery she reached a BMI of 28.7 Kg/m², with comorbidities resolution and no complaints.

Case Two—Surgical Steps

- Patient, team and trocars position are demonstrated in **Figure 1** and **Figure 2**;
- Ligation of branches from the right gastroepiploic vessels, from 4 cm proximal to the pylorus, until 2 cm distal to it;
- Retropyloric dissection, releasing the posterior distal 2 cm of the antrum, the pylorus and the 2 cm proximal bulb, dissecting adhesions and ligating vessels, branches from the gastroduodenal artery;
- Ligation of branches from right gastric vessels, from 2 cm proximal to the pylorus, until 2 cm distal to it;
- A retro pyloric and retrobulbar window is created, where a tape is passed around, to be used for traction (**Figure 7**);
- The tape is pulled proximally and anteriorly, to better expose the retrobulbar space, facilitating duodenal stapling and transection (**Figure 8**);
- The duodenum is transected 5 cm distal to the pylorus;
- The gastric pouch, the gastroenteric anastomosis and the alimentary limb, from the previous RYGB, are dissected;
- The gastric pouch is stapled just above the gastroenteric anastomosis and the alimentary limb is sectioned 10 cm distal to the gastroenteric anastomosis. The specimen is put in an Endo bag;
- The remnant stomach is released by sealing the vessels, branches from the gastroepiploic arteries and veins and by dissecting adhesions;
- The stapled pouch (from RYGB) is handsewn anastomosed to the remnant stomach, on the level of the staple line, from the primary surgery stapled site;
- A 32Fr bougie is passed through the anastomosis and positioned in the lesser curvature. The former remnant stomach is sleeved, lateral to the bougie, starting 5 cm from the pylorus until the gastric fundus, previously released;
- The specimen is put inside the Endo bag;
- A reinforcement of staple line with omentopexy is done with prolene 3-0;
- The biliopancreatic limb from the previous RYGB is stapled and sectioned, just proximal to the entero-enteric anastomosis;
- The alimentary limb, previously sectioned, is anastomosed with the biliopancreatic limb, reconstructing the intestinal transit continuity;
- The mesenteric space is closed;
- A handsewn omegaloop duodeno-ileal anastomosis is done, counting 3 meters of ileum from the ileocecal valve;
- All the specimens are retrieved; The trocars are removed and the wounds are closed.
- The scheme of the surgery is shown in **Figure 9**.

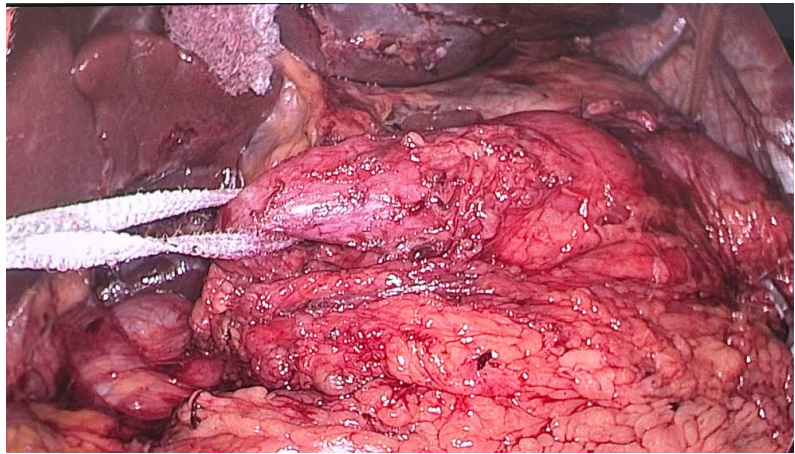


Figure 7. Retro duodenal space and duodenum traction.

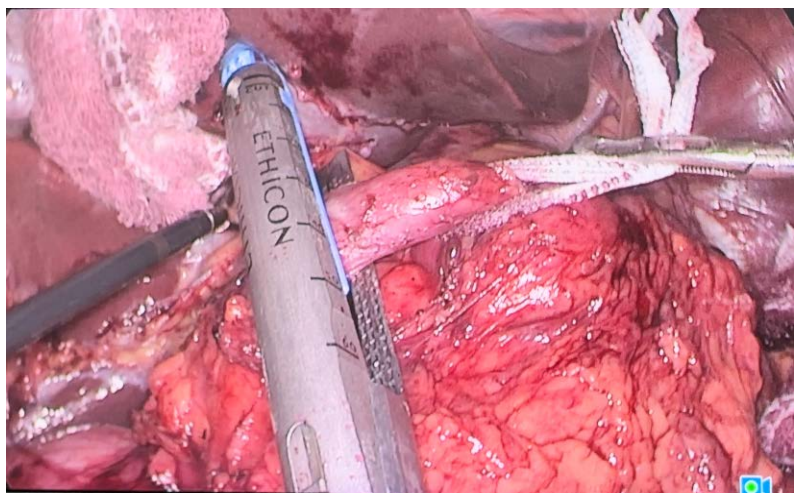


Figure 8. Tape proximal traction for duodenum septation.

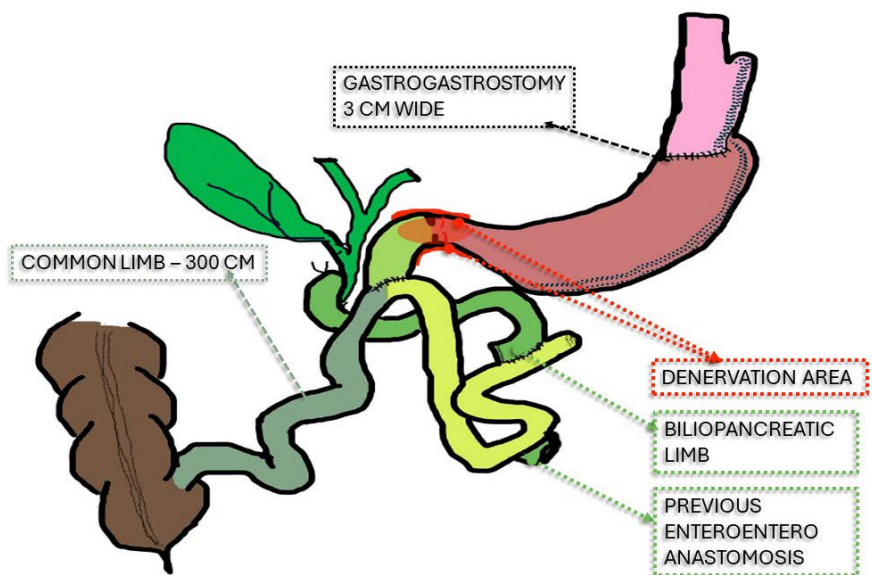


Figure 9. Surgical scheme of RYGB conversion to SADI-S, plus sympathectomy.

4. Postoperative Endoscopy

Both patients were submitted to endoscopic evaluations in first month and first year postoperative period. No alterations were found in early examinations. Below, the findings of 1-year evaluation will be reported.

4.1. Postoperative Endoscopy in Case One

In the one-year endoscopic examination, after Sleeve Gastrectomy plus “Sympathectomy”, there was neither esophagitis nor hiatal hernia and the gastric pouch had no dilation. One important observation was the permanently atonic and wide open pylorus, with no motility during one-minute endoscopic observation, without the use of drugs which could affect it. The bulb was normal (**Figures 10(a)-(d)**).

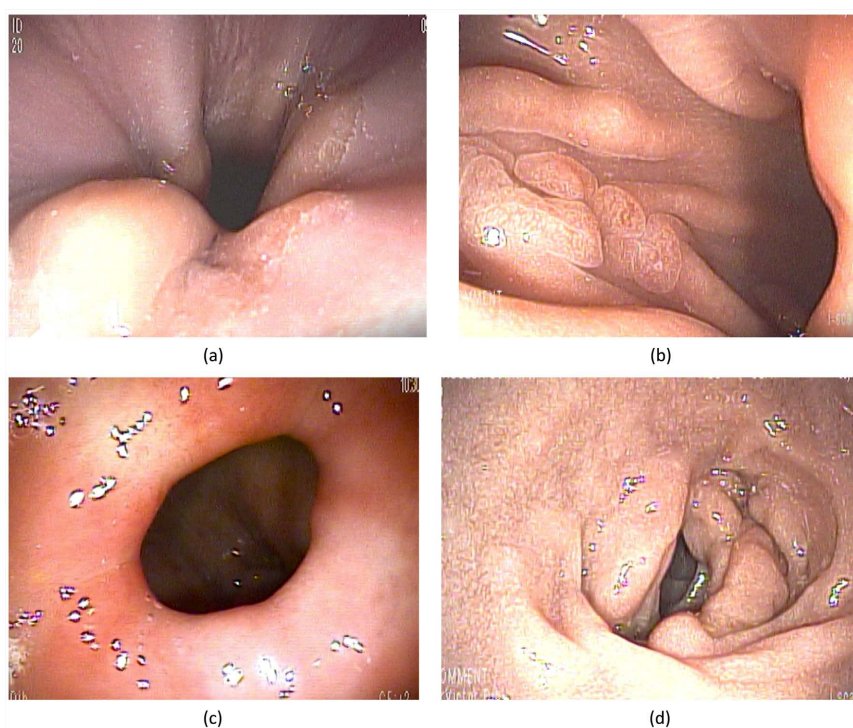


Figure 10. (a) Esophagogastric transition; (b) Sleeved stomach; (c) Wide open pylorus; (d) Normal duodenal bulb.

4.2. Postoperative Endoscopy in Case Two

In the one-year endoscopic examination, after conversion from RYGB to SADI-S, there was neither esophagitis nor hiatal hernia. The gastric pouch (from previous RYGB) normal and gastrogastrostomy was smooth and wide. The sleeved remnant stomach, put in transit, had no dilation or angulations. The pylorus was wide open and relaxed, with no contractions, during one-minute endoscopic observation, without the use of drugs which could affect it. The bulb was 5 cm long, with a wide end-sideduodeno-ileostomy. Both afferent and efferent ileal limbs had normal endoscopic aspect (**Figures 11(a)-(g)**).

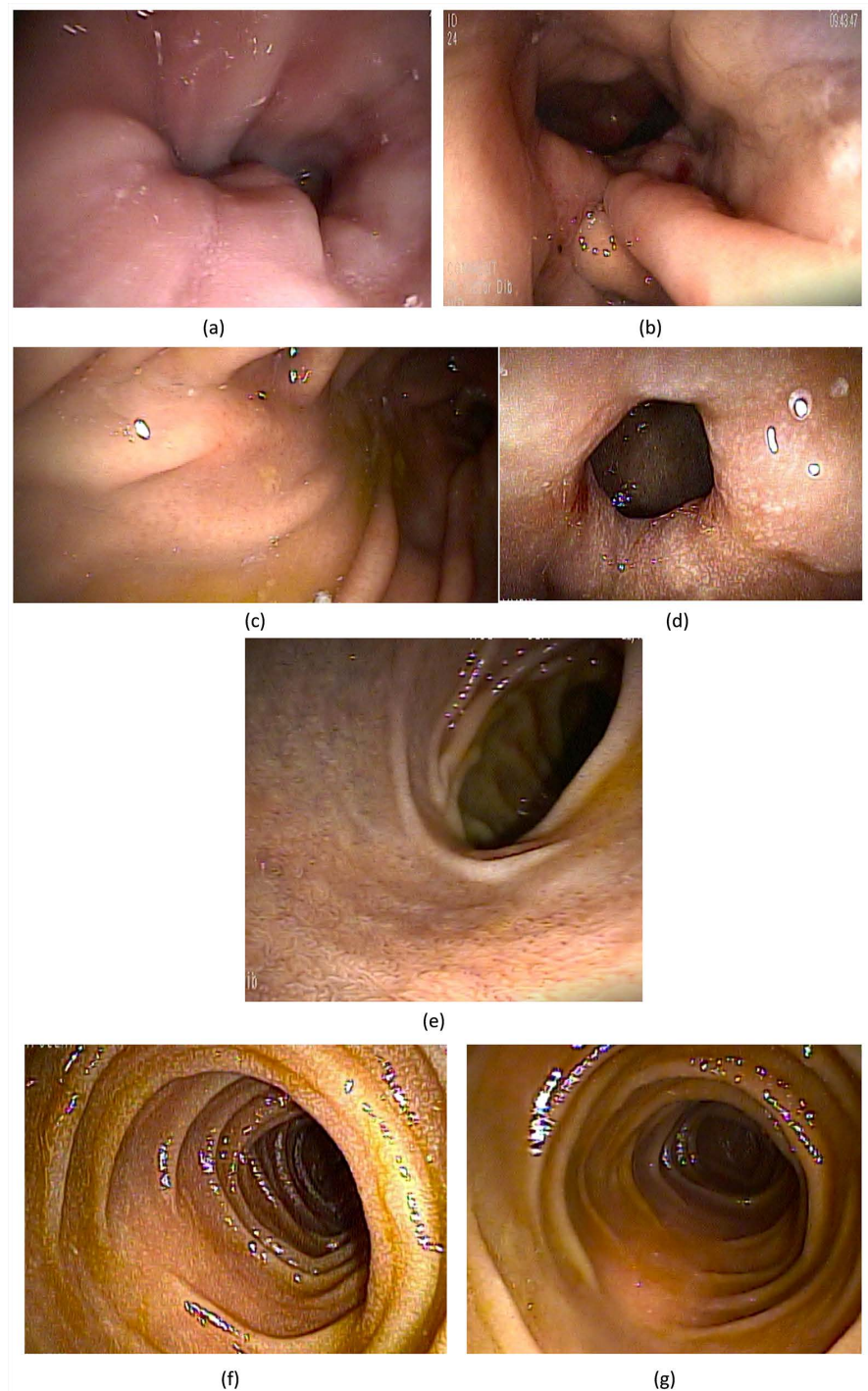


Figure 11. (a) Esophagogastric transition; (b) Gastric pouch/Gastrogastrostomy; (c) Sleeved remnant stomach; (d) Opened pylorus; (e) Bulb and duodeno-ileostomy; (f) Afferent ileal limb; (g) Efferent ileal limb.

5. Discussion

In this current study, it is reported a pyloric relaxation, endoscopically observed in two bariatric cases, one of them a primary SG and the other one, a revisional surgery (RYGB conversion to SADI-S). In both cases, the sphincter atony was

kept until 1-year endoscopic postoperative evaluation. This can represent a novel neuromodulation on the pylorus motility, which leads to a wide and permanently open pylorus. This functional response can be explained by pyloric synchronous sympathetic nerves transection, that occurred during peripyloric arterial terminal branches ligation, coming from right gastric, gastroduodenal and right gastroepiploic arteries, considering that the sympathetic gastrointestinal nerves wrap the corresponding gastrointestinal arteries [12] [13]. Such devascularization was required for pyloric traction with a tape to get a better surgical field exposure. In SG case, this maneuver facilitated the first antral stapling, while in the revisional one, it exposed better de duodenum, for its septation.

Sleeve gastrectomy has proved to be an effective bariatric procedure [14]. There are some potential advantages of doing this operation, other than achieving good weight loss results. The absence of gastrointestinal exclusions is of paramount importance in the presence of gastrointestinal cancer family history, gastric polyposis, gastrointestinal stromal tumors, intractable *H. pylori* infection, inflammatory bowel diseases and others [15] [16]. However, the high incidence of gastroesophageal reflux disease associated with this operation is a problem [17] [18] [19]. One factor related to this is the elevated intragastric pressure, due to gastric complacency reduction, that follows the subtotal longitudinal gastric wall resection [6]. Besides, the pyloric sphincter, which normally regulates gastric emptying, can represent a barrier to this process, after a sleeve gastrectomy, increasing even more the intragastric pressure. Some authors have demonstrated a reduction of GERD incidence related to SG, by adding a gastrointestinal anastomosis to decompress the gastric chamber [20] [21] [22]. Back in the 70s and 80s, some studies showed the decompressing effect of pyloroplasty and pyloromyotomy on the stomach, improving gastric emptying [23] [24]. A functionally open pylorus, derived from a pyloric sympathectomy, alluded in this current case report, could be another way of alleviating the high intragastric pressure related to sleeve gastrectomy technique, without the inherent risks associated with pyloroplasty/pyloromyotomy. The relaxed pylorus would achieve expedited gastric emptying, which could help to reduce gastroesophageal reflux disease incidence [25]. These same mechanisms could also decrease acute gastric fistulas, considering there is no obstructive factor proximal to the pylorus [26] [27]. Accelerated gastric emptying is a desired effect in sleeve gastrectomy, considering this could contribute to increased incretin stimuli [28]. A functionally open pylorus could contribute to the expedited gastric emptying.

Conversions of RYGB to other techniques, due to weight regain, are not uncommon. When this operation involves a reinsertion of the excluded stomach in the gastrointestinal tract, a spastic pylorus is a possibility. This can be related to vagus nerve injury, during the primary operation, hindering gastric emptying and creating a high-pressure gastric chamber [29]. Such a situation could lead to an increased risk of gastro-gastric anastomosis fistula, which incidence is relatively high in these conversions [30] [31]. Therefore, a permanent or even temporarily pyloric relaxation might be protective against this complication. Adding

a pyloroplasty to lower intragastric pressure in these conversions could add risks to the procedure, considering the proximity with the duodenum-ileal anastomosis step of the SADI-S procedure. Achieving pyloric relaxation through pylorus sympathectomy avoid these risks.

Regarding the safety of pyloric devascularization, the gastroduodenal transition has a good submucosal arterial interconnection, which makes the proposed sympathectomy a safe maneuver, in terms of blood supply to this area [32].

The limitations of this case report relate to the short-term evaluation of the functional effects on the pylorus (relaxation) brought by pyloric sympathectomy and the absence of manometric pyloric evaluation. It was an observational finding, during the 1-year postoperative endoscopic evaluation in two cases. This warrants controlled studies for more robust inferences.

Proof of this finding would be of great applicability, not restricted to primary or revisional bariatric surgeries, but in other surgical fields, in which a relaxed pylorus would help in reducing acute and chronic complications, such as in esophageal resections, primary or redo fundoplication associated with gastric stasis, primary pyloric hypertonia and others.

6. Conclusion

We report two cases of bariatric surgeries, one of them revisional, with an observational novel functional pyloric response. A one-year lasting pylorus atony was endoscopically observed, probable due to its terminal arterial branches ligation, which implied a simultaneous corresponding sympathetic nerves sectioning. This probable pyloric neuromodulation has the potential to be beneficial in primary sleeve gastrectomy and in revisional bariatric surgeries, considering the consequent intragastric pressure reduction. This maneuver could be protective against acute gastric pouch and/or gastro-gastric anastomosis fistulas and could avoid long-term GERD development. Further studies are necessary to confirm this hypothesis.

Acknowledgements

Thank Bariatric Channel (<https://www.bariatricchannel.com/>) as a research support.

Conflicts of Interest

The authors have no conflicts of interest related to this publication.

References

- [1] Welbourn, R., Hollyman, M., Kinsman, R., Dixon, J., Liem, R., Ottosson, J., *et al.* (2018) Bariatric Surgery Worldwide: Baseline Demographic Description and One-Year Outcomes from the Fourth IFSO Global Registry Report 2018. *Obesity Surgery*, **29**, 782-795. <https://doi.org/10.1007/s11695-018-3593-1>
- [2] English, W.J., DeMaria, E.J., Hutter, M.M., Kothari, S.N., Mattar, S.G., Brethauer, S.A., *et al.* (2020) American Society for Metabolic and Bariatric Surgery 2018 Esti-

- mate of Metabolic and Bariatric Procedures Performed in the United States. *Surgery for Obesity and Related Diseases*, **16**, 457-463. <https://doi.org/10.1016/j.soard.2019.12.022>
- [3] Quero, G., Fiorillo, C., Dallemagne, B., Mascagni, P., Curcic, J., Fox, M., et al. (2020) The Causes of Gastroesophageal Reflux After Laparoscopic Sleeve Gastrectomy: Quantitative Assessment of the Structure and Function of the Esophagogastric Junction by Magnetic Resonance Imaging and High-Resolution Manometry. *Obesity Surgery*, **30**, 2108-2117. <https://doi.org/10.1007/s11695-020-04438-y>
- [4] Rebecchi, F., Allaix, M.E., Giaccone, C., Ugliono, E., Scozzari, G. and Morino, M. (2014) Gastroesophageal Reflux Disease and Laparoscopic Sleeve Gastrectomy. *Annals of Surgery*, **260**, 909-915. <https://doi.org/10.1097/sla.0000000000000967>
- [5] Braghetto, I., Csendes, A., Korn, O., Valladares, H., Gonzalez, P. and Henríquez, A. (2010) Gastroesophageal Reflux Disease after Sleeve Gastrectomy. *Surgical Laparoscopy, Endoscopy & Percutaneous Techniques*, **20**, 148-153. <https://doi.org/10.1097/sle.0b013e3181e354bc>
- [6] Yehoshua, R.T., Eidelman, L.A., Stein, M., Fichman, S., Mazor, A., Chen, J., et al. (2008) Laparoscopic Sleeve Gastrectomy—Volume and Pressure Assessment. *Obesity Surgery*, **18**, 1083-1088. <https://doi.org/10.1007/s11695-008-9576-x>
- [7] Peterli, R., Wölnerhanssen, B.K., Peters, T., Vetter, D., Kröll, D., Borbély, Y., et al. (2018) Effect of Laparoscopic Sleeve Gastrectomy vs Laparoscopic Roux-En-Y Gastric Bypass on Weight Loss in Patients with Morbid Obesity. *JAMA*, **319**, 255-265. <https://doi.org/10.1001/jama.2017.20897>
- [8] Parmar, C., Abdelhalim, M.A., Mahawar, K.K., Boyle, M., Carr, W.R.J., Jennings, N., et al. (2016) Management of Super-Super Obese Patients: Comparison between One Anastomosis (Mini) Gastric Bypass and Roux-En-Y Gastric Bypass. *Surgical Endoscopy*, **31**, 3504-3509. <https://doi.org/10.1007/s00464-016-5376-x>
- [9] Kermansaravi, M., Davarpanah Jazi, A.H., Shahabi Shahmiri, S., Eghbali, F., Valizadeh, R. and Rezvani, M. (2021) Revision Procedures after Initial Roux-En-Y Gastric Bypass, Treatment of Weight Regain: A Systematic Review and Meta-Analysis. *Updates in Surgery*, **73**, 663-678. <https://doi.org/10.1007/s13304-020-00961-w>
- [10] Alexandrou, A., Sakarellos, P., Davakis, S., Vailas, M., Dimitriou, N., Papalampros, A., et al. (2021) Revision of Roux-En-Y Gastric Bypass for Inadequate Weight Loss or Weight Regain. *In Vivo*, **36**, 30-39. <https://doi.org/10.21873/invivo.12673>
- [11] Parikh, M., Pomp, A. and Gagner, M. (2007) Laparoscopic Conversion of Failed Gastric Bypass to Duodenal Switch: Technical Considerations and Preliminary Outcomes. *Surgery for Obesity and Related Diseases*, **3**, 611-618. <https://doi.org/10.1016/j.soard.2007.07.010>
- [12] Lerman, S.H., Jacobowitz, D.M., Robert Mason, G., Garber, H.I. and Ormsbee, H.S. (1981) Gastric and Pyloric Motor Response to Sympathetic Nerve Stimulation after Chemical Sympathectomy. *Journal of the Autonomic Nervous System*, **4**, 207-215. [https://doi.org/10.1016/0165-1838\(81\)90045-x](https://doi.org/10.1016/0165-1838(81)90045-x)
- [13] Lerman, S.H., Mason, G.R., Bathon, E.M. and Ormsbee, H.S. (1981) Pyloric motor Response to Sympathetic Nerve Stimulation in Dogs. *Surgery*, **89**, 460-465.
- [14] Salminen, P., Grönroos, S., Helmiö, M., Hurme, S., Juuti, A., Juusela, R., et al. (2022) Effect of Laparoscopic Sleeve Gastrectomy vs Roux-En-Y Gastric Bypass on Weight Loss, Comorbidities, and Reflux at 10 Years in Adult Patients with Obesity. *JAMA Surgery*, **157**, 656-666. <https://doi.org/10.1001/jamasurg.2022.2229>
- [15] Gupta, R., MacIsaac, M. and Wright, E.K. (2021) Sleeve Gastrectomy in Patients with Inflammatory Bowel Disease Is Not Associated with Worsening Disease. *Jour-*

- nal of Crohn's and Colitis*, **16**, 865-866. <https://doi.org/10.1093/ecco-jcc/jjab195>
- [16] Hashimoto, K., Sakaguchi, Y., Nambara, S., Kudou, K., Kusumoto, E., Yoshinaga, K., *et al.* (2020) Laparoscopic Sleeve Gastrectomy Performed in a Morbidly Obese Patient with Gastrointestinal Stromal Tumor: A Case Report and Literature Review. *Surgical Case Reports*, **6**, Article No. 208. <https://doi.org/10.1186/s40792-020-00976-w>
- [17] Althuwaini, S., Bamehriz, F., Aldohayan, A., Alshammari, W., Alhaidar, S., Alotaibi, M., *et al.* (2017) Prevalence and Predictors of Gastroesophageal Reflux Disease After Laparoscopic Sleeve Gastrectomy. *Obesity Surgery*, **28**, 916-922. <https://doi.org/10.1007/s11695-017-2971-4>
- [18] Navarini, D., Madalosso, C.A.S., Tognon, A.P., Fornari, F., Barão, F.R. and Gurski, R.R. (2020) Predictive Factors of Gastroesophageal Reflux Disease in Bariatric Surgery: A Controlled Trial Comparing Sleeve Gastrectomy with Gastric Bypass. *Obesity Surgery*, **30**, 1360-1367. <https://doi.org/10.1007/s11695-019-04286-5>
- [19] Vitiello, A., Abu-Abeid, A., Dayan, D., Berardi, G. and Musella, M. (2023) Long-term Results of Laparoscopic Sleeve Gastrectomy: A Review of Studies Reporting 10+ Years Outcomes. *Obesity Surgery*, **33**, 3565-3570. <https://doi.org/10.1007/s11695-023-06824-8>
- [20] Dib, V.R.M., Madalosso, C.A.S., de Melo, P.R.E., Ribeiro, R., Volpe, P. and Domene, C.E. (2024) Functional Roux-En-Y Gastric Bypass (F-RYGB), with Preservation of Duodenal Access: Report of Two Revisional Cases of Sleeve Gastrectomy. *Surgical Science*, **15**, 135-158. <https://doi.org/10.4236/ss.2024.153015>
- [21] Wang, M., Widjaja, J., Dolo, P.R., Yao, L., Hong, J. and Zhu, X. (2022) The Protective Effect of Transit Bipartition and Its Modification against Sleeve Gastrectomy-Related Esophagitis in a Rodent Model. *Obesity Surgery*, **32**, 1149-1156. <https://doi.org/10.1007/s11695-022-05907-2>
- [22] Santoro, S., Mota, F.C. and Aquino, C.G. (2019) Treating Severe GERD and Obesity with a Sleeve Gastrectomy with Cardioplication and a Transit Bipartition. *Obesity Surgery*, **29**, 1439-1441. <https://doi.org/10.1007/s11695-019-03752-4>
- [23] Goligher, J.C., Pulvertaft, C.N., Irvin, T.T., Johnston, D., Walker, B., Hall, R.A., *et al.* (1972) Five- to Eight-Year Results of Truncal Vagotomy and Pyloroplasty for Duodenal Ulcer. *BMJ*, **1**, 7-13. <https://doi.org/10.1136/bmj.1.5791.7>
- [24] Kronborg, O. and Madsen, P. (1975) A Controlled, Randomized Trial of Highly Selective Vagotomy versus Selective Vagotomy and Pyloroplasty in the Treatment of Duodenal Ulcer. *Gut*, **16**, 268-271. <https://doi.org/10.1136/gut.16.4.268>
- [25] Johari, Y., Lim, G., Wickremasinghe, A., Yue, H., Seah, J., Ooi, G., *et al.* (2020) Pathophysiological Mechanisms of Gastro-Esophageal Reflux after Sleeve Gastrectomy. *Annals of Surgery*, **276**, e407-e416. <https://doi.org/10.1097/sla.00000000000004637>
- [26] Al Hajj, G. and Chemaly, R. (2017) Fistula Following Laparoscopic Sleeve Gastrectomy: A Proposed Classification and Algorithm for Optimal Management. *Obesity Surgery*, **28**, 656-664. <https://doi.org/10.1007/s11695-017-2905-1>
- [27] Negm, S., Mousa, B., Shafiq, A., Abozaid, M., Allah, E.A., Attia, A., *et al.* (2022) Endoscopic Management of Refractory Leak and Gastro-Cutaneous Fistula after Laparoscopic Sleeve Gastrectomy: A Randomized Controlled Trial. *Surgical Endoscopy*, **37**, 2173-2181. <https://doi.org/10.1007/s00464-022-09748-z>
- [28] Mans, E., Serra-Prat, M., Palomera, E., Suñol, X. and Clavé, P. (2015) Sleeve Gastrectomy Effects on Hunger, Satiety, and Gastrointestinal Hormone and Motility Responses After a Liquid Meal Test. *The American Journal of Clinical Nutrition*, **102**, 540-547. <https://doi.org/10.3945/ajcn.114.104307>

-
- [29] Gautron, L., Zechner, J.F. and Aguirre, V. (2013) Vagal Innervation Patterns Following Roux-En-Y Gastric Bypass in the Mouse. *International Journal of Obesity*, **37**, 1603-1607. <https://doi.org/10.1038/ijo.2013.48>
- [30] Keshishian, A., Zahriya, K., Hartoonian, T. and Ayagian, C. (2004) Duodenal Switch Is a Safe Operation for Patients Who Have Failed Other Bariatric Operations. *Obesity Surgery*, **14**, 1187-1192. <https://doi.org/10.1381/0960892042387066>
- [31] Demirel, T. (2023) Mid-Term Results of Laparoscopic Conversion of Gastric Bypass to Duodenal Switch for Weight Regain: The Review of the Literature and Single-Center Experience. *Obesity Surgery*, **33**, 3889-3898. <https://doi.org/10.1007/s11695-023-06885-9>
- [32] Barclay, A.E. and Bentley, F.H. (1949) The Vascularisation of the Human Stomach. *Gastroenterology*, **12**, 177-183. [https://doi.org/10.1016/s0016-5085\(49\)80026-6](https://doi.org/10.1016/s0016-5085(49)80026-6)