

Use of the Scar Acceleration Method/Método de Aceleração Cicatricial—MAC[®]—in the Treatment of Capsular Contracture: Case Report

Carolina Macedo Alves Moreira^{1*}, Carolina Gonçalves Pinheiro², Aline Ronis Sampaio³, Michele Paula dos Santos⁴, Andres Felipe Mantilla Santamaria^{5,6}, Miriam Viviane Baron⁷, Cristine Brandenburg⁸, Nathália Ken Pereira Iketani⁹, Mara Alessandra Porto dos Reis Oliveira¹⁰, Alexandre Sancho¹¹, Esteban Fortuny¹², Felice Picariello¹³, Marcus Vinicius de Mello Pinto¹⁴

¹Dr. Daniel Thomaz Clinic, Uberlandia, Minas Gerais, Brazil

²Postgraduate Program in Health Sciences of the Faculty of Medicine of ABC (FMABC), The Vale do Salgado Faculty (FVS), Ceará, Brazil

³Celulare Institute, Petrópolis, Rio de Janeiro, Brazil

⁴School of Medicine of the Pontifical Catholic University of Rio Grande do Sul (PUC/RS), Porto Alegre, Brazil

⁵School of Medicine of the Industrial University of Santander (UIS), Bucaramanga, Colombia

⁶School of Medicine of the Pontifical Catholic University of Rio Grande do Sul (PUC/RS), Porto Alegre, Brazil

⁷Postgraduate Program in Medicine and Health Sciences of the Pontifical Catholic University of Rio Grande do Sul (PUC/RS), Porto Alegre, Brazil

⁸Brazilian Education of the Federal University of Ceará (UFC), Fortaleza, Brazil

⁹Hospital Beneficente Portuguesa of Belém, Pará, Brazil

¹⁰Clínica Instituto de Cirurgia Plástica Vênus, Barreiras, Bahia, Brazil

¹¹Unigranrio, Rio de Janeiro, Brazil

¹²Universidad Finis Terrae and CEO of Diagnostra, Santiago, Chile

¹³Università degli Studi di Napoli Federico II, Napoli, Italy

¹⁴Ph.D. and Creator of the MAC[®] Method, CEO and Researcher of the Celulare Institute, Petrópolis, Rio de Janeiro, Brazil

Email: *carolinamoreira70@gmail.com

How to cite this paper: Moreira, C.M.A., Pinheiro, C.G., Sampaio, A.R., dos Santos, M.P., Santamaria, A.F.M., Baron, M.V., Brandenburg, C., Iketani, N.K.P., dos Reis Oliveira, M.A.P., Sancho, A., Fortuny, E., Picariello, F. and de Mello Pinto, M.V. (2020) Use of the Scar Acceleration Method/Método de Aceleração Cicatricial—MAC[®]—in the Treatment of Capsular Contracture: Case Report. *Open Journal of Therapy and Rehabilitation*, 8, 131-142.

<https://doi.org/10.4236/ojtr.2020.84012>

Abstract

Capsular contracture is a frequent complication in the postoperative period of breast implantation. It usually accompanies the appearance of a firm breast that can progress to pain, distortion, and asymmetry of the breasts, requiring surgical revision. The present study is a case report. A 58-year-old woman with a medical diagnosis of capsular contracture of the right breast evidenced by ultrasound. She was referred to the physiotherapy clinic in October 2019 with an initial complaint of pain on palpation, swelling, and stiffness in her right breast. The patient was evaluated and the MAC[®] method was used to treat capsular contracture. For this, 12 sessions of photodynamic therapy were carried out. The treatment included the use of LED by doping: red (300

Received: August 3, 2020

Accepted: September 4, 2020

Published: September 7, 2020

Copyright © 2020 by author(s) and

Scientific Research Publishing Inc.

This work is licensed under the Creative

Commons Attribution International

License (CC BY 4.0).

<http://creativecommons.org/licenses/by/4.0/>



Open Access

s), violet (60 s) and blue (120 s), with the use of 1% methylene blue in target areas, three times a week. The patient had the beginning of symptoms' remission in the fourth visit and total remission in the 12th visit. It was concluded that the use of photodynamic therapy using the MAC[®] method showed improvement in signs and symptoms—the sensation of prosthesis stiffness in the lower and medial region, local temperature, and pain in the right breast. The patient was followed up after treatment and currently, she has no complaints. There was also no need for surgical intervention. In the present case report, the MAC[®] method proved to be effective. Further research is suggested with a cohort of patients with capsular contracture, with randomization and evaluation of a larger number of patients with the referred method.

Keywords

Breast Implants, Fibroses, Methylene Blue, Semiconductor Diode Laser, Photodynamic Therapy

1. Introduction

Breast augmentation represents one of the most common cosmetic procedures performed on women and involves placing an implant to change the shape and size of the breast. Breast implants can be placed either in the subglandular or submuscular position [1] and regardless of the type of implant used in the patient, there may be an excessive inflammatory reaction to the foreign body—breast implant—with collagen production and fibrotic process [2] [3] that can trigger the formation of capsular contracture (CC).

CC is a complication that generates a firm-looking breast that can progress to distortion, pain, and asymmetry, in addition to commonly requiring revision surgery with capsulectomy and implant replacement [4] [5]. About 1.3% to 30% of patients with breast implants develop CC, and approximately 92% of CC cases occur in the first 12 months after surgery. Although the characteristics of the implant surface, the formation of hematomas, and bacterial colonization are associated with the etiopathogenesis of CC, the cause and pathogenesis are not yet fully understood [5]-[11]. It is believed that the immune system plays an important role in this process, however, it is unclear the magnitude of its contribution to the formation of CC [12].

The treatment for CC base itself, mainly, on cirurgic procedures, like capsulectomy or the capsulectomy (fully or partial) and other procedures [13], like the photodynamic therapy (PDT), the latter is a form of modern non invasive therapy [14] [15], which base itself on local or systemic application of photosensitive compound that accumulates intensively on the pathological tissues. The photosensitizer molecules absorb the light from the wave length of appropriate and begin the activation processes that led to the selective destruction of the inadequate cells. The photodynamic therapy is well received by the patients due to its selective action, furthermore, the photodynamic treatments are painless and simple

regarding application, which in turn allows it to outpatient use [15] [16] [17].

In the present report, a patient with CC underwent treatment with photodynamic therapy (PDT) and there was a significant improvement in the signs and symptoms reported using a differentiated approach, based on the scar acceleration method/método de aceleração cicatricial (MAC[®]), an innovative method, little widespread in the literature, and which demonstrated satisfactory effects on patient therapy; thus, avoiding a possible surgical procedure to correct the pathogenesis. The patient's consent was obtained for this report. The case is reported here for sharing with colleagues.

2. Case Report

Female patient, 58 years old, married, and with a clinical diagnosis of CC. Patient with no history of comorbidities and no use of medication at home. She sought a physiotherapy clinic with an initial complaint of tenderness in the right breast, swelling, and stiffness on September 13, 2019. She has a previous history of plastic surgery a year ago. The patient underwent mastopexy surgery with prostheses, having a postoperative evolution with periareolar necrosis in both breasts, followed by rejection of the right prosthesis, which was removed about 27 days later. Three months after the removal, the medical team replaced the prosthesis and, seven months later, the patient sought the surgeon with the symptoms of CC.

The doctor ordered an ultrasound that showed thickening of the periprosthetic fibrous capsule of the right breast, with an area of thin anechoic liquid sheets between the prosthesis and the fibrous capsule, inferring capsulitis; thus, diagnosing CC. The patient was evaluated at the physiotherapy service on October 1, 2019. On physical examination, during inspection and palpation, there was an increase in the volume of the right breast, stiffness of the prosthesis in the lower and medial region, increased temperature and pain at the site. Physical examination revealed inflammatory indicators. However, the skin was intact, without the presence of an open wound. The range of articular movement of the right upper limb was preserved. Vital signs were normal with blood pressure: 120/70 mmHg; heart rate: 76 bpm, and axillary temperature: 36.8°C.

The patient started treatment at the physiotherapy clinic using the MAC[®] method on October 1, 2019. This method is a proposal for therapeutic intervention based on the premise of identifying, evaluating, interpreting, and treating the problem. For this, anamnesis, detailed physical examination, and analysis of complementary tests are performed to interpret the problem and define treatment.

The treatment intervention continued with the use of PDT, which uses Light-Emitting Diode (LED) in association with specific drugs. In the present case, the treatment followed the topical application of 1% methylene blue solution, which is photosensitizing agent, in the lower and medial region of the right breast. Then, the red (300 s), violet (60 s) and blue (120 s) LED were applied in the region. The treatment was carried out three times a week, and a total of 12

sessions were carried out to finish the treatment. In the 12th consultation, there was improvement of the condition, with no complaints of pain on palpation, edema and stiffness in the right breast. On physical examination, the right and left breast had a similar appearance and volume. The patient was discharged from the clinical physiotherapist.

The patient remains under monthly monitoring with the physiotherapist and the surgeon. In the follow-up, the patient remains without complaints of pain on palpation, and without signs of edema and stiffness in the right breast. The patient did not need to use medication during treatment and also did not need a new surgical intervention. **Figure 1** shows the breasts before treatment, with complaints of pain on palpation, swelling, and stiffness in the right breast. After the start of treatment, the patient presented remission of signs and symptoms at the fourth session. And there was an improvement in the overall condition at the 12th visit, as shown in **Figure 2**. **Figure 3** shows the image 30 days after treatment, with no complaints of pain and stiffness in the right breast.

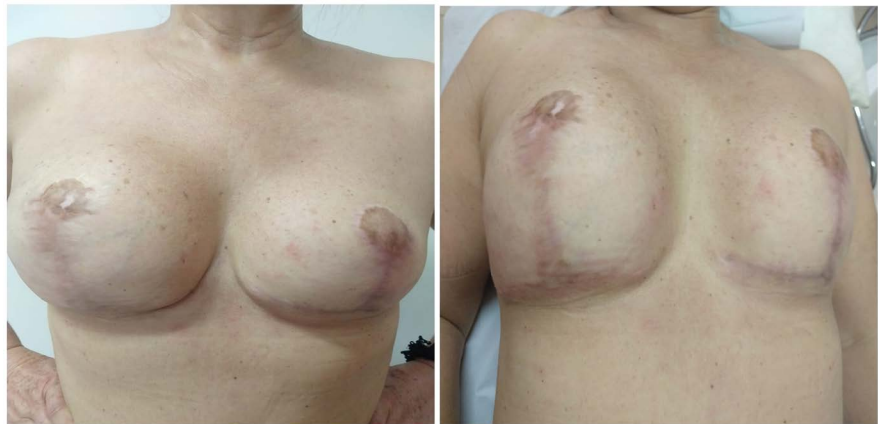

Figure 1. Image of the breasts before the first session. Source: Author data.

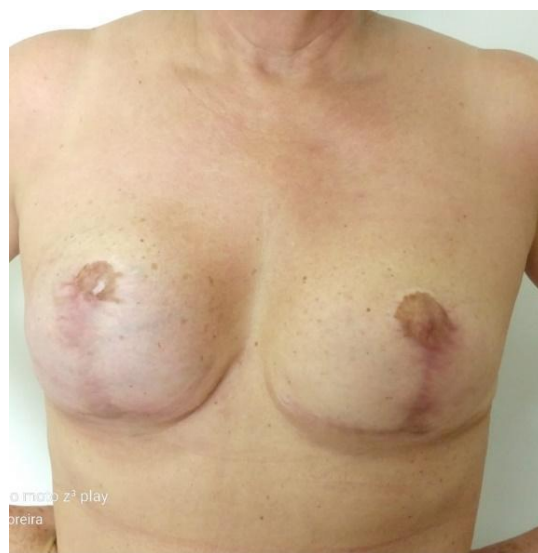

Figure 2. Image after the 12th session. Source: Author data.

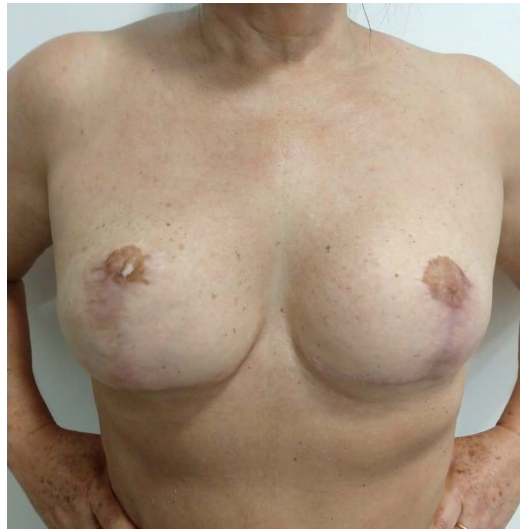


Figure 3. Image 30 days after the end of the sessions. Source: Author data

3. Discussion

Breast implants for augmentation and cosmetic purposes are generally performed by placing the prostheses in the subglandular or submuscular position [1]. There are several complications related to this procedure, from bacterial infections to capsular contractures, being the last the most frequent complication after breast enlargement or reconstruction with breast implants [12] [18] [19]. The immune system plays an important role in the formation of CC, but it is not known the extent of this immunological action [12]. It is believed that CC is multifactorial and that an excessive inflammatory reaction to a foreign body occurs, causing changes in the production of collagen fibers and fibrosis, among other reactions [3]. The main symptoms of CC are pain, induration, and distortion of the breast [12] [20], corroborating the findings of the present report.

The formation of a capsule around the silicone prosthesis is part of an adaptive response to a foreign body, which is a normal reaction after breast implantation. The silicone prosthesis, although relatively inert, causes a protective immune reaction, isolating the exogenous material and keeping the prosthesis at the implantation site [13]. This immune response involves macrophages, T cells, and various types of cytokines [12] [21] [22]. Subsequently, the pro-inflammatory cells decrease in number and fibroblasts begin to accumulate around the implant, thus, a fibrous capsule is formed [12] [23] [24] [25], normally, being a soft and thin capsule, which does not influence the shape of the breast. However, the capsules can become contracted and this can generate a tendency to thicken, constrict, and induration around the implant, which is attributed to an excess of myofibroblast production within the capsule [12] [26]. Despite advances in studies in this area, the pathogenesis of CC is not yet fully understood [5].

In addition, it is known that the capsule tissue is composed of collagen fibers, in which the orientation and organization of these fibers are altered as the disease progresses, becoming thicker bundles. In CC, the physiological response of

fibroblasts ends up becoming more accentuated through interactions with inflammatory cells and with the extracellular matrix (ECM) [27] [28], also occurring the differentiation of fibroblasts into myofibroblasts, which will provide a contractile force that will decrease the capsule's surface area, while the collagen matrix remodels and stabilizes the contracture. On the other hand, in the fibrotic condition, myofibroblasts proliferate persistently and are resistant to apoptosis, which leads to the assembly of the ECM with subsequent target organ dysfunction. In the epithelial-mesenchymal transition, there is an important predominance of myofibroblasts, which will play a critical role in the development of organ fibrosis [2] [29] [30] [31] [32] [33].

Thus, the number of fibroblasts is directly related to the degree of CC and the appearance of the breast, according to Baker's usual classification [2]. This classification describes four degrees of CC: Grade I, a normal and soft breast; grade II, capsule contracture is minimal, observed on palpation; grade III, a moderate degree of CC, which may cause pain—breasts with some visible asymmetry; and IV: severe CC, with a painful, hard and distorted breast. Grades III and IV usually require correction surgery [34]. In the present report, a painful and hard breast, but not distorted, corresponding to grade III of CC, was observed.

Mast cells are also identified as participating in the pathogenesis process of CC. These are present in the capsular tissue and involved with renin, histamine, and tumor growth factor β -1 (TGF- β). Capsular fibroblasts are responsible for signaling corresponding receptors indicating that mast cells can activate neighboring fibroblasts via a paracrine pathway, which leads to an increase in collagen production and, therefore, to the development of contracture of the capsule [3] [35]. In addition, hypoxia seems to be one of the determining factors of fibrogenesis, since the capsules are usually located between normal tissues and the artificial avascular prosthesis; thus, being able to find relatively hypoxic conditions in this place when compared to normal tissues [2].

PDT is a therapeutic procedure used in wound healing, treatment of psoriasis, squamous cell carcinoma in situ (Bowen's disease), basal cell carcinoma, mild to moderate acne vulgaris, actinic keratosis, and cosmetic applications [36]. It is a technique that uses dyes or pigments that are photosensitizing molecules and able to absorb visible light, resulting in photochemical reactions [37]. This therapy involves the use of the LED, which consists of light-emitting diodes and its function is to stimulate the production of ATP in the mitochondria, which contributes to faster healing of wounds with wavelengths of 680, 730 and 880 nm; in addition to promoting changes in the items forming the material that is subjected to an electromagnetic light source [38].

In PDT there are three main components: the photosensitizer, light, and oxygen, which interact on time scales for a single treatment. It is also noteworthy that the distribution of light is determined by the characteristics of the light source and the optical properties of the tissue, which are influenced by the concentration of photosensitizer and the concentration of oxygen in the blood [38] [39] [40]. The treatment's principle of the PDT is the interaction between visible

spectrum light, the photosensitizing substance, and endogenous oxygen that leads to toxicity for the target cells [37]. This treatment has two action mechanisms [37] [41] [42], the first is called Reaction I which, after the absorption of photons by the dye, generates an electronic stimulation called the triplet, which leads to electron transfer from the photosensitizer and can act directly with biological substrates to form free radicals. The second mechanism, Reaction II, consists of transferring energy from the photosensitizer directly to the molecular oxygen dissolved in the cells to form a very excitable state, which is singlet oxygen, which is cytotoxic to the cells of the target tissue [37] [43] [44] [45] [46] [47].

Methylene blue is the photosensitizing molecule that can generate high concentrations of singlet oxygen or can induce the formation of reactive oxygen species, which are byproducts of PDT and can cause cell toxicity [37] [48] [49] [50]. This photosensitizer absorbs light within a therapeutic window of 600 to 800 nm, in which there is a greater penetration of light in the tissues and can be used in several therapies [37] [48] [50]. Depending on the type of interface to which the sensitizers bind, different types of aggregates can be induced and can generate different types of cytotoxic species, and, consequently, different mechanisms of apoptosis [48]. On the other hand, PDT works with an antimicrobial effect and contributes to the natural healing process [37] [51]. Therefore, it is believed that in the case of CC, apoptosis in the target tissue is initially generated, subsequently enabling remodeling and wound healing.

In the process of remodeling the lesion, there is maturation and reorganization of the ECM's elements, with type III collagen being replaced by type I collagen, a process that is done by metalloproteases, which are proteolytic enzymes characterized by the ability to degrade various components of the ECM [52] [53]. In order to successfully remodel, it is necessary to have a balance between ECM synthesis and degradation, as an imbalance in this process can cause changes in the aesthetic quality of healing. According to authors on the subject, after three sessions of PDT, it was observed that the process of remodeling the lesion provided an increase in TGF- β and β_3 , which favored control in the ordered deposition of collagen fibers [54]. Thus, through the reactions that occur in PDT regarding oxygen modification, microorganism control, inflammatory process modulation, healing improvement, and collagen reorganization, positive effects were obtained in the treatment of CC in the present report.

Therefore, it is believed that the treatment of PDT employed in this patient with CC provided a qualitative improvement in the signs and symptoms reported by the patient. Thus, the importance of this work is given by the differentiated approach based on the MAC[®] method, an innovative method, little disseminated in the literature, and which demonstrated satisfactory effects in the treatment of CC. The standard treatment for CC is surgical with capsulectomy or capsulotomy [3]. The patient in the present report presented signs and symptoms of grade III CC, according to the clinical picture, indicative of surgery according to the current medical literature [34]. However, it was possible to evi-

dence improvement in the CC condition using the MAC[®] method. Thus, there was no need for a new surgical intervention avoiding the potential risks arising from it.

As limitations of this study, it is possible to point out the absence of a new breast ultrasound after the treatment of CC with the MAC[®] method. Thus, it is not possible to evidence the results by images, but only by reporting and monitoring with physical examination the improvements in CC in the present report. As suggestions for future research, it is recommended to monitor a cohort of patients with CC, with randomization of groups, and control of variables and assessment measures. To our knowledge, this is the first study that uses the MAC[®] method and PDT in the treatment of CC.

4. Conclusion

The patient was referred to the physiotherapy service in October 2019, after seven months of plastic surgery and replacement of the breast implant. She had a medical diagnosis of CC confirmed by ultrasound examination. CC is formed by an exacerbated reaction that promotes the formation of a capsule with fibrosis due to excess collagen production, differentiation of fibroblasts into myofibroblasts, in addition to the involvement of the ECM, which leads to the presence of symptoms such as stiffness, tension, deformation of the breast, and the possibility of pain occurring. The patient in the present report had a clinical condition corresponding to grade III according to Baker's classification. It was subjected to PDT using the MAC[®] Method in order to improve collagen reorganization and healing, showing positive effects with reports of improvement of CC. The patient showed improvement in signs and symptoms—the sensation of prosthesis stiffness in the lower and medial region, local temperature, and pain—of the treated breast (right breast). The patient was followed up after the treatment and currently, she has no complaints and no surgical intervention is necessary. In the present case report, the MAC[®] method proved to be effective in the treatment of CC. Further research with a larger number of patients and randomization is suggested for the evaluation of this method.

Acknowledgements

This study was funded in part by the Coordination of Improvement of Higher Level Personnel-Brazil (CAPES)-Finance Code 001.

Conflicts of Interest

The authors declare having no conflict of interest regarding this article.

References

- [1] Lalani, T. (2018) Breast Implant Infections. *Infectious Disease Clinics of North America*, **32**, 877-884. <https://doi.org/10.1016/j.idc.2018.06.007>
- [2] Kuo, Y.-L., Jou, I.-M., Jeng, S.-F., Chu, C.-H., Huang, J.-S., Hsu, T.-I., *et al.* (2019)

- Hypoxia-Induced Epithelial-Mesenchymal Transition and Fibrosis for the Development of Breast Capsular Contracture. *Scientific Reports*, **9**, Article No. 10269. <https://doi.org/10.1038/s41598-019-46439-7>
- [3] Headon, H., Kasem, A. and Mokbel, K. (2015) Capsular Contracture after Breast Augmentation: An Update for Clinical Practice. *Archives of Plastic Surgery*, **42**, 532-543. <https://doi.org/10.5999/aps.2015.42.5.532>
- [4] Liu, C., Chen, Y., Xu, Y., Qu, Q., Wang, Z. and Fan, Y. (2019) Transaxillary Endoscopic Approach to Capsular Contracture Following Previous Breast Augmentation: Operative Technique and Clinical Outcome. *Aesthetic Plastic Surgery*, **44**, 28-34. <https://doi.org/10.1007/s00266-019-01525-z>
- [5] Cihan, Y.B., Baykan, H. and Arslan, A. (2019) Treatment of Capsular Contracture after Radiotherapy in Breast Reconstruction. *European Journal of Breast Health*, **15**, 203-204. <https://doi.org/10.5152/ejbh.2019.4713>
- [6] Kim, I.-K., Park, S.O., Chang, H. and Jin, U.S. (2018) Inhibition Mechanism of Acellular Dermal Matrix on Capsule Formation in Expander-Implant Breast Reconstruction after Postmastectomy Radiotherapy. *Annals of Surgical Oncology*, **25**, 2279-2287. <https://doi.org/10.1245/s10434-018-6549-8>
- [7] Evans, G.R.D., Schusterman, M.A., Kroll, S.S., Miller, M.J., Reece, G.P., Robb, G.L., et al. (1995) Reconstruction and the Radiated Breast: Is There a Role for Implants? *Plastic and Reconstructive Surgery*, **96**, 1111-1115. <https://doi.org/10.1097/00006534-199510000-00016>
- [8] Azzi, A.J., Zammit, D. and Lessard, L. (2018) Single-Stage Breast Reconstruction Using an All-in-One Adjustable Expander/Implant. *Plastic and Reconstructive Surgery—Global Open*, **6**, e1609. <https://doi.org/10.1097/GOX.0000000000001609>
- [9] Hallberg, H., Rafnsdottir, S., Selvaggi, G., Strandell, A., Samuelsson, O., Stadig, I., et al. (2018) Benefits and Risks with Acellular Dermal Matrix (ADM) and Mesh Support in Immediate Breast Reconstruction: A Systematic Review and Meta-Analysis. *Journal of Plastic Surgery and Hand Surgery*, **52**, 130-147. <https://doi.org/10.1080/2000656X.2017.1419141>
- [10] Chung, K.J., Park, K.R., Lee, J.H., Kim, T.G. and Kim, Y.-H. (2016) Simvastatin Reduces Capsular Fibrosis around Silicone Implants. *Journal of Korean Medical Science*, **31**, 1273-1278. <https://doi.org/10.3346/jkms.2016.31.8.1273>
- [11] Cook, M., Johnson, N., Zegzula, H.D., Schray, M., Glissmeyer, M. and Sorenson, L. (2016) Prophylactic Use of Pentoxifylline (Trental) and Vitamin E to Prevent Capsular Contracture after Implant Reconstruction in Patients Requiring Adjuvant Radiation. *The American Journal of Surgery*, **211**, 854-859.
- [12] Bachour, Y., Verweij, S.P., Gibbs, S., Ket, J.C.F., Ritt, M.J.P.F., Niessen, F.B., et al. (2018) The Aetiopathogenesis of Capsular Contracture: A Systematic Review of the Literature. *Journal of Plastic, Reconstructive & Aesthetic Surgery*, **71**, 307-317. <https://doi.org/10.1016/j.bjps.2017.12.002>
- [13] Pereira Leite, L., Correia Sá, I. and Marques, M. (2013) Etiopathogenesis and Treatment of Breast Capsular Contracture. *Acta Médica Portuguesa*, **26**, 737-745.
- [14] Luo, D., Carter, K.A., Miranda, D. and Lovell, J.F. (2017) Chemophototherapy: An Emerging Treatment Option for Solid Tumors. *Advanced Science*, **4**, Article ID: 1600106. <https://doi.org/10.1002/advs.201600106>
- [15] Kwiatkowski, S., Knap, B., Przystupski, D., Saczko, J., Kędzierska, E., Knap-Czop, K., et al. (2018) Photodynamic Therapy—Mechanisms, Photosensitizers and Combinations. *Biomedicine & Pharmacotherapy*, **106**, 1098-1107. <https://doi.org/10.1016/j.biopha.2018.07.049>

- [16] Kharkwal, G.B., Sharma, S.K., Huang, Y.-Y., Dai, T. and Hamblin, M.R. (2011) Photodynamic Therapy for Infections: Clinical Applications. *Lasers in Surgery and Medicine*, **43**, 755-767. <https://doi.org/10.1002/lsm.21080>
- [17] Sperandio, F.F., Huang, Y.-Y. and Hamblin, M.R. (2013) Antimicrobial Photodynamic Therapy to Kill Gram-Negative Bacteria. *Recent Patents on Anti-Infective Drug Discovery*, **8**, 108-120. <https://doi.org/10.2174/1574891X113089990012>
- [18] Henriksen, T.F., Hölmich, L.R., Fryzek, J.P., Friis, S., McLaughlin, J.K., Høyer, A.P., *et al.* (2003) Incidence and Severity of Short-Term Complications after Breast Augmentation: Results from a Nationwide Breast Implant Registry. *Annals of Plastic Surgery*, **51**, 531-539. <https://doi.org/10.1097/01.sap.0000096446.44082.60>
- [19] Stevens, W.G., Harrington, J., Alizadeh, K., Berger, L., Broadway, D., Hester, T.R., *et al.* (2012) Five-Year Follow-Up Data from the U.S. Clinical Trial for Sientra's U.S. Food and Drug Administration-Approved Silimed Brand Round and Shaped Implants with High-Strength Silicone Gel. *Plastic and Reconstructive Surgery*, **130**, 973-981. <https://doi.org/10.1097/PRS.0b013e31826b7d2f>
- [20] Baker Jr., J.L., Bartels, R.J. and Douglas, W.M. (1976) Closed Compression Technique for Rupturing a Contracted Capsule around a Breast Implant. *Plastic and Reconstructive Surgery*, **58**, 137-141. <https://doi.org/10.1097/00006534-197608000-00002>
- [21] Blum, A., Abboud, W., Shajrawi, I. and Tatour, I. (2007) Prolonged Fever Due to Silicone Granulomatosis. *Israel Medical Association Journal*, **9**, 121-122.
- [22] Prantl, L., Schreml, S., Fichtner-Feigl, S., Pöpl, N., Eisenmann-Klein, M., Schwarze, H., *et al.* (2007) Clinical and Morphological Conditions in Capsular Contracture Formed around Silicone Breast Implants. *Plastic and Reconstructive Surgery*, **120**, 275-284. <https://doi.org/10.1097/01.prs.0000264398.85652.9a>
- [23] Domanskis, E.J. and Owsley, J.QJ. (1976) Histological Investigation of the Etiology of Capsule Contracture Following Augmentation Mammoplasty. *Plastic and Reconstructive Surgery*, **58**, 689-693. <https://doi.org/10.1097/00006534-197612000-00006>
- [24] Gayou, R.M. (1979) A Histological Comparison of Contracted and Non-Contracted Capsules around Silicone Breast Implants. *Plastic and Reconstructive Surgery*, **63**, 700-707. <https://doi.org/10.1097/00006534-197905000-00015>
- [25] Nemecek, J.R. and Young, V.L. (1993) How Safe Are Silicone Breast Implants? *Southern Medical Journal*, **86**, 932-944. <https://doi.org/10.1097/00007611-199308000-00017>
- [26] Lossing, C. and Hansson, H.-A. (1993) Peptide Growth Factors and Myofibroblasts in Capsules around Human Breast Implants. *Plastic and Reconstructive Surgery*, **91**, 1277-1286. <https://doi.org/10.1097/00006534-199306000-00014>
- [27] Araco, A., Caruso, R., Araco, F., Overton, J. and Gravante, G. (2009) Capsular Contractures: A Systematic Review. *Plastic and Reconstructive Surgery*, **124**, 1808-1819. <https://doi.org/10.1097/PRS.0b013e3181bf7f26>
- [28] Sood, A., Xue, E.Y., Sangiovanni, C., Therattil, P.J. and Lee, E.S. (2017) Breast Massage, Implant Displacement, and Prevention of Capsular Contracture After Breast Augmentation with Implants: A Review of the Literature. *Eplasty*, **17**, e41. <https://www.ncbi.nlm.nih.gov/pmc/articles/PMC5749369/>
- [29] Wynn, T.A. and Ramalingam, T.R. (2012) Mechanisms of Fibrosis: Therapeutic Translation for Fibrotic Disease. *Nature Medicine*, **18**, 1028-1040. <https://doi.org/10.1038/nm.2807>
- [30] LeBleu, V.S., Taduri, G., O'Connell, J., Teng, Y., Cooke, V.G., Woda, C., *et al.* (2013) Origin and Function of Myofibroblasts in Kidney Fibrosis. *Nature Medicine*,

- 19, 1047-1053. <https://doi.org/10.1038/nm.3218>
- [31] Stone, R.C., Pastar, I., Ojeh, N., Chen, V., Liu, S., Garzon, K.I., et al. (2016) Epithelial-Mesenchymal Transition in Tissue Repair and Fibrosis. *Cell and Tissue Research*, **365**, 495-506. <https://doi.org/10.1007/s00441-016-2464-0>
- [32] Padwal, M. and Margetts, P.J. (2016) Experimental Systems to Study the Origin of the Myofibroblast in Peritoneal Fibrosis. *Kidney Research and Clinical Practice*, **35**, 133-141. <https://doi.org/10.1016/j.krcp.2016.07.003>
- [33] Sun, Y.B.Y., Qu, X., Caruana, G. and Li, J. (2016) The Origin of Renal Fibroblasts/Myofibroblasts and the Signals That Trigger Fibrosis. *Differentiation*, **92**, 102-107. <https://doi.org/10.1016/j.diff.2016.05.008>
- [34] Wan, D. and Rohrich, R.J. (2016) Revisiting the Management of Capsular Contracture in Breast Augmentation: A Systematic Review. *Plastic and Reconstructive Surgery*, **137**, 826-841. <https://doi.org/10.1097/01.prs.0000480095.23356.ae>
- [35] Brazin, J., Malliaris, S., Groh, B., Mehrara, B., Hidalgo, D., Otterburn, D., et al. (2014) Mast Cells in the Periprosthetic Breast Capsule. *Aesthetic Plastic Surgery*, **38**, 592-601. <https://doi.org/10.1007/s00266-014-0318-2>
- [36] Ablon, G. (2018) Phototherapy with Light Emitting Diodes: Treating a Broad Range of Medical and Aesthetic Conditions in Dermatology. *The Journal of Clinical and Aesthetic Dermatology*, **11**, 21-27.
- [37] Da Silva, A.P. (2014) Avaliação histopatológica do tratamento do carcinoma espinocelular cutâneo em camundongos usando terapia fotodinâmica mediada por azul de metileno. Universidade de São Paulo, São Paulo. <http://www.teses.usp.br/teses/disponiveis/42/42134/tde-25112014-130952/>
- [38] Pinto and De Mello, M.V. (2011) Fototerapia—Aspectos Clínicos Da Reabilitação. ANDREOLI, São Paulo.
- [39] Zhu, T.C. and Finlay, J.C. (2008) The Role of Photodynamic Therapy (PDT) Physics. *Medical Physics*, **35**, 3127-3136. <https://doi.org/10.1118/1.2937440>
- [40] Gonçalves, R.V., Sarandy, M.M., Da Matta, S.L.P., Novaes, R.D. and De Mello Pinto, M.V. (2013) Comparative Study of the Effects of laser Photobiomodulation and Extract of *Brassica oleracea* on Skin Wounds in Wistar Rats: A Histo-morphometric Study. *Pathology—Research and Practice*, **209**, 648-653. <https://doi.org/10.1016/j.prp.2013.07.006>
- [41] Arias, G.A.M., Luna, A.E., Delgadillo, A.A. and Camps-Fresneda, A. (2007) Terapia Fotodinâmica. *Medicina cutânea ibero-latino-americana*, **35**, 255-268.
- [42] Dougherty, T.J., Gomer, C.J., Henderson, B.W., Jori, G., Kessel, D., Korbek, M., et al. (1998) Photodynamic Therapy. *Journal of the National Cancer Institute*, **90**, 889-905. <https://doi.org/10.1093/jnci/90.12.889>
- [43] Kübler, A.C. (2005) Photodynamic Therapy. *Medical Laser Application*, **20**, 37-45.
- [44] Da Hora Machado, A.E. (2000) Photodynamic Therapy: Principles, Potential of Application and Perspectives. *Química Nova*, **23**, 237-243. <https://doi.org/10.1590/S0100-4042200000200015>
- [45] Mroz, P., Yaroslavsky, A., Kharkwal, G.B. and Hamblin, M.R. (2011) Cell Death Pathways in Photodynamic Therapy of Cancer. *Cancers*, **3**, 2516-2539. <https://doi.org/10.3390/cancers3022516>
- [46] Soukos, N.S., Ximenez-Fyvie, L.A., Hamblin, M.R., Socransky, S.S. and Hasan, T. (1998) Targeted Antimicrobial Photochemotherapy. *Antimicrobial Agents and Chemotherapy*, **42**, 2595-2601. <https://doi.org/10.1128/AAC.42.10.2595>
- [47] Silva, M.P. (2012) Terapia Fotodinâmica em esporos de *Bacillus atrophaeus* e

Bacillus subtilis: estudos com LASER, LED, azul de metileno, rosa bengala e verde malaquita. Universidade Estadual Paulista, São José dos Campos.

- [48] Severino, D., Helena, C., Gugliotti, M., Gabrielli, D. and Baptista, M. (2003) Influence of Negatively Charged Interfaces on the Ground and Excited State Properties of Methylene Blue. *Photochemistry and Photobiology*, **77**, 459-468.
[https://doi.org/10.1562/0031-8655\(2003\)077%3C0459:IONCIO%3E2.0.CO;2](https://doi.org/10.1562/0031-8655(2003)077%3C0459:IONCIO%3E2.0.CO;2)
- [49] Tardivo, J.P., Del Giglio, A., De Oliveira, C.S., Gabrielli, D.S., Junqueira, H.C., Tada, D.B., *et al.* (2005) Methylene Blue in Photodynamic Therapy: From Basic Mechanisms to Clinical Applications. *Photodiagnosis and Photodynamic Therapy*, **2**, 175-191. [https://doi.org/10.1016/S1572-1000\(05\)00097-9](https://doi.org/10.1016/S1572-1000(05)00097-9)
- [50] Wainwright, M. (2005) The Development of Phenothiazinium Photosensitisers. *Photodiagnosis and Photodynamic Therapy*, **2**, 263-272.
[https://doi.org/10.1016/S1572-1000\(05\)00110-9](https://doi.org/10.1016/S1572-1000(05)00110-9)
- [51] Sperandio, F.F., Simões, A., Aranha, A.C.C., Corrêa, L., Machado de Sousa, S.C.O. (2010) Photodynamic Therapy Mediated by Methylene Blue Dye in Wound Healing. *Photobiomodulation, Photomedicine, and Laser Surgery*, **28**, 581-587.
- [52] Gurtner, G.C., Werner, S., Barrandon, Y., Longaker, M.T. (2008) Wound Repair and Regeneration. *Nature*, **453**, 314-321. <https://doi.org/10.1038/nature07039>
- [53] Madden, J.W. and Peacock, E.E. (1971) Studies on the Biology of Collagen during Wound Healing. 3. Dynamic Metabolism of Scar Collagen and Remodeling of Dermal Wounds. *Annals of Surgery*, **174**, 511-520.
<https://doi.org/10.1097/0000658-197109000-00017>
- [54] Farrar, M.D., Mills, S.J., Griffiths, C.E., Ashcroft, G.S. and Rhodes, L.E. (2011) Photodynamic Therapy Modulates Production of Transforming Growth Factor (TGF)-Beta in Association with Improved Healing in Excisional Wounds of Human Skin. ResearchGate, Berlin.