

Class III Reversion with Immediate Complete Denture and Immediate Implant-Retained Overdenture: Case Report

Giovanna Lima Costa Barcelos¹, Rafaella de Oliveira Matiolo¹, Sérgio Carvalho Costa², Cláudia Lopes Brilhante Bhering², José Augusto César Discacciati²

¹Dental School, Federal University of Minas Gerais, Belo Horizonte, Brazil

²Department of Restorative Dentistry, Dental School, Federal University of Minas Gerais, Belo Horizonte, Brazil

Email: giovannalima610@gmail.com

How to cite this paper: Barcelos, G.L.C., de Oliveira Matiolo, R., Costa, S.C., Bhering, C.L.B. and Discacciati, J.A.C. (2020) Class III Reversion with Immediate Complete Denture and Immediate Implant-Retained Overdenture: Case Report. *Open Journal of Stomatology*, 10, 372-382. <https://doi.org/10.4236/ojst.2020.1012034>

Received: November 10, 2020

Accepted: December 25, 2020

Published: December 28, 2020

Copyright © 2020 by author(s) and Scientific Research Publishing Inc. This work is licensed under the Creative Commons Attribution International License (CC BY 4.0).

<http://creativecommons.org/licenses/by/4.0/>



Open Access

Abstract

With the increased life expectancy, complete dentures have been used in the treatment of edentulism progressively. It restores stomatognathic system functions, providing improvements in chewing, aesthetics, and phonetics. The aim was to report an oral rehabilitation of a patient with severe aesthetic and functional impairment, with Angle's class III malocclusion. The patient sought the extension project of the School of Dentistry of the Federal University of Minas Gerais with aesthetic complaints. After clinical and radiographic evaluation, the proposed planning was immediate complete denture maxilla and immediate implant-retained overdenture in mandible. During clinical evaluation it was observed that the patient was Angle's III. The rehabilitation was performed as proposed and at the end of the treatment, it was possible to revert the class III occlusal pattern to Angle's I. The excellent maxillomandibular relationship was achieved, which ensured optimal facial aesthetics and functional condition. It was concluded that the immediate complete dentures and immediate implant-retained overdenture might be beneficial for restoring the aesthetics and function of patients with Angle's class III malocclusion.

Keywords

Dental Prosthesis, Immediate Complete Denture, Overdenture, Dental Implants, Dental Occlusion

1. Introduction

To reestablish the functions of the stomatognathic system, it becomes essentially the replacement of lost teeth through the prosthesis, providing an improvement

of chewing, aesthetics, and phonetics, and, consequently, an increase of comfort and quality of life of the patient [1]. However, in cases of partial edentulism, when the patient's remaining teeth are indicated for extraction, there may be insecurity experienced by the patient regarding the fact that he remains toothless during the period of tissue healing and prosthesis construction.

In this situation, it has been indicated the use of immediate complete denture (ICD), which is made before anterior teeth extraction. This is important because it allows the preservation of aesthetics until the prosthesis placement and increases the acceptance of anterior teeth extraction. In these cases, there is a simultaneity of the surgical phase with the prosthetic phase. This conduct has as its main advantage of preservation of psychological and social well-being since the patient at no time is completely edentulous, facilitating their social and family life [2].

Besides the improvement of the aesthetic aspect, the immediate complete denture maintains expression and the natural facial appearance, since the facial muscles are maintained in their normal position before extractions [3]. The surgical wounds can also be protected against physical aggression, allowing hemorrhage control, protection against exogenous infections, and faster healing [4]. A well-executed immediate complete denture, together with the patient's psychological preparation, can significantly improve their quality of life [5].

However, a problem reported by patients using the lower removable prostheses is the lack of retention and stability. This occurs due to the action of structures such as the tongue, salivary glands, mental muscles, buccinators, mylo-hyoid and the smallest area of contact with the fibromucosa, which impairs the performance of the prostheses [6] [7].

For these cases, implant rehabilitation is a reliable and predictable treatment modality. Implant-retained overdentures are an excellent treatment alternative. Overdentures are removable complete dentures stabilized by retentive elements installed on residual roots or implants. This treatment modality, which presents a high rate of clinical success, solves several problems reported by users of a removable prosthesis because it improves retention and stability, also improving chewing function and phonation, and transmits to the patient greater safety [8]. When compared to implant-supported fixed prostheses, overdentures present lower cost and greater facility for the cleaning, both for the prosthetic part and the implanted units, mainly for patients with some motor difficulties and/or advanced age [9] [10] [11].

In addition to the evaluation for the implants immediate loading, during the examination and treatment planning, an important situation is the occlusal pattern of the patients. Malocclusion must be evaluated concerning function and aesthetics and, possible corrections in future rehabilitation should be considered.

In cases of intermaxillary relationships referred to as Angle's Class III malocclusion, the strong aesthetic impairment and unfavorable treatment prognosis are especially highlighted, especially when there is a hereditary component [12]. The dentofacial deformities associated with bone base changes can lead to an

unfavorable functional and aesthetic binomial, which can lead to several abnormalities, such as difficulty in chewing, mouth breathing, obstructive sleep apnea, in addition to facial disharmony [13].

The prosthesis treatment for this group is challenging due to skeletal discrepancies between the maxilla and mandible. Frequently, patients with class III malocclusion present anterior and/or posterior crossbite, resulting from mandibular prognathism and/or maxillary retrognathism. Also, a reduced overjet may be present, as well as the absence of an anterior guide [14]. In these cases, in adult patients, the treatment is usually conducted by orthodontic means, with or without orthognathic surgery. However, the duration of orthodontic therapy and intrusiveness of surgery often deter them [15]. When the remaining teeth are no longer viable, one of the therapy options is a dental prosthesis approach, as will be described in this article. In this sense, the choice of the occlusal pattern to be instituted in the future rehabilitation of the patient is extremely important, especially because the stress pattern during chewing distributed throughout the prosthesis causes the same stress on supporting tissues [16].

Thus, the aim was to report a clinical case of a patient with Angle's class III occlusal pattern rehabilitated with immediate complete dentures in maxilla and immediate overdenture in mandible. The treatment was executed in an assistance project offered by the School of Dentistry of the Federal University of Minas Gerais. This project aims to rehabilitate low-income patients, with severe aesthetic and functional impairment, using immediate complete dentures for maxilla and overdentures retained by two single-implants, in immediate load, for mandible.

2. Case Report

A female patient, 59 years old, sought care at extension project of the School of Dentistry of the Federal University of Minas Gerais. On intraoral examination was observed: severe dental-periodontal involvement, loss of dental elements, unsatisfactory prostheses, carious lesions, mobility, large amount of plaque, dental calculus, and periodontal pockets. About the maxillomandibular relationship, the patient presented a class III pattern, when the mandibular teeth assume a more anterior position than normal (**Figure 1(A)**). The panoramic radiograph was requested and the need of extraction all the teeth was confirmed (**Figure 1(B)**). Maxillary immediate complete denture and mandibular overdenture on two single-implants under immediate load were planned.

The patient agreed with planning that was explained to her. She read and signed the Free and Informed Consent Term, as well as the Image Use Authorization Term, authorizing the treatment and the scientific dissemination. The consent and participation of her were optional. Research and dissemination of the results of the project were duly approved by the UFMG Research Ethics Committee (Protocol number: 20532213.5.0000.5149; approval number: 434.361).

The clinical procedures followed the care protocol recommended in the project [17] starting with the adequacy of the oral environment, by removing

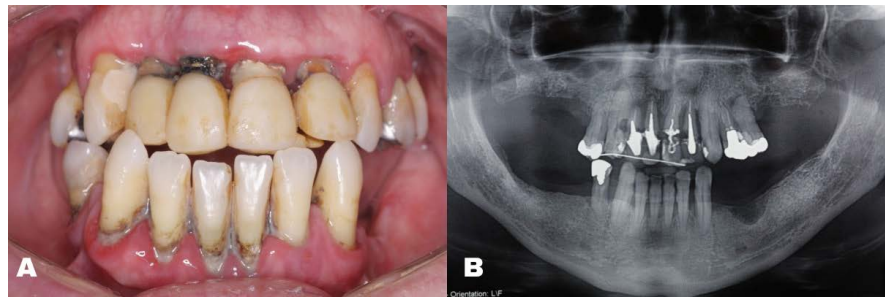


Figure 1. A, frontal intraoral view, showing Angle's Class III occlusal pattern. B, initial panoramic radiography.

factors that retain plaque. Subsequently, all posterior teeth were extracted in both arches. All surgical procedures were preceded by intraoral antiseptics, performed with 0.12% chlorhexidine digluconate for one minute, followed by perioral asepsis with polyvinyl pyrrolidone-iodine (PVPI) with 1% active iodine, and assembly of sterile operative fields. The anaesthetic solution used was articaine 4% + epinephrine 1:100.000 (DFL®, Rio de Janeiro, Rio de Janeiro, Brazil) [18].

Expected an initial period of tissue healing of the posterior regions of 21 days, it was started the immediate prostheses manufacture. The molding was performed with metal trays of stock type Vernes (Tecnodont®, Indaiatuba, São Paulo, Brazil) and irreversible hydrocolloid-alginate (Jeltrate-Dentsply®, Vila Gertrudes, São Paulo, Brazil) to obtain study models in type III stone plaster (Asfer®, São Caetano do Sul, São Paulo, Brazil). On the models, individual trays were made in self-polymerizing acrylic resin (JET®, Campo Limpo Paulista, São Paulo, Brazil), to perform the functional molding of the jaws. Low fusion godiva was used for peripheral sealed (Godiva Exata; Nova DFL, Rio de Janeiro, Brazil) and irreversible hydrocolloid-alginate (Jeltrate; Dentsply®, Vila Gertrudes, São Paulo, Brazil). After obtaining the functional models in type III stone plaster (Asfer®, São Caetano do Sul, São Paulo, Brazil), test bases were made in chemically activated acrylic resin (JET®, Campo Limpo Paulista, São Paulo, Brazil) and wax planes (7 wax, Polidental®, Cotia, São Paulo, Brazil). The wax planes were adjusted, intermaxillary relations were recorded (vertical dimension of occlusion and centric relation) and the models were assembled in a semi-adjustable articulator (Bioart®, São Carlos, São Paulo, Brazil). It was defined the size, shape, and color of the teeth to assemble, using the mold chart (Biotone-Dentsply®, Vila Gertrudes, São Paulo, Brazil). After the aesthetic and functional proof of artificial teeth (only in the posterior regions), the prostheses were completed by removing the remaining teeth present in the models, complementing the assembly in the anterior region (saddle and teeth), and pressing in muffles. In this step, tried to revert the relationship from Class III to Class I, from Angle, which would improve both aesthetics and chewing.

When the prostheses were installed in oral cavity, they received antiseptics, using 2% chlorhexidine for 30 minutes. The anterior superior teeth were ex-

tracted, with appropriate bone adjustments, followed by the incorporation of the maxillary immediate complete denture. The natural lower teeth were adjusted using high-rotation wear to fit the contours of the maxillary prosthesis. The patient was instructed not to remove the prosthesis for 24 hours to control the post-surgical edema, under the risk of being unable to fit it. Re-evaluations were performed with 1, 3, 7, and 14 days, making the necessary adjustments. After 14 days, anteroinferior teeth were extracted and the implants were installed in the interforaminal region. After bone settling and flattening of the edge with a tungsten drill (Maxicut PM-Edenta®, St.Gallen, Switzerland), under irrigation, two 15 mm deep surgical sites were prepared following a sequence of surgical cutters (Surgical Kit - Neodent®, Curitiba, Paraná, Brazil): a spear, 2 mm, pilot 2/3, 2.8 mm and 3.0 mm, mounted in contra-angle (Koncept 20: 1 contra-angle reducer-Kavo®, Berlin, Germany) and implant motor (Koncept Surg Surgical Motor-Kavo®, Berlin, Germany), under constant irrigation with saline. Then, the implants (Titamax TI Cortical - Neodent®, Curitiba, Paraná, Brazil), with external connection, with 3.75 mm in diameter and 15 mm in length, were installed with a manual ratchet (Surgical Kit-Neodent®, Curitiba, Paraná, Brazil). As good primary stability (60 Ncm) was achieved in both implants, the mandibular overdenture was captured under immediate load. The retention system chosen was the ball-type. Using a tungsten drill (Maxicut PM-Edenta®, St. Gallen, Switzerland), space was created, inside the prosthesis, to accommodate the metallic capsule of the polymeric ring, captured with chemically activated acrylic resin (JET®, Campo Limpo Paulista, São Paulo, Brazil). In a first occlusal assessment and preliminary adjustments, a class I occlusal pattern was observed, with molar and canine keys and horizontal (overjet) and vertical (overbite) overlap between the anterior teeth (**Figure 2(A)**). The patient was taught how to remove and replace the overdenture and was instructed on the care to be taken with the prostheses and with the implanted units. She was instructed not to remove the mandibular prosthesis within the first 24 hours. The patient was reassessed at one and three days, for adjustments, and the sutures were removed after seven days. After thirty days, it was necessary to adjust the acrylic base, due to small ulcerations. In this case, the use of Omcilon A in orabase was recommended (**Figure 2(B)**).

After three months, the necessary relined was performed, both in the maxillary immediate complete denture and in the mandibular overdenture. Where appropriate, prostheses were relined with heat-polymerized acrylic resin or replaced (denture retention absence). Denture stability, retention and occlusion were re-evaluated and adjusted. All patients were scheduled for follow-up appointments. In each visit, occlusion, denture stability, retention and hygiene of the prosthesis were checked. Criteria to evaluate the implant survival were as follows: absence of pain, exudation or suppuration, edema, peri-implant inflammation and implant mobility. After the necessary adjustments, the patient was discharged (**Figure 3(A)** & **Figure 3(B)**), and included in the maintenance program offered by the extension project, being followed up every six months

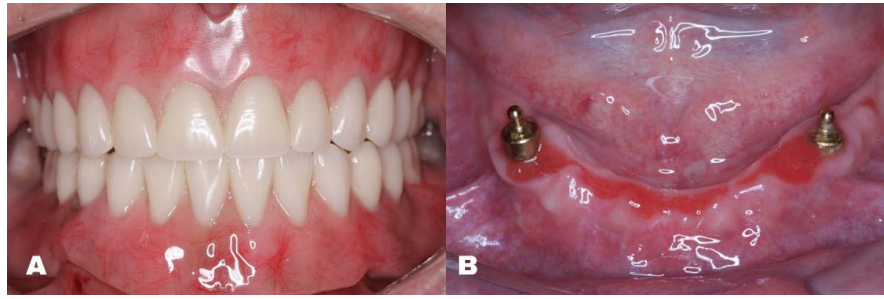


Figure 2. A, intra-oral frontal view of the immediate result. B, control with 30 days with the presence of ulcerations. Need for adjustments to the acrylic base.

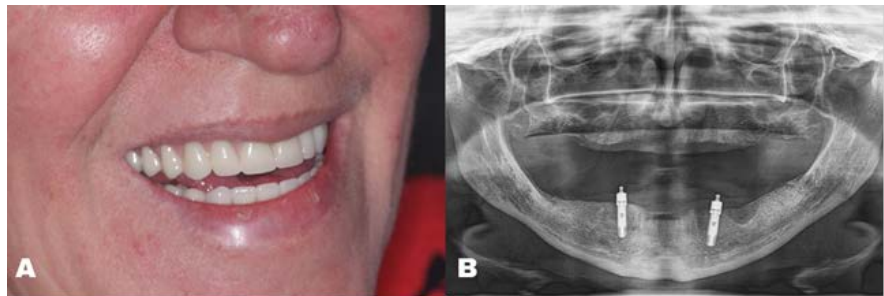


Figure 3. A, clinical control with 3 months, after rebasing of prostheses. B, panoramic radiography in the control at 3 months.

for clinical evaluations and exchange of polymeric rings, when necessary, due to their natural wear.

3. Discussion

Some difficulties are observed in patients with the absence of occlusal harmonies, such as masticatory discomfort. In patients whose remaining teeth are indicated for extraction, there is a concern with the facial appearance, a constant state of anxiety, and in some cases of self-recrimination for neglecting their oral health in the past and worry about the perception of others [19]. For those, treatment with dental prostheses provided a significant improvement in oral functions and “oral well-being”, both in short and long term perspectives [20]. Replacing teeth through oral rehabilitation is essential to restore the masticatory function, the stability of occlusal contacts and supporting structures, phonetics, aesthetics, provide comfort to patient and, also, to restore the balance of stomatognathic system [21].

Many patients who use total removable dentures report difficulty in chewing, observing a change in the individual’s diet and nutrition pattern. The treatment protocol that includes a mandibular overdenture with two implants demonstrates a significant gain in prosthesis retention and stability [22]. Also, it can have a strong positive impact on overall health, particularly for adults and elderly people vulnerable to malnutrition [23].

The patient in the present clinical case had dental-periodontal involvement and sought an aesthetic and functional gain with her rehabilitation. The imme-

mediate complete denture, installed immediately after tooth extractions, provides many advantages, for example, gain in aesthetics, phonetics, and chewing. Also, it's visible the psychological gain since the patient does not live the social embarrassment. Another benefit is that rehabilitation works as a protection to the surgery site, providing bleeding control. Besides, the natural remaining natural teeth often facilitate the maintenance of the vertical dimension of occlusion, since the patient does not experience a prolonged period of edentulism [24].

However, there are some limitations of immediate complete denture therapy, which are related to the difficulties of the techniques associated with the preparation of the prosthesis. As immediate complete dentures are constructed before the extraction of the remaining teeth, some significant challenges arise, often added to an unfavorable bone and tissue contour. Relining procedures are usually necessary, due to the changes on alveolar ridges after the extractions. Thus, the retention of the prosthesis is not compromised. Therefore, patients will need time in accommodation and attendance in the adjustment and maintenance sessions of the prostheses [25]. Other limitation of immediate dentures is the absence of aesthetics proof. Anterior teeth can be a critical area for patients and the absence the aesthetics proof may compromise the aesthetics results.

Immediate implant-retained overdentures have been widely used. It offers the reduction in the healing period and the early use of prostheses. This has become an attractive therapy since over the years the patient's expectations have increased concerning comfort in chewing and the prosthetic result [23]. Despite some studies point out the risk of this protocol in teeth involved with infectious processes, such as the presence of periodontal and periapical disease [26], other studies indicate that immediate loading offers greater stability and has high implant success rates [24]. An implant survival rates of 98.9% was observed by some authors [27] after 1 year and 100% by others [28] after 2 years of follow-up. These findings are consistent with the case report in this study because there was no implant lost related to the overdenture.

For the immediate loading protocol's success, some factors related to surgical and prosthetic aspects must be considered, such as primary stability, implant geometry, surgical technique, bone quality and quantity, and bone occlusal forces [25]. Thereby, a rigid protocol was applied, such as full alveolar debridement, osteotomy, full rinsing, pre and post-operative antibiotics, the use of long implants, careful occlusal adjustment, recommendations for overnight prosthesis removal, and the adoption of a softer diet for the first few months [29], which guaranteed the success of the treatment using immediate loading, including in periodontal disease sites.

Fixed implant-supported prostheses are an alternative to implant rehabilitation treatment that allows patients to have new fixed teeth. Selection of which type depends on the patient bone volume and soft tissue conditions in addition to economic factors [28]. In the reported case, the patient's best indicated treatment was a rehabilitation with a maxillary immediate complete denture and a

mandibular overdenture on implants, which represented lower costs for the patient.

Regarding the occlusal pattern of the treatment performed, it was possible to observe that the patient had an altered maxillary/mandibular relationship, such as Angle's Class III. The use of the immediate complete denture helped to visualize the aesthetic and functional result and, thus, made it possible to achieve a satisfactory final aspect. The reversion to Angle's class I standard guaranteed a favorable aesthetic and better functional condition. A balanced occlusion pattern was achieved, with adequate overbite and overjet. The midline in the maxilla coincided with the mandible and the patient developed a more aesthetic lip profile.

A Class III malocclusion can be corrected with a variety of treatment approaches, including orthognathic surgery and orthodontic therapy [26]. The age of the patient, severity of the malocclusion, patient's chief complaint, clinical examinations, and cephalometric analysis will assist in the treatment of choice. Generally, orthognathic surgery is recommended for young patients with larger dentoskeletal discrepancies, while orthodontics is recommended for milder discrepancies [27]. Nevertheless, the decision as to which treatment should be chosen is not always an easy task especially when the condition of the patients' remaining teeth is unsatisfactory. In the reported case, there was an indication for tooth extraction and the rehabilitation with prostheses, which provided improvement in chewing, aesthetics and allows the malocclusion correction.

Other studies rehabilitated a pseudoskeletal class III relationship with two implant-supported bar retained overdentures using clips for retention on mandible, and for the maxilla, a combination of implant placement, sinus augmentation, and classic prosthodontic treatment on an implant-supported bar. Patient reported a high level of satisfaction with the dentures and an improved quality of life [30]. Another clinical case report described a treatment for an edentulous patient with an atrophic maxilla and severe class III malocclusion. However, in this study, they used an implant-supported overdenture retained with horizontal path insertion to compensate the severe class III malocclusion, where the primary and secondary structures were produced using CAD/CAM techniques [31].

In the case of the patient's follow-up, in one of the visits was observed presence of ulcers in the region of the lower ridge. With this, the prosthesis was adjusted, and an ointment was prescribed based on a synthetic corticosteroid (Omcilon-A Orabase) and mouthwash with warm water, which was enough to revert the condition in question. The evaluations were performed by clinical examination, where the probing depth of the implants, absence of pain, mobility, peri-implant inflammation, and suppuration were measured. No changes were observed, and the patient was satisfied with the proper functioning of her prostheses.

4. Conclusion

Immediate complete denture represents an advantageous and effective clinical

procedure for patients who will inevitably lose their remaining teeth. The treatment protocol that combined the use of a maxillary immediate complete denture and a mandibular implant-retained overdenture in immediate loading was shown to be beneficial. At the end of the treatment, the patient was reverted from a class III to I standard, and the relation of molars and canines in occlusion key was obtained, ensuring excellent facial aesthetics and functional condition.

Acknowledgements

The authors would like to thank Neodent (Curitiba, Brazil) for providing the implants and prosthetic components used in this study.

The authors would like to thank Dentisply (São Paulo, Brazil) for providing the artificial teeth used in this study.

The authors would like to thank PROEX/UFMG for providing the financial support for the Immediate Complete Denture/Overdenture Project.

Conflicts of Interest

The authors declare no conflicts of interest regarding the publication of this paper.

References

- [1] Doornewaard, R., Glibert, M., Matthys, C., Vervaeke, S., Bronkhorst, E. and de Bruyn, H. (2019) Improvement of Quality of Life with Implant-Supported Mandibular Overdentures and the Effect of Implant Type and Surgical Procedure on Bone and Soft Tissue Stability: A Three-Year Prospective Split-Mouth Trial. *Journal of Clinical Medicine*, **8**, 773. <https://doi.org/10.3390/jcm8060773>
- [2] Gooya, A., Ejlali, M. and Adli, A.R. (2013) Fabricating an Interim Immediate Partial Denture in One Appointment (Modified Jiffy Denture). A Clinical Report. *Journal of Prosthodontics*, **22**, 330-333. <https://doi.org/10.1111/j.1532-849X.2012.00950.x>
- [3] Shah, F.K., Gebreel, A., Elshokouki, A., Habib, A.A. and Porwal, A. (2012) Comparison of Immediate Complete Denture, Tooth and Implant-Supported Overdenture on Vertical Dimension and Muscle Activity. *The Journal of Advanced Prosthodontics*, **4**, 61-71. <https://doi.org/10.4047/jap.2012.4.2.61>
- [4] Prakash, V. (2008) Prosthetic Rehabilitation of Edentulous Mandibulectomy Patient: A Clinical Report. *Indian Journal of Dental Research*, **19**, 257-260. <https://doi.org/10.4103/0970-9290.42961>
- [5] Dzambas, L., Gnjata, S. and Vukic, Z. (2012) Life Quality of the Elderly with Immediate Total Dentures. *Archives of Biological Sciences*, **64**, 1141-1145. <https://doi.org/10.2298/ABS1203141D>
- [6] Crum, R.J. and Rooney Jr., G.E. (1978) Alveolar Bone Loss in Overdentures: A 5-Year Study. *Journal of Prosthetic Dentistry*, **40**, 610-613. [https://doi.org/10.1016/0022-3913\(78\)90054-9](https://doi.org/10.1016/0022-3913(78)90054-9)
- [7] Liddelow, G.J. and Henry, P.J. (2007) A Prospective Study of Immediately Loaded Single Implant-Retained Mandibular Overdentures: Preliminary One-Year Results. *Journal of Prosthetic Dentistry*, **97**, S126-S137. [https://doi.org/10.1016/S0022-3913\(07\)60016-X](https://doi.org/10.1016/S0022-3913(07)60016-X)
- [8] Miranda, S.B., Possebon, A.P.R., Schuster, A.J., Marcello-Machado, R.M., de Re-

- zende Pinto, L. and Faot, F. (2019) Relationship between Masticatory Function Impairment and Oral Health-Related Quality of Life of Edentulous Patients: An Interventional Study. *Journal of Prosthodontics*, **28**, 634-642. <https://doi.org/10.1111/jopr.13070>
- [9] Salman, A., Thacker, S., Rubin, S., Dhingra, A., Ioannidou, E. and Pietro, S.G. (2019) Immediate versus Delayed Loading of Mandibular Implant-Retained Overdentures: A 60-Month Follow-Up of a Randomized Clinical Trial. *Journal of Clinical Periodontology*, **46**, 863-871. <https://doi.org/10.1111/jcpe.13153>
- [10] Attard, N.J., Laporte, A., Locker, D. and Zarb, G.A. (2006) A Prospective Study on Immediate Loading of Implants with Mandibular Overdentures: Patient-Mediated and Economic Outcomes. *International Journal of Prosthodontics*, **19**, 67-73.
- [11] Chiapasco, M., Gatti, C., Rossi, E., Haefliger, W. and Markwalder, T.H. (1997) Implant-Retained Mandibular Overdentures with Immediate Loading. A Retrospective Multicenter Study on 226 Consecutive Cases. *Clinical Oral Implants Research*, **8**, 48-57. <https://doi.org/10.1111/j.1600-0501.1997.tb00007.x>
- [12] Major, P.W. and el Badrawy, H.E. (1993) Maxillary Protraction for Early Orthopedic Correction of Skeletal Class III Malocclusion. *Pediatric Dentistry Journal*, **15**, 203-207.
- [13] Zhou, Y.H., Hägg, U. and Rabie, A.B. (2001) Patient Satisfaction Following Orthognathic Surgical Correction of Skeletal Class III Malocclusion. *International Journal of Adult Orthodontics and Orthognathic Surgery*, **16**, 99-107.
- [14] Kuliš, A. and Kopač, I. (2017) Prosthodontic Treatment of an Angle III Class Malocclusion: A Case Report. *Quintessence International*, **48**, 625-631. <https://doi.org/10.3290/j.qi.a38705>
- [15] De Clerck, H.J. and Proffit, W.R. (2015) Growth Modification of the Face: A Current Perspective with Emphasis on Class III Treatment. *American Journal of Orthodontics and Dentofacial Orthopedics*, **148**, 37-46. <https://doi.org/10.1016/j.ajodo.2015.04.017>
- [16] Morokuma, M. (2008) Influence of the Functional Improvement of Complete Dentures on Brain Activity. *Nihon Hotetsu Shika Gakkai Zasshi*, **52**, 194-199. <https://doi.org/10.2186/jjps.52.194>
- [17] Discacciati, J., Carvalho, M. and Costa, S. (2012) PTI e Overdentures: Melhorando Estética, Mastigação e Qualidade de vida. *Revista Ciência em Extensão*, **8**, 123-137.
- [18] Discacciati, J., Brilhante Bhering, C.L., Costa, S., Carvalho, M., Mattos, F., Moreira, N. (2020) Immediate Loading of Mandibular Overdenture Retained by Two Not Slanted Implants: Results from Retrospective of 77 Consecutive Cases. *Journal of Investigative and Clinical Dentistry*, In Press.
- [19] Nordenram, G., Davidson, T., Gynther, G., Helgesson, G., Hultin, M., Jemt, T., et al. (2013) Qualitative Studies of Patients' Perceptions of Loss of Teeth, the Edentulous State and Prosthetic Rehabilitation: A Systematic Review with Meta-Synthesis. *Acta Odontologica Scandinavica*, **71**, 937-951. <https://doi.org/10.3109/00016357.2012.734421>
- [20] Ekelund, J.-A., Lindquist, L.W., Carlsson, G.E. and Jemt, T. (2003) Implant Treatment in the Edentulous Mandible: A Prospective Study on Brånemark System Implants over More than 20 Years. *International Journal of Prosthodontics*, **16**, 602-608.
- [21] Lopes Brilhante Bhering, C., Feitosa Henriques, S.E., Mauro da Silva Girundi, F., Edson Miranda, M. and Araújo de Vasconcellos, A. (2017) Full Arch Implant Supported Oral Rehabilitation to Reestablish Esthetic and Function. *International*

Journal of Clinical Dentistry, **10**, 25-33.

- [22] Thomason, J.M., Feine, J., Exley, C., Moynihan, P., Müller, F., Naert, I., *et al.* (2009) Mandibular Two Implant-Supported Overdentures as the First Choice Standard of Care for Edentulous Patients—The York Consensus Statement. *British Dental Journal*, **207**, 185-186. <https://doi.org/10.1038/sj.bdj.2009.728>
- [23] Statement, C. and Most, I. (2003) The McGill Consensus Statement on Overdentures. *Quintessence International*, **34**, 78-79.
- [24] Bouma, L.O., Mansueto, M.A. and Koeppen, R.G. (2001) A Nontraditional Technique for Obtaining Optimal Esthetics for an Immediate Denture: A Clinical Report. *Journal of Prosthodontics*, **10**, 97-101.
- [25] Massad, J.J. and Cagna, D.R. (2008) Immediate Complete Denture Impressions: Case Report and Modern Clinical Technique. *Dentistry Today* **27**, 58,60,62-65.
- [26] Werbitt, M.J. and Goldberg, P.V. (1992) The Immediate Implant: Bone Preservation and Bone Regeneration. *International Journal of Periodontics & Restorative Dentistry*, **12**, 206-217.
- [27] Mangano, C., Mangano, F.G., Shibli, J.A., Ricci, M., Perrotti, V., d'Avila, S., Piattelli, A. (2012) Immediate Loading of Mandibular Overdentures Supported by Unsplinted Direct Laser Metal-Forming Implants: Results from a 1-Year Prospective Study. *Journal of Periodontology*, **83**, 70-78. <https://doi.org/10.1902/jop.2011.110079>
- [28] Stephan, G., Vidot, F., Noharet, R. and Mariani, P. (2007) Implant-Retained Mandibular Overdentures: A Comparative Pilot Study of Immediate Loading versus Delayed Loading after Two Years. *Journal of Prosthetic Dentistry*, **97**, S138-S145. [https://doi.org/10.1016/S0022-3913\(07\)60017-1](https://doi.org/10.1016/S0022-3913(07)60017-1)
- [29] Casap, N., Zeltser, C., Wexler, A., Tarazi, E. and Zeltser, R. (2007) Immediate Placement of Dental Implants into Debrided Infected Dentoalveolar Sockets. *Journal of Oral and Maxillofacial Surgery*, **65**, 384-392. <https://doi.org/10.1016/j.joms.2006.02.031>
- [30] Zafiroopoulos, G.G., Yoon, T.H. and Abuzayda, M (2019) Rehabilitation of an Extremely Edentulous Atrophic Maxilla with a Pseudoskeletal Class III Relationship. *Case Reports in Dentistry*, **2019**, Article ID: 5696837. <https://doi.org/10.1155/2019/5696837>
- [31] Agustín-Panadero, R., Peñarrocha-Oltra, D., Gomar-Vercher, S., Ferreiroa, A., Peñarrocha-Diago, M. (2015) Implant-Supported Overdenture Manufactured Using CAD/CAM Techniques to Achieve Horizontal Path Insertion between the Primary and Secondary Structure: A Clinical Case Report. *Journal of Advanced Prosthodontics*, **7**, 264-270. <https://doi.org/10.4047/jap.2015.7.3.264>