

# CT Aspects of Psychomotor Delays in Children Aged 0 to 5 Years at Bogodogo University Hospital (Ouagadougou)

Ouedraogo Nina-Astrid<sup>1,2\*</sup>, Tall Mohamed<sup>2</sup>, Sawadogo Adama<sup>2</sup>,  
Kambou Tientore Benilde Marie Ange<sup>1,2</sup>, Yougbare Solange<sup>3</sup>, Cisse Rabiou<sup>1,4</sup>

<sup>1</sup>Laboratory of Radiodiagnosis and Medical Imaging, Joseph Ki Zerbo University, Ouagadougou, Burkina Faso

<sup>2</sup>Radiology Department, Bogodogo University Hospital, Ouagadougou, Burkina Faso

<sup>3</sup>Pediatric Department of the University Hospital of Bogodogo, Ouagadougou, Burkina Faso

<sup>4</sup>Radiology Department, Yalgado Ouédraogo University Hospital, Ouagadougou, Burkina Faso

Email: \*ninawed@hotmail.com

**How to cite this paper:** Nina-Astrid, O., Mohamed, T., Adama, S., Ange, K.T.B.M., Solange, Y. and Rabiou, C. (2022) CT Aspects of Psychomotor Delays in Children Aged 0 to 5 Years at Bogodogo University Hospital (Ouagadougou). *Open Journal of Radiology*, **12**, 92-101.

<https://doi.org/10.4236/ojrad.2022.123011>

**Received:** August 8, 2022

**Accepted:** September 19, 2022

**Published:** September 22, 2022

Copyright © 2022 by author(s) and Scientific Research Publishing Inc.

This work is licensed under the Creative Commons Attribution International License (CC BY 4.0).

<http://creativecommons.org/licenses/by/4.0/>



Open Access

## Abstract

**Background:** Psychomotor delays in children are mainly investigated by CT imaging, due to the low availability and accessibility of magnetic resonance imaging in our context. Our aim was to study the CT aspects of psychomotor retardation (PMR) in children under 5 years of age at the University Hospital of Ouagadougou. **Materials and Methods:** Descriptive study with retrospective collection carried out over a period of twelve months (from September 2020 to August 2021). Our study focused on the reports of cranioencephalic CT scans performed on children aged 0 to 5 years, in whom a clinical diagnosis of psychomotor retardation had been made. Variables studied included socio-demographic data, clinical data, technique of CT examination, description of lesions and normality or not of the conclusion. **Results:** Cranioencephalic CT in children aged 0 - 5 years represented 9.78% of all CT scans performed in this age group. The sex ratio was 1.39. The mean age of the subjects in these reports was  $18.31 \pm 13.97$  months and the modal class was [13 - 24] months. The CT scan was considered pathological in 85.10% of cases ( $n = 57$ ). The most frequently noted encephalic anomalies were cerebral atrophy isolated in 54.4% of the cases ( $n = 31$ ) or associated with other lesions in 30.1% of the cases ( $n = 17$ ). Hydrocephalus was noted in 19.5% of the cases ( $n = 11$ ). **Conclusion:** The lesions were mostly sequelae of cerebral ischaemia or cerebromeningeal infections. There were few cerebral malformations. There was no tumour etiology noted.

## Keywords

CT Scan, Brain, Child, Ouagadougou, Psychomotor Delay

## 1. Introduction

Childhood psychomotor delay (CPD) refers to any significant difference between a child's development and that of normal children of the same age group [1]. In developed countries, the prevalence of PMR is estimated to be 1% - 3% in children under 5 years of age. The aetiologies may be somatic, environmental or unknown [2].

The etiological assessment involves several paraclinical examinations: biological explorations, electroencephalogram, chromosomal and genetic analyses, and medical imaging. The prescription of these investigations is not systematic and depends on the child's personal or family history, particularly ante- and peri-natal.

This is a frequent reason for consultation in paediatrics in our context, as PMR is often the consequence of intrauterine hypoxia and obstetric asphyxia, constituting one of the top five neonatal pathologies in Burkina Faso [3] [4] [5] [6].

Medical imaging of the brain includes ultrasound, computed tomography (CT) and magnetic resonance imaging (MRI). Although MRI is the most suitable examination for analysing the brain in psychomotor delays, in our context, this examination is not widely available or accessible. There is no functional MRI in public facilities in Burkina Faso. The average cost of a brain MRI scan is 5.5 times the guaranteed minimum wage, which is 30,684 XOF, or \$61 [7]. Cranioencephalic CT is therefore the examination prescribed in first intention, especially since free care has been put in place in children under 5 years of age, since 2016, facilitating accessibility to this modality present in some hospital centres in the city of Ouagadougou [8].

In our context, there have been a few studies devoted to imaging cranioencephalic anomalies on CT, describing the etiologies of macrocrania [9]. But we have not specifically highlighted any imaging aspects of psychomotor delays in children.

Our aim was to study the CT aspects of PMR in children aged 0 to 5 years at the Centre Hospitalier Universitaire de Bogodogo (CHUB) in Ouagadougou.

## 2. Materials and Methods

This was a retrospective descriptive study conducted over a period of twelve months (September 2020 to August 2021). Our study focused on cranioencephalic CT scans performed in children aged 0 - 5 years with a clinical diagnosis of psychomotor delay.

According to the American psychiatric Association, psychomotor delay is defined as a significant delay (at least two standard deviations below the mean on standardised tests) in at least two of the following areas of development: fine or gross motor skills, speech or language, cognition, social or personal sphere and activities of daily living, in children under five years of age.

We included all reports of cranioencephalic CT scans for PMR archived on

the department's computer. We did not include incomplete reports (no section of the report such as indication, technique, results or conclusion).

Data were recorded on an individual survey form (**Annex**). The variables studied were socio-demographic data, clinical data mentioned in the indication of the examination, the technique used to perform the CT examination, the description of the lesions in the results section and the normality or not of the conclusion.

The data were entered and processed on a microcomputer and the analyses were carried out with Epi Info software version 7.2.4.0.

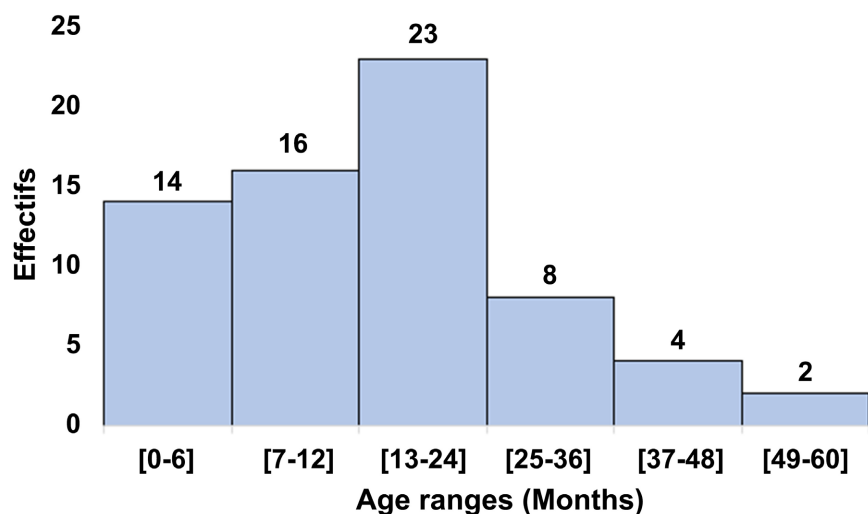
We obtained authorization for data collection from the university hospital authorities. The anonymity of the patients was respected and the confidentiality of the data was preserved.

### 3. Results

The proportion of cranioencephalic CT scans in children aged 0 - 5 years was 9.78% of all CT scans performed for this age group in the department.

**Socio-demographic data.** The reports were from 39 male patients (58%) and 28 female patients (42%), giving a sex ratio of 1.39. The mean age of the subjects in these reports was  $18.31 \pm 13.97$  months. The modal class was [13 - 24] months, with a frequency of 34.33% (**Figure 1**).

**Origin of CT requests.** The majority of patients came from the CHUB in 98.51% of cases. CT requests came from the Paediatric Department in 85.07% of cases. All reports mentioned the notion of PMR. The child's background was noted in 49.30% of cases (**Table 1**). Neonatal distress was the most frequently noted history in 23 cases (69.7%) followed by neonatal infection in 7 cases (21.2%). Some signs or symptoms were associated with PMR in the reason for the examination in 31.34% of cases (**Table 2**). These were mainly convulsions in 8 cases, tone disorders in 4 cases and macrocrania in 3 cases.



**Figure 1.** Distribution of the sample by age.

**Table 1.** History mentioned in the “reason for examination” section.

Background	Frequency (n = 33)	Proportions (%)
Neonatal distress	23	69.7
Neonatal infection	7	21.2
Prematurity	2	6
Neonatal jaundice	1	3

**Table 2.** Signs and symptoms associated with psychomotor delay.

Associated signs	Frequency (n = 21)	Proportions (%)
Convulsions	8	38
Tone disorders	4	19
Macrocrania	3	14.4
Language disorders	2	9.5
Fontanel bulge	2	9.5
Trisomal facies	1	4.8
Dorsolumbar swelling	1	4.8

**Technique for carrying out the examination.** Fifty-one reports, *i.e.* 76.12% of the sample, mentioned an injection of iodinated contrast medium during the examination. The notion of whether or not the child was sedated during the examination did not appear on the report.

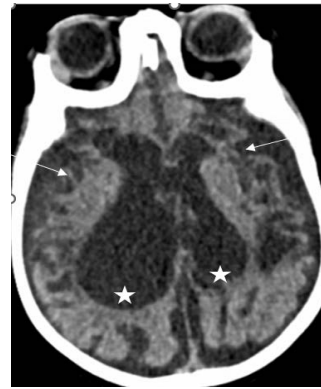**Results of the reports.** The CT scan was considered pathological in 85.10% of cases (n = 57). The most frequently noted brain abnormalities were cerebral atrophy (**Figure 2**). It was isolated in 31 cases (54.4%) or associated with other anomalies in 17 cases (30.1%). Hydrocephalus was noted in 11 children (19.5%) (**Figure 3**). These CT abnormalities are listed in **Table 3**.

#### 4. Discussion

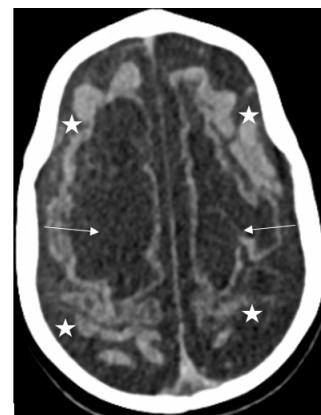
Our study showed that CT scans, prescribed to explore PMR in children aged 0 to 5 years, were pathological in 85.10% of cases. It was most often performed between 13 and 24 months of age. The most frequently noted antecedents were neonatal suffering or asphyxia and infections. The most frequently noted CT anomalies were cerebral atrophy and hydrocephalus.

Although MRI is the reference examination for an exhaustive lesion assessment, CT is prescribed in our context as the first line of defence because of the availability of this modality in the university hospital and especially because of its accessibility linked to the policy of free care for children aged 0 to 5 years. The total number of CT examinations performed in paediatrics represented one fifth of the scans performed in the department during the study period.

However, cranioencephalic CT is less efficient than MRI outside the context of trauma. However, it can detect cranioencephalic anomalies and calcifications.



**Figure 2.** Cranioencephalic CT axial section, without iodinated contrast injection, showing biventricular hydrocephalus (stars), with cerebral atrophy predominating in the temporal regions (arrows).



**Figure 3.** Cranioencephalic CT axial section, passing through the semi-oval centres, without injection of iodinated contrast medium showing bilateral fronto-parietal brain atrophy (stars), associated with cystic patches of encephalomalacia (arrows).

**Table 3.** Cranioencephalic CT lesions described.

Cranioencephalic anomalies	Frequency (n = 57)	Proportions (%)
Isolated cerebral atrophy	31	54.4
Cerebral atrophy and encephalomalacia	5	8.9
Cerebral atrophy and hydrocephalus and encephalomalacia	5	8.9
Cerebral atrophy and hydrocephalus	5	8.9
Isolated encephalomalacia	4	7
Subependymal abscess	1	1.7
Cerebral atrophy and Blake’s pouch cyst	1	1.7
Cerebral atrophy and schizencephaly	1	1.7
Isolated hydrocephalus	1	1.7
Hydrocephalus and encephalomalacia	1	1.7
Dandy Walker malformation	1	1.7
Meningo encephalitis	1	1.7

However, it is less effective in analysing the gyration of the cerebral cortex, the white matter and the cerebellum. The majority of CT scans were performed without injection of contrast medium in 76.12% of cases. This lack of contrast injection may mask abnormalities in parenchymal enhancement, expansive processes or the analysis of vascular structures. The contrast medium and injection material are expensive, approaching the cost of the CT scan, and are not included in the free care policy.

CT scanning was most often performed between 13 and 24 months of age. Our results corroborated those of several authors, who noted a high prevalence of the diagnosis of PMR in children under two years of age, corresponding to an age when parents are most concerned about delays in certain acquisitions [3] [10] [11].

The notion of neonatal suffering was the most frequently noted antecedent in 69.7% of cases, as well as cerebro-meningeal infections in 21.2% of cases. It is a real tragedy in our context of a country with limited resources, as in several African countries. Amadou *et al.* [10] noted respectively 62% of a history of neonatal suffering and 26% of a history of cerebral infection in their sample of children investigated for PMR.

Koueta *et al.* [6] showed that neonatal distress ranked fifth among neonatal pathologies in Burkina Faso and caused about 20.9% of deaths in 2011. It is essentially due to three delays: delay in decision-making, delay in access to health services and delay in access to appropriate care. It accounts for 19.8% of neonatal admissions in Ouagadougou according to Ouédraogo *et al.* [5] and 15.6% according to Okoko *et al.* in Brazzaville [12] and 22.8% for Ameur *et al.* [13] in Tunisia. Neonatal suffering is reflected on imaging by hypodense ischaemic patches at the onset and then at the aftermath, by cerebral atrophy, present in our sample in 71.64% of cases. It appeared isolated or associated with other lesions.

Hydrocephalus was the second most common lesion described, with a predominance of tetra ventricular forms. In Africa, the aetiologies of hydrocephalus are mainly infectious, as noted by Amadou *et al.* in 56.36% of cases, and 43.4% according to Tapsoba *et al.* [14]. A history of neonatal infection, noted in 21.2% of cases, may explain these CT lesions. They were the first cause of death in neonatology [6]. According to Nagalo *et al.* [3] in Burkina Faso, these infections are most often due to congenital causes (malaria), specific perinatal infections or acquired after birth. They constitute a real challenge in our context.

Cerebral malformations were uncommon in our study. Three reports mentioned malformative aetiologies: a Blake's pouch cyst, a schizencephaly and a Dandy Walker malformation. Some authors noted higher prevalences of cerebral malformations but used MRI as the modality of exploration: 9% and 40% noted respectively by Belaroussi *et al.* [15] and Nasri *et al.* [16] and Ameur *et al.* [13]. Other cerebral malformations have been reported during the exploration of RPM, notably a congenital porto-cava fistula described by Magne *et al.* [17] and a hemimegaephalia associated with cortical anomalies reported by Diarra *et al.*

[18].

We did not note any tumour cause in our sample, as did other authors such as Amadou *et al.* [10] who found 28.57% tumours in their sample of PMR. However, they included children up to the age of 16 in their study population. In addition, the radiological explorations combined MRI and CT.

The CT scan was mentioned as normal in 14.93% of the reports, close to the rates noted by Amadou *et al.* [10] who found a rate of normal examinations in 17% of the cases, during the exploration of PMR. These results can be explained on the one hand by the low sensitivity of CT in the detection of certain cerebral anomalies, particularly of the white matter, and on the other hand by the fact that there are several non-organic aetiologies of PMR that do not affect the morphological aspect of the brain.

This study does have limitations inherent to the monocentric and retrospective nature of the study, as well as the statistical unit described, namely the report. A more exhaustive and multicentric study would allow a better mapping of encephalic lesions in children with psychomotor delay.

## 5. Conclusions

CT scans show abnormalities in most cases of psychomotor delay, dominated by sequelae of anoxic-ischaemic lesions due to the high prevalence of neonatal suffering in our context. Hydrocephalus may also be sequelae of peri- or post-natal infections, which are common in a country with limited resources and are the main cause of neonatal deaths in Burkina Faso.

Although the free health care system in place allows for CT scans of PMR in children aged 0 to 5 years, what is the real impact of these examinations on the care of these children, which constitute a real burden for families?

Access to MRI remains an imperative to better explore cranioencephalic lesions in these children, most of whom come from poor families. But above all, the education of the population, the improvement of human and material resources for a better ante- and peri-natal follow-up seems necessary to reduce this perinatal anoxia, responsible for the major part of the CT lesions noted.

## Conflicts of Interest

The authors declare no conflicts of interest regarding the publication of this paper.

## References

- [1] Bompard, Y., Aufrant, C., Massonnaud, M., Gantzer, A. (1986) La souffrance cérébrale asphyxique du nouveau-né, E.M.C., (Paris, France), Pédiatrie, 4002 S60, 7-1987. Développement et maladie de l'enfant Edition Masson, Paris.
- [2] Berquin, P. and Le Moing, A.G.L. (2016) Chapitre 15. Démarche diagnostique neuropédiatrique des troubles cognitifs. In: Mazet, P., Xavier, J., Guilé, J.-M., Plaza, M. and Cohen, D., Eds., *Troubles intellectuels et cognitifs de l'enfant et de l'adolescent*, Lavoisier, Cachan, 185-196.



- <https://www.cairn.info/troubles-intellectuels-et-cognitifs-de-l-enfant--9782257206091-page-185.htm>
- [3] Nagalo, K., Fousseini, D., François, T.H. and Diarra, Y. (2013) Morbidité et mortalité des nouveau-nés hospitalisés sur 10 années à la Clinique El Fateh-Suka (Ouagadougou, Burkina Faso). *The Pan African Medical Journal*, **14**, Article No. 153. <https://doi.org/10.11604/pamj.2013.14.153.2022>  
<https://www.ncbi.nlm.nih.gov/pmc/articles/PMC3683511/>
- [4] Zoungrana-Yameogo, W.N., Dahourou, D.L., Diallo, A.H., Sangho, O., Nikiema, E., Tougouma, S., et al. (2021) Mortalité néonatale au centre hospitalier universitaire de Tengandogo, Ouagadougou, Burkina Faso: Une étude de cohorte rétrospective. *Journal of Interventional Epidemiology and Public Health*, **4**, Article No. 4. <https://www.afenet-journal.net/content/series/4/3/4/full/>
- [5] Ouédraogo Yugbaré, S.O., Coulibaly, G., Kouéta, F., Yao, S., Savadogo, H., Dao, L., et al. (2015) Profil à risque et pronostic néonatal de l'asphyxie périnatale en milieu hospitalier pédiatrique à Ouagadougou. *Journal de Pédiatrie et de Puériculture*, **28**, 64-70. <https://doi.org/10.1016/j.jpp.2015.02.003>
- [6] Kouéta, F., Yugbaré, S.O.O., Dao, L., Dao, F., Yé, D. and Kam, K.L. (2011) Audit médical des décès néonataux selon le modèle des trois retards, en milieu hospitalier pédiatrique de Ouagadougou. *Cahiers d'études et de recherches francophones/Santé*, **21**, 209-214. <https://doi.org/10.1684/san.2011.0271>
- [7] <http://www.ilo.org/dyn/travail/docs/1744/Burkina>
- [8] <https://www.ilo.org/dyn/natlex/docs/ELECTRONIC/104122/126889/F331618513/BFA-104122.pdf>
- [9] Diallo, O., Ouattara, B., Zanga, M., Tiemtore-Kambou, B., N'de, N., Dao, B.A., et al. (2017) Diagnostic étiologique des macrocrâniées explorées par TDM au Burkina Faso (70 cas). *Journal Africain d'Imagerie Médicale*, **8**, 159-163.
- [10] Amadou, A., Sonhayé, L., Assih, K., Hemou, M., Kombate, D., D'almeida, D.M., et al. (2017) Imagerie Des Retards Psychomoteurs De L'enfant A Lome. *European Scientific Journal*, **13**, 258-268. <https://doi.org/10.19044/esj.2017.v13n27p258>
- [11] Amadou, A., Adoko, A.L., Assih, K., Agbangba, A.K., Sonhayé, L., Tchaou, M., et al. (2017) Imagerie dans les malformations cérébrales congénitales à Lomé. *Journal de la Recherche Scientifique de l'Université de Lomé*, **19**, 347-358.
- [12] Okoko, A.R., Ekouya-Bowassa, G., Moyen, E., Togho-Abessou, L.C., Atanda, H.L. and Moyen, G. (2016) Asphyxie périnatale au centre hospitalier et universitaire de Brazzaville. *Journal de Pédiatrie et de Puériculture*, **29**, 295-300. <https://doi.org/10.1016/j.jpp.2016.09.003>
- [13] Ameer, S.B., Aloulou, H., Sfaihi, L., Yaich, S., Mnif, Z., Kamoun, T., et al. (2014) Imagerie cérébrale de l'épilepsie de l'enfant. Etude de 140 observations. *La Tunisie Medical*, **92**, 24-28.
- [14] Tapsoba, T.L., Sanon, H., Soubeiga, K.J., Ouattara, T.F., Kabré, A. and Cissé, R. (2010) Aspects épidémiologiques, cliniques et tomodensitométries des hydrocéphalies chez les enfants de zéro à 15 ans (à propos de 53 patients colligés au centre hospitalier universitaire Yalgado Ouédraogo de Ouagadougou: CHU YO). *Médecine Nucléaire*, **34**, e3-e7. <https://doi.org/10.1016/j.mednuc.2010.07.004>
- [15] Belaaroussi, S., Berrada, G., Badi, F.E., Salam, S., Chbani, K., Laoudiyi, D., et al. (2019) Apport de l'IRM dans le diagnostic des malformations corticales. *Pan African Medical Journal-Clinical Medicine*, **1**, Article No. 67. <https://doi.org/10.11604/pamj-cm.2019.1.67.20987>
- [16] Nasri, S., Aichouni, N., Neftah, C., Marzouki, Z., Boutahar, I., Amar, A.O., et al.



- (2017) Apport de l'IRM dans les malformations cérébrales chez l'enfant. *Journal of Neuroradiology*, **44**, 108. <https://doi.org/10.1016/j.neurad.2017.01.088>
- [17] Magne, N., Franchi-Abella, S., Hassani, A., Vasies, I., Dacher, J.N. and Vivier, P.H. (2020) Un retard psychomoteur expliqué par une fistule porto-cave. *Journal d'imagerie diagnostique et interventionnelle*, **3**, 210-214. <https://doi.org/10.1016/j.jidi.2020.03.001>
- [18] Diarra, E.A.A., Yapo, F.B., Tanoh, C., Yapo, C., Muriele, A., Assouan Ange, K., *et al* (2013) Epilepsie et anomalie du développement cérébral illustrée par une observation d'hémimégalencéphalie: Revue de littérature. *African & Middle East Epilepsy Journal*, **2**, 7-10.

## Annex

### Collection sheet: CT aspects of psychomotor delays in children at CHU-B

#### Survey form n°

Date of examination /...../...../.....

#### Administrative data

Age (years):

Sex: M/...../ F/...../

Medical structure: University Hospital /...../ Medical Centre /...../ Clinic/...../  
CSPS /...../ Other /...../

Requesting department: Paediatrics/...../ Other specify .....

Quality of prescriber: specialist: /...../ (specify specialty) .....

Generalist/...../ intern /...../ other /...../

Prescriber's contact .....

#### Clinical data

Mention of previous history: Yes/...../ No /...../

Ante-natal distress/...../ Prematurity/...../ Neonatal care /...../

Neurological condition /...../ other/...../

Head circumference: normal/...../ increased/...../ decreased/...../

Diagnostic hypothesis mentioned: Yes /...../ No/...../

#### Technique for performing the examination

Injection of contrast medium: Yes/...../ N/...../

Sedation: Yes/...../ No/...../ not mentioned /...../

#### CT aspects

##### - Topography of lesions

Intra axial /...../ extra axial /...../

Infra tentorial /...../ supra tentorial /...../

##### - CT lesions:

Cerebral atrophy: location .....

Porencephalic cavity /...../

Hydrocephalus: uni ventricular/...../ bi ventricular/...../ tri ventricular /...../ tetra  
ventricular/...../

Infection: type.....

Calcifications /...../

Brain tumor: type .....

Cerebral malformation: type ....

##### - CT diagnosis

Normal /...../ Abnormal /...../

Cerebral atrophy /...../ Anoxic-ischemic lesions /...../

Brain infections /...../ Tumours /...../

Encephalomalacia /...../

Malformations: yes /...../ No /...../

If yes specify type.....

Other:.....