

Anterior Chamber Depth Changes in Narrow Iridocorneal Angles after Phacoemulsification

Md. Ariful Islam^{1*}, Abir Bin Sajj², Tohura Sharmin³, Md. Sanwar Hossain⁴, Md. Shafiqul Islam⁵

¹Department of Ophthalmology, Combined Military Hospital (CMH), Dhaka, Bangladesh

²Vision Eye Hospital, Dhaka, Bangladesh

³Department of Community Medicine, Ad-Din Women's Medical College, Dhaka, Bangladesh

⁴Department of Ophthalmology, Dr. Sirajul Islam Medical College & Hospital, Dhaka, Bangladesh

⁵Department of Ophthalmology, Bangabandhu Sheikh Mujib Medical University (BSMMU), Dhaka, Bangladesh

Email: *shemul.oph@gmail.com

How to cite this paper: Islam, Md.A., Sajj, A.B., Sharmin, T., Hossain, Md.S. and Islam, Md.S. (2023) Anterior Chamber Depth Changes in Narrow Iridocorneal Angles after Phacoemulsification. *Open Journal of Ophthalmology*, 13, 187-198.
<https://doi.org/10.4236/ojoph.2023.132016>

Received: November 23, 2022

Accepted: May 7, 2023

Published: May 10, 2023

Copyright © 2023 by author(s) and Scientific Research Publishing Inc. This work is licensed under the Creative Commons Attribution International License (CC BY 4.0).

<http://creativecommons.org/licenses/by/4.0/>



Open Access

Abstract

Background: The burden of cataract and glaucoma has been increasing. Primary angle closure occurs as a result of crowded anterior segment anatomy causing appositional contact between peripheral iris and trabecular meshwork. Lens extraction has been proposed as a method of deepening anterior chamber and managing intraocular pressure. **Purpose:** To assess changes in anterior chamber depth after phacoemulsification with intraocular lens implantation in narrow angle eyes. **Design:** Prospective controlled trial (before-after) study. **Method:** The study was conducted from March 2015 to August 2017 among the patients of department of Ophthalmology of BSMMU who were diagnosed as cataract with narrow angles. Anterior chamber angle grading of 2 or less (Shaffer grading) in 3 or more quadrants was considered narrow angle (NA). The purposive type sampling technique was applied to collect sample from the study population, as per inclusion and exclusion criteria. Complete clinical evaluation including history, physical examination, relevant ocular examinations and systemic examinations were performed. In this prospective study, subjects underwent phacoemulsification with foldable lens implantation. A scan ultrasonography was performed preoperatively and 10th and 30th postoperative days of surgery. **Results:** Thirty eyes of 29 patients included in the study, male: female ratio was 1:1, with an overall mean age of 62.03 ± 8.95 years. The mean preoperative central ACD was 2.95 ± 0.35 mm. At 10th and 30th POD mean central ACD were 3.94 ± 0.32, and 3.92 ± 0.28 mm respectively. Mean of increase in central ACD at final follow-up was 0.96 mm (p < 0.05). **Conclusion:** Phacoemulsification with posterior chamber in bag lens implantation can deepen the anterior chamber depth in patients with narrow angles. Based on these findings, it is concluded that phacoemulsification with foldable intraocular lens implantation is an effective tool in dee-

pening the anterior chamber.

Keywords

Anterior Chamber Depth, Phacoemulsification, Iridocorneal Angles, Open Angle, Narrow Angle

1. Introduction

Cataract and glaucoma are ranked as the leading causes of blindness worldwide (51 and 8%, respectively) [1]. In developed countries, glaucoma is the second leading cause of irreversible blindness (after diabetic retinopathy) and this burden tends to increase as the population ages [2] [3] [4].

A similar trend is seen with cataract, whose prevalence is also age-related – the global prevalence of 15.5% rises to 45.9% in those over 75 years and is expected to duplicate by 2020 [5]. Both diseases frequently coexist in the elderly population in a proportion that is likely to increase. Given this data, cataract surgery rises as one of the most common surgical procedures performed worldwide and it has been suggested to be of clinical benefit for both diseases.

During cataract surgery, the cloudy lens is removed or cleaned out and replaced by a clear man-made lens. There are three types of surgical techniques used.

The most common method of cataract surgery is extracapsular surgery. During this cataract surgery, the surgeon makes a medium-sized slit on the side of your cornea. The cloudy central section of the lens is slipped out of the eye in one piece. Then, the surgeon vacuums out the rest of the lens.

Phacoemulsification is also called “small incision cataract surgery”, and is an advanced form of extracapsular cataract surgery. Most cataract removals today are done by phacoemulsification. The incision can be smaller because the harder center section of the lens is liquefied and then vacuumed out.

Based on advanced imaging has demonstrated that the crystalline lens has an important role in the narrowing of the angle by pushing the peripheral iris anteriorly, in particular with the cataractous lens.

As the eye ages the crystalline lens increases significantly in volume. This may initiate a series of anatomical changes, that ultimately lead to increase in IOP observed with aging. As the lens grows, the anterior lens capsule is displaced forward causing the zonules to place anteriorly directed traction on the ciliary body and uveal tract, which in turn compresses the canal of Schlemm and trabecular meshwork, as the ciliary body is displaced forward by the enlarging lens the tendons relax and the space between trabecular plates becomes narrowed [6].

The trabecular meshwork and Schlemm tube pressure increase and aqueous drainage pump failure increase, intraocular pressure tends to increase [7] [8].

With the development of cataract, lens thickness and volume increase. The lens also moves forwards, which is known as a predominant risk factor for pu-

pillary block. The lens gradually thickens and the relative position of the lens' front surface moves forward and above phenomenon is more marked.

Recently, the International Society of Geographical and Epidemiological Ophthalmology labeled eyes with narrow-entry iridocorneal angles as occludable and as primary angle-closure suspects because they have long-term risk for visual morbidity. Eyes with occludable angles are considered to be in a pre-glaucomatous stage and likely to progress to primary angle closure glaucoma (PACG) over the natural history of the condition [9].

In patients with coexisting chronic angle-closure glaucoma and cataract, phacoemulsification surgery alone has been suggested as an initial surgical option for the treatment of glaucoma [10] [11].

Besides removing the opacified lens, phacoemulsification surgery has been suggested to reduce intraocular pressure (IOP) in eyes either with or without glaucoma. It may be in variable magnitude and influenced by several factors, including anterior chamber anatomy and angle configuration (open-angle vs. angle-closure) [12].

It is thought that intraocular pressure (IOP) is an important modifiable risk factor in glaucoma progression. Huang *et al.* (2011) reported that six months after phacoemulsification surgery mean (SD) intraocular pressure reduction was 2.75 (0.60) mmHg in the narrow angle group [13]. Recent studies of phacoemulsification surgery in glaucoma patients have demonstrated intraocular pressure increase by 1.7 mmHg (15%) following cataract surgery in the 14 to 15 mmHg group [14] [15]. Shin *et al.* (2010) reported that mean preoperative anterior chamber depth in the narrow angle group was 2.75 mm. After phacoemulsification surgery anterior chamber depth increased to 3.98 mm [16] [17]. Huang *et al.*, (2011) reported that before phacoemulsification surgery the mean (SD) ACD was 2.23 (0.07) mm in the NA group and mean ACD deepening induced by phacoemulsification surgery was 1.52 (0.04) mm in the NA group [13]. Six months after surgery, the mean (SD) postoperative anterior chamber depth was 3.75 (0.05) mm in the narrow angle group.

This sustained intraocular pressure reduction highlights phacoemulsification surgery as a valuable supplement to the preexisting armamentarium of tube shunt surgery and trabeculectomy. The amount of intraocular pressure decrease seems to be inversely related to preoperative anterior chamber depth (ACD) [18]. Its enhanced safety profile relative to traditional glaucoma surgeries makes it an attractive choice for selective patients, particularly those without severe glaucomatous disease [14] [15].

2. Materials and Methods

2.1. Study Design and Place

This was a prospective controlled trial (before-after) study. The study was performed at Department of Ophthalmology, Bangabandhu Sheikh Mujib Medical University (BSMMU), Dhaka from March 2015 to August 2017.

2.2. Participants

After obtaining permission and ethical approval from Institutional review board (IRB) of BSMMU, a total of 30 patients who underwent phacoemulsification cataract surgery with intra ocular lens (IOL) implantation in the Department of Ophthalmology, BSMMU, were included in the study. Purposive sampling technique was applied.

2.3. Selection Criteria

Inclusion criteria:

- Age—45 years or above having cataract disease
- Eyes with narrow angles (Shaffer grades of 2 or less in 3 or all 4 quadrants) with cataract
- Patients with previous laser peripheral iridotomy who meet the criteria of narrow angle with cataract
- Patients with visually significant cataract

Exclusion criteria:

- Previous penetrating ocular surgery
- Complications related to the cataract surgery (such as posterior capsular rupture and vitreous loss)
- Secondary glaucoma
- Peripheral anterior synechiae
- Topical glaucoma therapy
- Optic nerves graded as having a cup-disc ratio greater than 0.6 (vertical meridian)
- Subluxated cataract
- Previous ocular trauma

2.4. Data Collection and Study Procedure

Patients attending into Department of Ophthalmology, Bangabandhu Sheikh Mujib Medical University (BSMMU), who were diagnosed as case of age-related cataract (Nuclear or cortico-nuclear grade 2 to 4, Post subcapsular cataract) and underwent phacoemulsification surgery with intraocular lens implantation, were the study population.

Complete clinical evaluation including history, physical examination, relevant ocular examinations, and some special ocular examinations like—intraocular pressure, fundus examination, and gonioscopy before and after surgery was done.

Angle assessment by gonioscopy (Sussman Four Mirror Diagnostic Gonioscope) was done under low ambient illumination.

The **Shaffer system**: Describes the angle between the trabecular meshwork and the iris as follows:

- Grade 4: The angle between the iris and the surface of the trabecular meshwork is 45°.
- Grade 3: The angle between the iris and the surface of the trabecular mesh-

work is greater than 20° but less than 45°.

- Grade 2: The angle between the iris and the surface of the trabecular meshwork is 20°. Angle closure is possible.
- Grade 1: The angle between the iris and the surface of the trabecular meshwork is 10°. Angle closure is probable in time.

Surgical technique:

On the day of surgery, all patients received short-acting mydriatic agents (tropicamide 0.8%, phenylephrine 5.0%) for pupil dilation. Topical anesthesia consisting of a single drop of proparacaine 0.5% were administered 3 times at intervals of 5 minutes prior to surgery. After topical anesthesia was administered, a 2.8 mm temporal clear corneal incision was created. Next, 0.1 ml of trypan blue 0.1% was injected to stain the capsule and the anterior chamber was reformed with sodium hyaluronate 2.0%. A continuous curvilinear capsulorhexis with a diameter of approximately 5.0 mm was created with forceps, and cortical-cleaving hydro-dissection and delamination were performed with a 27-gauge cannula. A quadrant divide and-conquer technique was used for phacoemulsification. The cortical remnants were removed with an automated irrigation and aspiration handpiece, and the posterior capsule was polished. A foldable hydrophobic acrylic IOL with a 6.00 mm optic and 13.00 mm haptic diameter (AcrySoft Single Piece, Alcon, Inc.) was then implanted in the capsular bag. Ocular viscoelastic device (OVD) was washed properly. At the end of the operation the surgeon always confirmed that the IOL was accurately implanted in the capsular bag. The corneal incisions were sealed by corneal stromal hydration. Patients were discharged one day postoperatively and were prescribed a standard treatment regimen of dexamethasone 0.1% eye drops every 4 hours and Moxifloxacin 0.5% eye drop for 4 weeks, with tapering doses over the subsequent 4 weeks. Postoperative follow-up visits at the eye clinic were scheduled for 1st, 10th and 30th post-operative day (POD).

All examinations and Shaffer's grading were done by a single person to avoid bias. Surgeries were also done by the same Ophthalmologist.

2.5. Statistical Analysis

Statistical analysis was carried out by using R program. The mean values were calculated for continuous variables. The quantitative observations were indicated by frequencies and percentages. p value < 0.05 was considered as statistically significant.

3. Results

Patients diagnosed with narrow angle with visually significant cataract were the source of the study. The main objective of the study was to assess changes in anterior chamber depth after phacoemulsification with intraocular lens implantation in narrow angle eyes. So, initially 31 eyes of 30 patients were enrolled. But one eye was left due to raised intraocular pressure per-operatively and converted

to small incision cataract surgery. Finally, 30 eyes of 29 patients were kept for study results formulation.

The age and sex distribution of the study participants shows that out of 30 patients 36.7% belonged to age group 51 - 60 years followed by, 36.7% in 61 - 70 years age group. The median age of the respondents was 60.50 years. Minimum age was 45 years and maximum age was 76 years. Among the respondents 50% were male and 50% were female (**Table 1**).

The scatter plot of change in anterior chamber depth in relation to preoperative anterior chamber depth shows the correlation between preoperative anterior chamber depth and change in anterior chamber depth measured at 10th and 30th postoperative days. Here red color indicates change in anterior chamber depth measured at 10th postoperative day and blue color indicates change in anterior chamber depth measured at 30th postoperative day. Here at 10th postoperative day $r = -0.62$ (p value=0.000) which indicates an enough evidence that the lower preoperative anterior chamber depth has a significant association with the change in post-operative anterior chamber depth. At 30th postoperative day $r = -0.69$ (p value 0.000) which also indicates that the lower preoperative anterior chamber depth has a significant association with the change in post-operative anterior chamber depth.

Our observation was shallower anterior chamber depth before phacoemulsification surgery was associated with greater increase in anterior chamber depth after phacoemulsification surgery. And those who have deep anterior chamber before phacoemulsification surgery associated with less increase in anterior chamber depth after phacoemulsification surgery. No difference was found in change in anterior chamber depth in between 10th and 30th postoperative days (**Figure 1**).

The scatter plot of relationship between preoperative average anterior chamber angle and change in anterior chamber depth measured at 10th and 30th post-operative day. Here red color indicates average change in anterior chamber depth measured at 10th postoperative day and blue color indicates average change in

Table 1. Age and sex distribution of the study participants (n = 30).

Variables	Frequency	Percentage (%)
Age (Years)		
45 - 50	4	13.3
51 to 60	11	36.7
61 - 70	11	36.7
71 - 76	4	13.3
Mean ± SD	62.03 ± 8.95	
Sex		
Male	15	50.0
Female	15	50.0

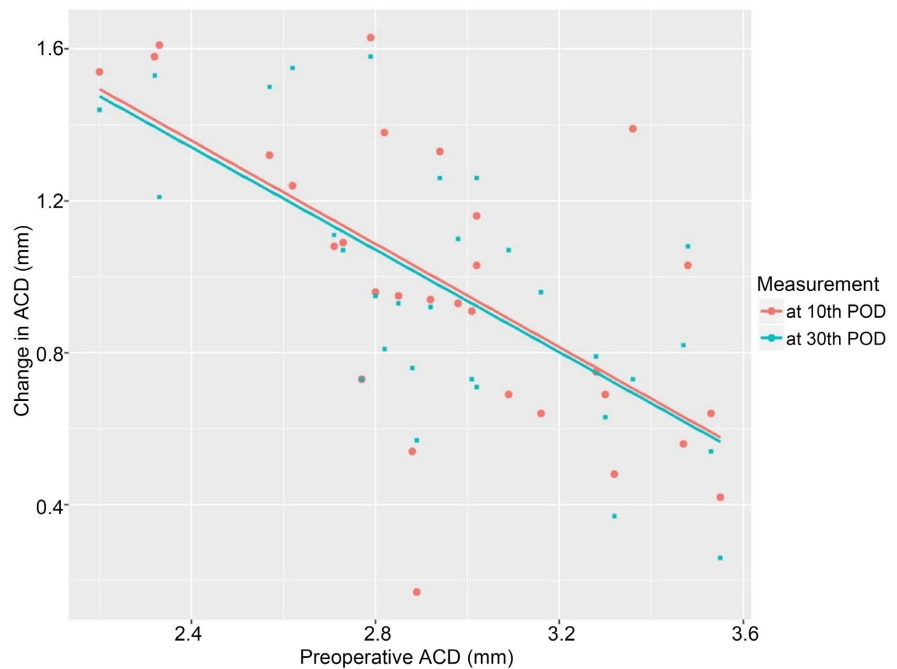


Figure 1. Change in anterior chamber depth (ACD) in relation to preoperative anterior chamber depth.

anterior chamber depth measured at 30th postoperative day. **Figure 2** shows that at 10th postoperative day those patients have narrow anterior chamber angle preoperatively were associated with more increase in anterior chamber depth postoperatively. But at 30th postoperative day change in anterior chamber depth at different preoperative average anterior chamber angle were equal.

So, our observation was change in anterior chamber depth after phacoemulsification surgery measured over 10th and 30th postoperative day were not dependent on preoperative average anterior chamber angle (**Figure 2**).

The box whisker plot of anterior chamber depth at 10th and 30th post-operative day versus gender shows that at 10th postoperative day median value of anterior chamber depth is more in case of male than female. But variation of change in anterior chamber depth occurs in male respondents, as the p-value was 0.320 which was less than 0.05 and not statistically significant. At 30th postoperative day median value of anterior chamber depth is more in case of female than male. But variation of anterior chamber depth occurs in female respondents, as the p-value was 0.634, which was less than 0.05 and not statistically significant (**Figure 3**).

The mean preoperative anterior chamber depth was 2.95 ± 0.35 mm and mean anterior chamber depth at 10th and 30th postoperative days were 3.94 ± 0.32 mm and 3.92 ± 0.28 mm respectively. While the mean of change in anterior chamber depth at 10th postoperative day of cataract surgery was 0.98 mm and at 30th postoperative day was 0.96 mm. Both of these provide evidence that after surgery the average central anterior chamber depth is expected to increase significantly as the p-values of the paired t-test of both time points are <0.05 (**Table 2**).

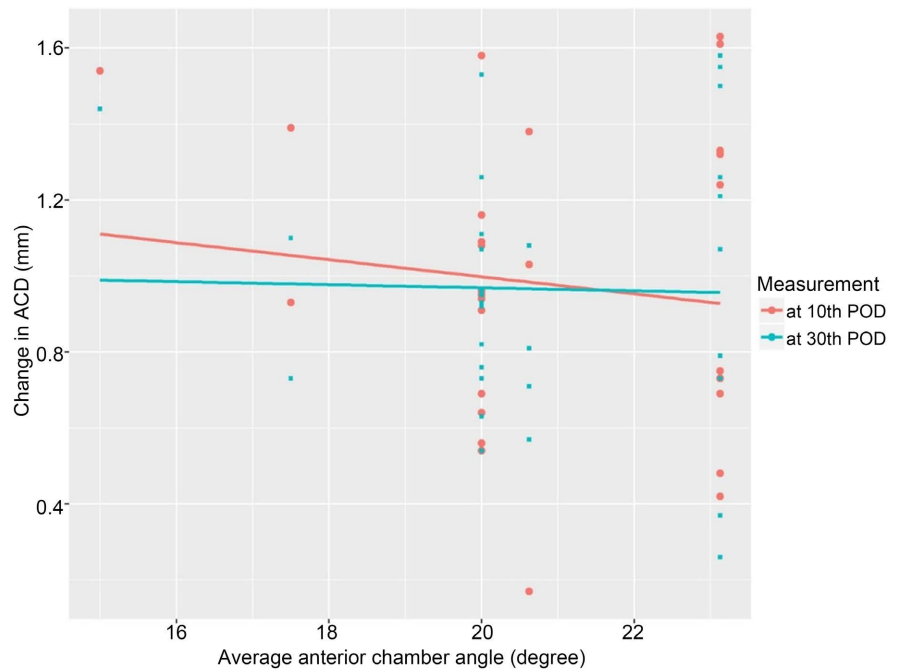


Figure 2. Relationship between average anterior chamber angle and change in anterior chamber depth (ACD).

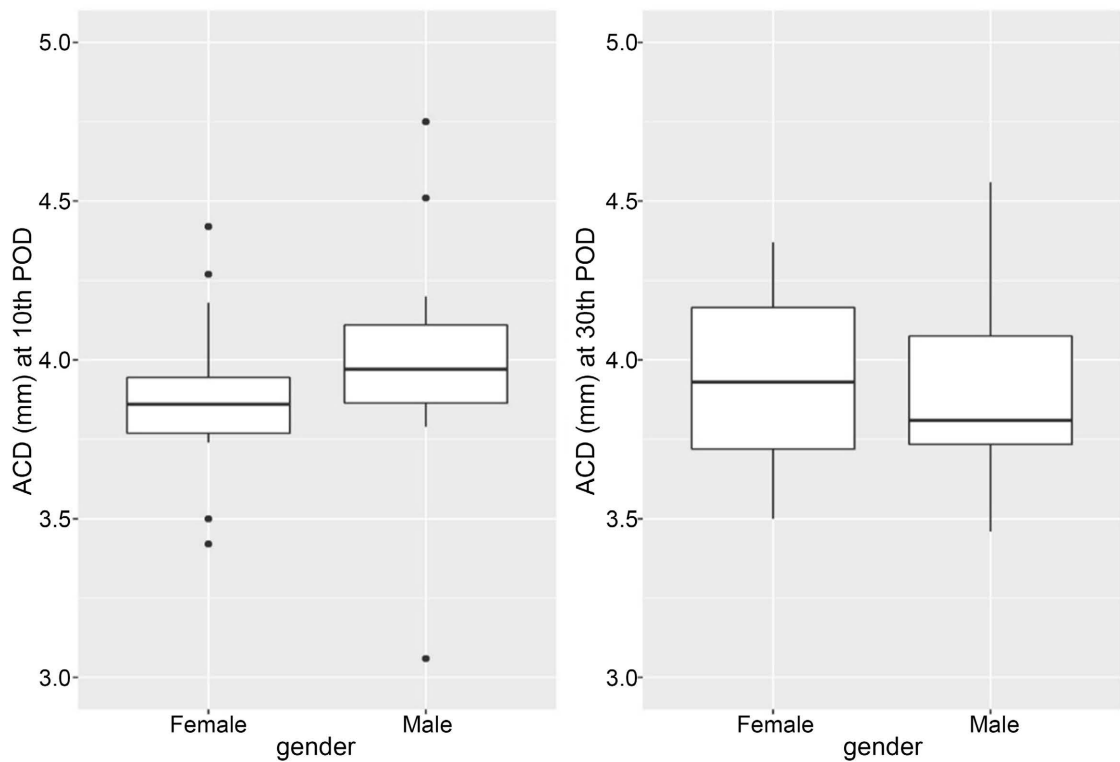


Figure 3. Anterior chamber depth (ACD) at 10th and 30th postoperative days versus gender.

The mean of changes in anterior chamber depth in between 10th and 30th postoperative day. **Table 3** shows that at 10th postoperative day mean anterior chamber depth was 3.94 mm, on an average they are dispersed as ± 0.32 mm. At

Table 2. Anterior chamber depth (ACD, mm) and changes in depth induced by cataract surgery.

Variable	Mean \pm SD	Mean of changes in ACD from preoperative (postop-preop)	p-value
Preoperative ACD	2.95 \pm 0.35	-	-
10 th Postoperative ACD	3.94 \pm 0.32	0.98	0.000
30 th Postoperative ACD	3.92 \pm 0.28	0.96	0.000

Table 3. Mean of changes in anterior chamber depth (ACD) in between 10th postoperative day and 30th postoperative day.

Variable	Mean \pm SD, mm	Mean of changes in ACD, mm from 10 th postoperative	p-value
10 th Postoperative ACD	3.94 \pm 0.32	-	-
30 th Postoperative ACD	3.92 \pm 0.28	0.015	0.750

30th postoperative day mean anterior chamber depth was 3.92 mm, on an average they are dispersed as ± 0.28 mm. Mean of changes in anterior chamber depth from 10th postoperative day were 0.015 mm. As the p-value is more than 0.05, which indicates that mean of changes in anterior chamber depth from 10th postoperative day is not statistically significant. So, our observation was mean of changes in anterior chamber depth achieved at 10th postoperative day, no further significant changes occur at 30th postoperative day (**Table 3**).

4. Discussion

In this prospective study we studied changes in anterior chamber depth after phacoemulsification with intraocular lens implantation in narrow angle eyes.

In our case series mean preoperative ACD were 2.95 \pm 0.35 mm, while the mean of change in ACD at 10th postoperative day of phacoemulsification surgery were 0.98 mm and at 30th postoperative day 0.96 mm, which is comparable to reports of Hayashi *et al.* 2000 [10] [11]. They showed that mean increase in ACD was 1.10 mm 8 weeks postoperatively. They found that after surgery the ACD in eyes with angle closure glaucoma (ACG) became almost identical to those in the non-glaucomatous eyes, indicating that cataract extraction may negate the anatomical predisposition to ACG.

Huang *et al.* (2011) reported that before surgery the mean (SD) ACD was 2.23 (0.07) mm in the NA group and mean ACD deepening induced by phacoemulsification surgery was 1.52 (0.04) mm in the NA group [13]. Six months after surgery, the mean (SD) postoperative ACD was 3.75 (0.05) mm in the narrow angle group.

Shin *et al.* (2011) showed that mean preoperative ACD in the occludable angle group was 2.75 mm, four weeks postoperatively change in ACD from preoperative was +1.23 mm, twelve weeks postoperatively ACD was +1.24 mm which is similar to our study [16] [17].

The possible explanation for ACD increase is as follows: The intraocular lens (IOL) is much thinner than the physiological lens, specially than the aged cataractous lens which is much thicker and steeper [19]. The posteriorly angled haptics are believed to push the IOL backward. The IOL is pushed posteriorly by the haptics with shrinkage of the lens capsule.

Gunning and Greve (1998) advocated cataract extraction for ACG as they found that it resulted in IOP reduction to the same extent as did filtering surgery, with fewer complications [20] [21].

In our study at 10th postoperative day those patients have shallower anterior chamber depth preoperatively are associated with more increase in anterior chamber depth postoperatively. At 30th postoperative day our observation was lower value of anterior chamber depth preoperatively associated with more increase in anterior chamber depth postoperatively. Similarly, Issa *et al.* (2005) reported inverse relation between preoperative ACD and the extent of ACD increase ($r = -0.8215$, $p\text{-value} < 0.01$) [18].

In our study at 10th postoperative day those patients have narrow average anterior chamber angle preoperatively are associated with more increase in ACD. At 30th postoperative day our observation was similar ACD as 10th postoperative day. No variation noted according to angle degree, which is comparable to Kurimato and coauthors (1997) [22]. They found that postoperative deepening was more prevalent in eyes with crowded anterior segments. In our study at final follow up visit ACD change was stable it may be due to postoperative stabilization of ocular condition.

Primary angle closure has been reported 2 to 4 times more commonly in women than in men, irrespective of race. In studies assessing ocular biometry, women tend to have smaller anterior segments and axial lengths than do men. This difference does not appear to be large enough to explain this sexual predilection [23]. In our study average anterior chamber angle was narrow in case of male gender. This may be due to advance age of male respondents in our study, which is associated with increased lens thickness and anterior segment crowding.

We have found that in our study 50% of patients age > 60.50 years. The mean age of the respondents was 62.03 ± 8.95 years. 50% were male and 50% were female, similar findings was observed by Moghimi *et al.* (2015) in Iran [24]. Who studied 85 patients with an overall mean age of 62.2 ± 8.9 years, 35 were male and 50 were female. The mean age of the sample was equal to us but male female percentage was different.

In our study gender wise change in ACD and IOP after phacoemulsification surgery were not statistically significant. Similarly, Issa *et al.* (2005) also reported that sex was not significantly related to ACD or IOP change [18].

The results of the current study reveal that a simple phacoemulsification cataract surgery with narrow angle may significantly increase the ACD and thus lower IOP. Following successful phacoemulsification surgery with in bag implantation of the IOL results in a reduced lens thickness and significantly changes the ACD.

5. Conclusion

Phacoemulsification with posterior chamber intraocular lens implantation can deepen the anterior chamber depth in patients with narrow angles. Based on these findings, it is concluded that phacoemulsification with foldable intraocular lens implantation is an effective tool in deepening the anterior chamber.

Conflicts of Interest

The authors declare no conflicts of interest regarding the publication of this paper.

References

- [1] Pascolini, D. and Mariotti, A. (2012) Global Estimates of Visual Impairment. *British Journal of Ophthalmology*, **96**, 614-618. <https://doi.org/10.1136/bjophthalmol-2011-300539>
- [2] Quigley, H.A. and Broman, A.T. (2006) The Number of People with Glaucoma Worldwide in 2010 and 2020. *British Journal of Ophthalmology*, **90**, 262-267. <https://doi.org/10.1136/bjo.2005.081224>
- [3] Quigley, H.A. (1996) Number of People with Glaucoma Worldwide. *British Journal of Ophthalmology*, **80**, 389-393. <https://doi.org/10.1136/bjo.80.5.389>
- [4] Quigley, H.A., Friedman, D.S. and Congdon, N.G. (2003) Possible Mechanisms of Primary Angle-Closure and Malignant Glaucoma. *Journal of Glaucoma*, **12**, 167-180. <https://doi.org/10.1097/00061198-200304000-00013>
- [5] Asbell, P.A., Dualan, I., Mindel, J., Brocks, D., Ahmad, M. and Epstein, S. (2005) Age-Related Cataract. *The Lancet*, **365**, 599-609. [https://doi.org/10.1016/S0140-6736\(05\)70803-5](https://doi.org/10.1016/S0140-6736(05)70803-5)
- [6] Nomura, H., Shimokata, H. ando, F., Miyake, Y. and Kuzuya, F. (1999) Age-Related Changes in Intraocular Pressure in a Large Japanese Population: A Cross-Sectional and Longitudinal Study. *Ophthalmology*, **106**, 2016-2022. [https://doi.org/10.1016/S0161-6420\(99\)90417-7](https://doi.org/10.1016/S0161-6420(99)90417-7)
- [7] Ge, J., Guo, Y. and Liu, Y. (2001) Preliminary Clinical Study on the Management of Angle-Closure Glaucoma by Phacoemulsification with Foldable Posterior Chamber Intraocular Lens Implantation. *Chinese Journal of Ophthalmology*, **37**, 355-358.
- [8] Foster, P.J. and Johnson, G.J. (2001) Glaucoma in China: How Big Is the Problem? *British Journal of Ophthalmology*, **85**, 1277-1282. <https://doi.org/10.1136/bjo.85.11.1277>
- [9] Foster, P.J., Buhrmann, R., Quigley, H.A. and Johnson, G.J. (2002) The Definition and Classification of Glaucoma in Prevalence Surveys. *British Journal of Ophthalmology*, **86**, 238-242. <https://doi.org/10.1136/bjo.86.2.238>
- [10] Hayashi, K., Hayashi, H., Nakao, F. and Hayashi, F. (2000) Changes in Anterior Chamber Angle Width and Depth after Intraocular Lens Implantation in Eyes with Glaucoma. *Ophthalmology*, **107**, 698-703. [https://doi.org/10.1016/S0161-6420\(00\)00007-5](https://doi.org/10.1016/S0161-6420(00)00007-5)
- [11] Hayashi, K., Hayashi, H., Nakao, F. and Hayashi, F. (2001) Effect of Cataract Surgery on Intraocular Pressure Control in Glaucoma Patients. *Journal of Cataract & Refractive Surgery*, **27**, 1779-1786. [https://doi.org/10.1016/S0886-3350\(01\)01036-7](https://doi.org/10.1016/S0886-3350(01)01036-7)
- [12] Shrivastava, A. and Singh, K. (2010) The Effect of Cataract Extraction on Intraocular Pressure. *Current Opinion in Ophthalmology*, **21**, 118-122.

- <https://doi.org/10.1097/ICU.0b013e3283360ac3>
- [13] Huang, G., Gonzalez, E., Peng, P.H., Lee, R., Leeungurasatien, T., He, M., Porco, T. and Lin, S.C. (2011) Anterior Chamber Depth, Iridocorneal Angle Width, and Intraocular Pressure Changes after Phacoemulsification: Narrow vs Open Iridocorneal Angles. *Archives of Ophthalmology*, **129**, 1283-1290. <https://doi.org/10.1001/archophthalmol.2011.272>
- [14] Poley, B.J., Lindstrom, R.L. and Samuelson, T.W. (2008) Long-Term Effects of Phacoemulsification with Intraocular Lens Implantation in Normotensive and Ocular Hypertensive Eyes. *Journal of Cataract & Refractive Surgery*, **34**, 735-742. <https://doi.org/10.1016/j.jcrs.2007.12.045>
- [15] Poley, B.J., Lindstrom, R.L., Samuelson, T.W. and Schulze Jr., R. (2009) Intraocular Pressure Reduction after Phacoemulsification with Intraocular Lens Implantation in Glaucomatous and Nonglaucomatous Eyes: Evaluation of a Causal Relationship between the Natural Lens and Open-Angle Glaucoma. *Journal of Cataract & Refractive Surgery*, **35**, 1946-1955. <https://doi.org/10.1016/j.jcrs.2009.05.061>
- [16] Shin, D.H., Vandenbelt, S.M., Kim, P.H., Gross, J.P., Keole, N.S., Lee, S.H., Birt, C.M. and Reed, S.Y. (2002) Comparison of Long-Term Incidence of Posterior Capsular Opacification between Phacoemulsification and Phacotrabeculectomy. *American Journal of Ophthalmology*, **133**, 40-47. [https://doi.org/10.1016/S0002-9394\(01\)01285-5](https://doi.org/10.1016/S0002-9394(01)01285-5)
- [17] Shin, H.C., Subrayan, V. and Tajunisah, I. (2010) Changes in Anterior Chamber Depth and Intraocular Pressure after Phacoemulsification in Eyes with Occludable Angles. *Journal of Cataract & Refractive Surgery*, **36**, 1289-1295. <https://doi.org/10.1016/j.jcrs.2010.02.024>
- [18] Issa, S.A., Pacheco, J., Mahmood, U., Nolan, J. and Beatty, S. (2005) A Novel Index for Predicting Intraocular Pressure Reduction Following Cataract Surgery. *British Journal of Ophthalmology*, **89**, 543-546. <https://doi.org/10.1136/bjo.2004.047662>
- [19] Steuhl, K.P., Marahrens, P., Frohn, C. and Frohn, A. (1992) Intraocular Pressure and Anterior Chamber Depth before and after Extracapsular Cataract Extraction with Posterior Chamber Lens Implantation. *Ophthalmic Surgery, Lasers and Imaging Retina*, **23**, 233-237. <https://doi.org/10.3928/1542-8877-19920401-04>
- [20] Gunning, F.P. and Greve, E.L. (1991) Uncontrolled Primary Angle Closure Glaucoma: Results of Early Intercapsular Cataract Extraction and Posterior Chamber Lens Implantation. *International Ophthalmology*, **15**, 237-247. <https://doi.org/10.1007/BF00171026>
- [21] Gunning, F.P. and Greve, E.L. (1998) Lens Extraction for Uncontrolled Angle-Closure Glaucoma: Long-Term Follow-Up. *Journal of Cataract & Refractive Surgery*, **24**, 1347-1356. [https://doi.org/10.1016/S0886-3350\(98\)80227-7](https://doi.org/10.1016/S0886-3350(98)80227-7)
- [22] Kurimoto, Y., Park, M., Sakaue, H. and Kondo, T. (1997) Changes in the Anterior Chamber Configuration after Small-Incision Cataract Surgery with Posterior Chamber Intraocular Lens Implantation. *American Journal of Ophthalmology*, **124**, 775-780. [https://doi.org/10.1016/S0002-9394\(14\)71694-0](https://doi.org/10.1016/S0002-9394(14)71694-0)
- [23] Aihara, M., Caprioli, J., Crandall, A., Ge, J., Kim, D., Lerner, F., Lewis, R., Manni, G., Medeiros, F., Nordmann, J. and Rojana Pongpun, P. (2005) Combined Cataract/Trabeculectomy. *Glaucoma Surgery: Open Angle Glaucoma*, **2**, 65.
- [24] Moghimi, S., Abdi, F., Latifi, G., Fakhraie, G., Ramezani, F., He, M. and Lin, S.C. (2015) Lens Parameters as Predictors of Intraocular Pressure Changes after Phacoemulsification. *Eye*, **29**, 1469-1476. <https://doi.org/10.1038/eye.2015.141>