

Surgical Treatment of Cervical Spine Trauma in Rural Area (Low Income Country): Our Experience and Results

Daouda Wague¹, Mouhamet Cisse², Gaye Maguette³, Ansoumane Donzo⁴, Yakhiya Cisse⁵, Mouhamet Faye⁶, Maguette Mbaye⁷, Mbaye Thioub⁷

¹Neurosurgery at CHMFT, Diourbel, Senegal

²Neurosurgery at Fann, Dakar, Senegal

³Neurosurgery at HOGIP, Dakar, Senegal

⁴Neurosurgery at Fann, Dakar, Senegal

⁵Neurosurgery at CHR, Thies, Senegal

⁶Neurosurgery at HOGIP, Dakar, Senegal

⁷Neurosurgery at UCAD, Dakar, Senegal

Email: wagued@yahoo.fr, mohabcisse@gmail.com, magou762003@yahoo.fr, donzoansoumane0@gmail.com, yakhyacisse@hotmail.com, fayeneurochir92@gmail.com, maguya83@yahoo.fr, thioubmbaye@gmail.com

How to cite this paper: Wague, D., Cisse, M., Maguette, G., Donzo, A., Cisse, Y., Faye, M., Mbaye, M. and Thioub, M. (2022) Surgical Treatment of Cervical Spine Trauma in Rural Area (Low Income Country): Our Experience and Results. *Open Journal of Orthopedics*, 12, 195-203.

<https://doi.org/10.4236/ojo.2022.124018>

Received: March 17, 2022

Accepted: April 19, 2022

Published: April 22, 2022

Copyright © 2022 by author(s) and Scientific Research Publishing Inc. This work is licensed under the Creative Commons Attribution International License (CC BY 4.0).

<http://creativecommons.org/licenses/by/4.0/>



Open Access

Abstract

Introduction: cervical spine trauma remains one of the most common causes of morbidity in the world with a significant financial burden on our society. It is a devastating event for the patient and family. The aim of this study is to share our experience in the surgery management of cervical spine injury in rural area. **Methods:** We did retrospective and single center study for one year from August 2020 to August 2021. We included all the patients who had undergone surgery for cervical spine injury in our hospital. **Results:** The study is based on 14 patients, 9 males and 5 females (sex ratio: 1.8). The average age was 34 years old and 08 (57%) were employed at time of injury. Road traffic accident was the most common cause, it was found in 11 (78%) cases followed by falls in 2 (14%) and interpersonal assault in 1 (7%). The Time admission ranged from 03 hours to 03 weeks. The most associated lesion was head trauma 7 (50%) followed by chest injury in 05 (35%) and 92% of our patient had motor deficit. Surgery was performed in all cases. Closed reduction was performed in 09 (64%) before surgery. Different types of complications that we had encountered were: infection 01 (07%) case, bed sores 02 (14%) cases, respiratory distress 02 (14%) cases and cervical kyphosis 01 (07%) case. After 06 months 71% of patients have progressed well with partial or complete recovery of their deficit. 14% of death in our series were noted and 28% of patients returned to work. **Conclusion:** cervical spine trauma remains a heavy

socio-professional handicap. In rural areas, despite the lack of equipment and the difficulties of care, our results are satisfactory. However, it is necessary to insist on psychotherapy for these patients.

Keywords

Cervical, Spine, Morbidity, Trauma, Surgery

1. Introduction

Cervical spine trauma remains one of the most common causes of morbidity in the world with a significant financial burden on our society. It is a devastating event for the patient and family. It has a huge impact on society because of the intensive resources required to manage the patient in both the acute and rehabilitation phases [1] [2]. Attempts to minimize the damage to the cervical spinal cord can result in very important improvements in the quality of life for these devastating injuries. Therefore, the goal of any surgeon is to appropriately identify those injuries that would benefit from surgical stabilization and decompression. In our rural society cervical spine trauma is common due to the urbanization of cities but also indiscipline in driving. The particularity in our city remains the cost of care which is expensive for the people, the accessibility to care which is still difficult for some and also the lack of equipment we encounter in our structure for rapid surgical care.

The aim of this study is to share our experience in the surgery management of cervical injury in rural area.

2. Methodology

We did retrospective and single center study in one year from August 2020 to August 2021. Patients who underwent surgery for cervical spine injury at matlaboufawzaini hospital in Touba city were enrolled. The American Spinal Injury Association Impairment Scale was used to assess for paralysis. 14 patients were enrolled and analysis was done using Microsoft office excel 2016. We studied their epidemiological, clinical, radiological, therapeutic and follow up data.

3. Surgical Method

After general anesthesia and neck collar removing, closed reduction is done in case of indication. Intraoperative fluoroscopy X-ray is used to follow reduction process. A standard Smith-Robinson anterior approach was used to perform anterior decompression. Discectomy or corpectomy was done then iliac bone graft or pyramesh cage were used for fusion. Cervical plate one level or two level with screw was used close was done after good hemostasis (**Figure 1**).

For patient who closed reduction was failed like unilateral facet dislocation, combined approach was performed. The patient was turned in prone position

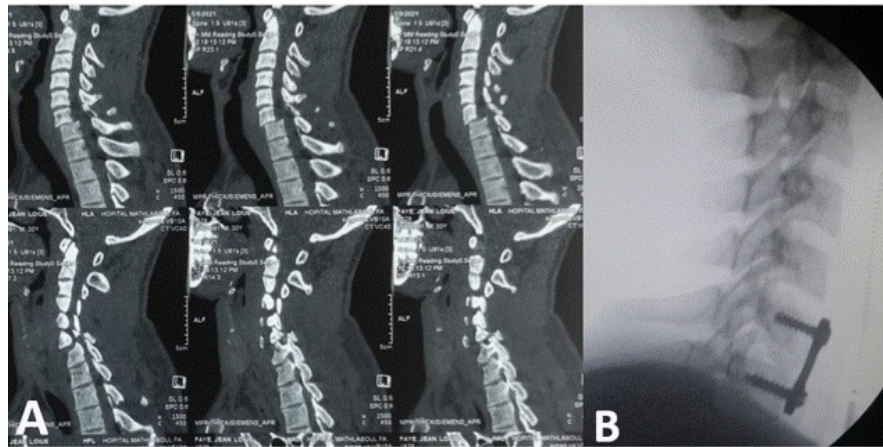


Figure 1. (A): C6C7 bifacet dislocation. (B): Fluoroscopy control show C6C7 plating with iliac bone graft after good close reduction.

with skull traction, posterior approach was performed to dislocate unilateral facet joint, after good reduction was checked by fluoroscopy X-ray and anterior approach was done.

4. Results

The study is based on 14 patients: 9 males and 5 females (The sex ratio was: 1.8 in favor of male). The average age was 34 years old and 08 (57%) were employed at time of injury. Road traffic accident was the most common cause in our series; it was found in 11 (78%) cases followed by falls in 2 (14%) cases and interpersonal assault in 1 (7%) case. The time admission ranged from 03 hours to 03 weeks and the mean time for admission was 04 days. A multiple trauma was found in 09 (64%) cases and the most frequently associated lesion was head trauma 7 (50%) followed by chest injury in 05 (35%) and femur fracture in 03 (21%) cases. 92% of our patients had motor deficit and were classified as ASIA A (American Spinal Injury Association) in 4 (28%) patients, ASIA B in 6 (42%), ASIA C in 3 (21%), ASIA D in 0 and ASIA E in 1 patient (07%). Respiratory impairment was noted in 4 (28%) cases.

Cervical CT-scan (computerized tomography) was performed in all patients and the lower cervical spine was the most frequent site of injury, found in 92% with a predominance of C6-C7 level (35%). Different lesions were found and fracture dislocation was the most found in 11 (78%) (**Table 1**).

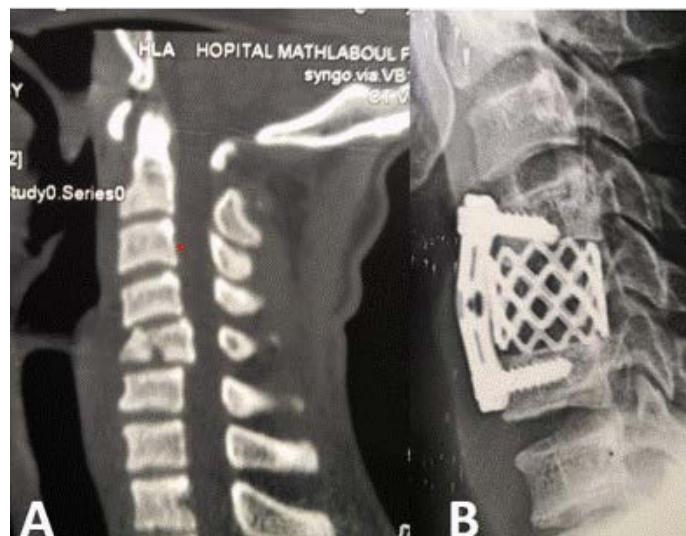Surgery was performed in all cases, the average time to surgery since trauma was 10, 28 days and 50% of cases, surgery was performed during the first week.

Closed reduction was performed in 09 (64%) before surgery.

Anterior approach was performed in all cases and combined approach (posterior and anterior approach) in one case. One level approach: discectomy with iliac bone graft and plating were performed in 09 (64%) cases, two level approach: corpectomy with iliac bone graft and cervical plate in 05 (35%) cases and corpectomy with pyramesh cage and plating in 01 (07%) (**Figure 2**).

Table 1. Level fracture and type of cervical injury in CT-scan.

Level fracture and type of cervical injury	Cases (%)
C6-C7 Fracture dislocation	05 (35%)
C5-C6 Fracture dislocation	02 (14%)
C4-C5 fracture dislocation	04 (28%)
C5 vertebral body fracture	02 (14%)
C2 vertebral body fracture	01 (07%)
Posterior elements fractures	11 (78%)
Unifacet dislocation	01 (07%)
Bifacet dislocation	05 (35%)

**Figure 2.** (A): Préop imaging: C5 body fracture. (B): Postop imaging: corporectomy + Plating with screw + Pyramesh cage.

Medical treatment was corticosteroids in 42%, analgesic and antibiotic prophylaxis in all case.

All patients underwent intraoperative X-ray fluoroscopy during surgery and cervical X-ray after surgery (**Figure 3**).

The 4 patients who had respiratory impairment received high dose injectable corticosteroids to stabilize them before surgery.

During follow up all patients with motor deficit underwent physiotherapy and psychotherapy.

Different types of complications that we had encountered in this series were: infection 01 (07%) case, bed sores 02 (14%) cases, respiratory distress 02 (14%) cases and cervical kyphosis 01 (07%) case.

After 06 months 71% of patients have progressed well with partial or complete recovery of their deficit. 14% of death in our series were noted and 28% of patients returned to work (**Table 2**).

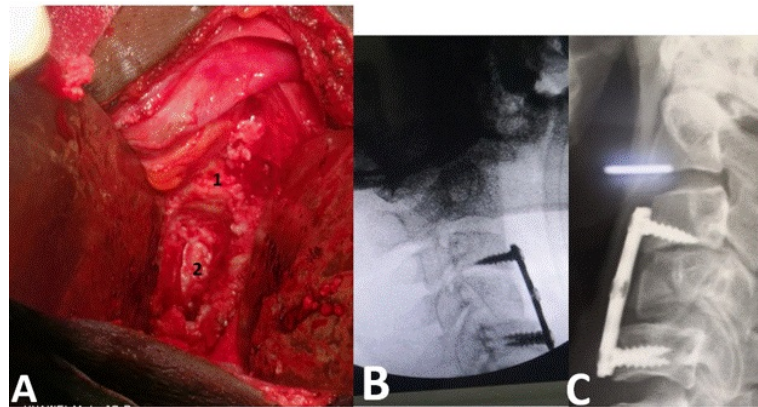


Figure 3. (A): Show intraoperative corpectomy/anterior approach: 1 C3 vertebral body, 2 cervical dura mater after decompression. (B): The same patient X-ray fluoroscopy control shows corpectomy with C3C5 plating. (C): X-ray after surgery show cervical plate C3C5 with iliac bone graft.

Table 2. Follow up for the motor deficit according to ASIA classification during the month.

ASIA	At the beginning: case (%)	01 month after: case	03 months case	06 months case
ASIA A	04 (28%)	A: 01 B: 01 C: 01 Death: 01	A: 01 C: 02	A: 01 C: 01 D: 01
ASIA B	06 (42%)	B: 02 C: 03 D: 01	B: 01 C: 01 D: 02 E: 02	B: 01 C: 01 E: 04
ASIA C	03 (21%)	D: 02 death: 01	E: 02	
ASIA E	01 (07%)	E: 01		

5. Discussion

SCI (Cervical Spinal Cord Injury) occurs predominately in young males, as shown in this study and substantiated by the literature [3] [4]. Fifty seven per cent were employed at the time of injury, which is a surprisingly high percentage given the referral population.

Road traffic accident was the most common causes in our series it was found in 11 (78%) cases due to non-compliance with the highway code in our city, the indiscipline of drivers while driving ,bad roads which are unlit at night and old bad cars which shouldn't be driven.

Time admission ranged from 03 hours to 03 weeks because some patients come from remotes areas and also there is no neurosurgeon in many regions of our country to take care of these patients. Given the nature of the injury (requiring prolonged stay and intensive care resources), coupled with the perception of poor

outcome, lack of surgeon and equipment, some hospitals will often not accept SCI patients. This results in the patients waiting in suboptimal conditions in primary-level hospitals until a bed becomes available in our hospital. The most common associated injury was head trauma. Studies have shown that 45% of severe head trauma is associated with cervical spine injury [5] [6] [7].

92% patients had neurologic deficit, in some case like assault or fall in our country, patients do not receive prehospital immobilization for cervical spine injury. They are in general transported to the hospital by parents or colleagues (responsible for secondary aggravation). In case of road traffic accident, people automatically call firefighters then prehospital immobilization with neck collar is done. However CSI can immediately be responsible for neurologic deficit due to cervical spinal cord compression.

Steroid treatment in the early hours after the injury is aimed at reducing the extent of permanent paralysis during the rest of the patient's life [8]. The use of MP (Methylprednisolone) remains a contentious issue, in part because of the catastrophic nature of ASCI and Although the results of NASCIS (National Acute Spinal Cord Injury Study) II and III trials led to the widespread adoption of a high-dose MP regimen for patients treated within 8 hours of injury, subsequent studies have called into question the validity of NASCIS conclusions [9]. In our hospital we use methylprednisolone at the dose of 2 to 5 mg/kg for 48 hours when the patients have complete motor impairment (ASIA A and B) but especially when there are respiratory disorders.

Patients with a preoperative neurological deficit due to spine trauma, in case of spinal cord compression or instability, surgery is often the treatment of choice to grant a chance of neurological recovery, early mobilization, and faster return to usual daily activities compared to the conservative treatment [10] [11]. In our series, 50% of patients were operated during the first week; the others patients beyond the first week up to a month. This delay is explained by unavailability of cervical spine implants in emergency (in our hospital) which purchased from the capital city, the lack of CT-scan in remote areas, financial problem for patients to buy cervical spine implant quickly which are expensive in our country, availability of beds in our hospital which are often full, diagnostics errors in some cases, socio-cultural beliefs (some patients after cervical spine trauma consult cultural healer before coming to hospital) and those who have respiratory impairment that requires stabilization with corticosteroids for a few days before having surgery.

The classic anterolateral approach was used for most of our patients. It is a simple approach, this choice depends on clinic and surgeon experience, it allows anterior column stabilisation and good anterior decompression. Many authors prefer the anterolateral approach with placement of an inter-somatic graft or cage combined with plating [12] [13].

In our series after 06 months 71% of patients have progressed well with partial or complete recovery of their deficit. 14% of death (02 cases) in our series were noted and 28% of patients returned to work.

The 02 cases of death, one was classified ASIA A with respiratories impairments stabilized slightly by corticosteroids but after surgery the patient still presented respiratory impairment, despite treatment in the intensive care unit the patient died. The other was a patient classified ASIA C with a traumatic brain injury, he presented an inhalation in intensive care in postoperative then he died of inhalation pneumonia. Previous studies have reported mortality of between 4% - 6%, 6% - 18% and other like Perter G et al in U.S reported 6.6% of mortality [14] [15] [16].

Different types of complications encountered: infection one case, cervical kyphosis one case and bed sores in two cases. In our region, anti-decubitus beds are expensive for most of patients and also there are no rehabilitation center as in developed countries, we insist on mobilization of the patient: in the hospital the patients are mobilized every 04 hours after the surgery, gloves filled with serum are placed under the patient's points of support (elbow, heel, etc.) for the prevention of bedsores, when they discharge from hospital, we advise family to insist on mobilization at home and also to start physiotherapy sessions. For some patients, physiotherapy remains expensive because there are many patients who live between 100 to 200 miles from the hospital in remote areas where there is no physiotherapy, they come to the hospital in difficult conditions to do one or two sessions per week.

28% of patients returned to work after 06 months of follow up, this percentage is low and still justify that spinal trauma remains a heavy socio-professional handicap and significant causes of morbidity, often these patients were responsible for their families. Some of them are depressed, that's why psychotherapy is always needed.

The limits of this study are: the low number of patients which is explained that we started neurosurgery in this hospital just a year ago. Patients who have means often go to the cities to get care. Some patients are transferred to other hospitals because we have a single surgery department for all surgical specialties and beds are often full like in emergency to receive spinal trauma. This study also shows that in rural areas we have to find the equipment which is available in our hospitals to operate early for the patients who are victims of cervical spine trauma.

6. Conclusion

Cervical spine trauma remains a heavy socio-professional handicap. In rural areas, despite the lack of equipment and the difficulties of care, our results are satisfactory. However, it is necessary to insist on psychotherapy for these patients.

Conflicts of Interest

The authors declare no conflicts of interest regarding the publication of this paper.

References

- [1] Melvin, D.H., Gendelberg, D. and Gursukhman, S.S., *et al.* (2012) Management of

- Cervical Spine Trauma: Can a Prognostic Classification of Injury Determine Clinical Outcomes? Department of Orthopaedic Surgery, Rothman Institute, Thomas Jefferson University and Hospitals, 925 Chestnut Street, Philadelphia, PA 19107, USA. *Orthopedic Clinics of North America*, **43**, 89-96.
<https://doi.org/10.1016/j.ocl.2011.08.005>
- [2] Frielingsdorf, K. and Dunn, R.N. (2007) Cervical Spine Injury Outcome—A Review of 101 Cases Treated in a Tertiary Referral Unit. *South African Medical Journal*, **97**, 203-207.
- [3] Frankel, H.I., Coli, J.R., Charlifue, S.W., et al. (1998) Long-Term Survival in Spinal Cord Injury: A Fifty Year Investigation. *Spinal Cord*, **36**, 266-274.
<https://doi.org/10.1038/sj.sc.3100638>
- [4] Vaccaro, A.R., Daugherty, R.J., Sheehan, T.P., et al. (1997) Neurologic Outcome of Early versus Late Surgery for Cervical Spinal Cord Injury. *Spine*, **22**, 2609-2613.
<https://doi.org/10.1097/00007632-199711150-00006>
- [5] Iida, H., Tachibana, S., Kitahara, T., Horiike, S., Ohwada, T. and Fujii, K. (1999) Association of Head Trauma with Cervical Spine Injury, Spinal Cord Injury or Both. *The Journal of Trauma and Acute Care Surgery*, **46**, 450-452.
<https://doi.org/10.1097/00005373-199903000-00018>
- [6] Feron, J.M., Gleyzes, V. and Signoret, F. (1997) Prévalence des associations lésionnelles dans les fractures du rachis cervical. *Rev Chir Orthop, Suppl. II* 83: 39.
- [7] Ouhmich, M.M. (2019) La prise en charge du traumatisme du rachis cervical. Thèse, Université Sidi Mohamed Ben Abdellah, 198 p.
- [8] Bracken, M.B. (2012) Steroids for Acute Spinal Cord Injury. *Cochrane Database of Systematic Reviews*, **1**, CD001046.
<https://doi.org/10.1002/14651858.CD001046.pub2>
- [9] Bydon, M., Lin, J., Macki, M., Ziya, L.G. and Bydon, A. (2013) The Current Role of Steroids in Acute Spinal Cord Injury. *World Neurosurgery*, **82**, 848-854.
<https://doi.org/10.1016/j.wneu.2013.02.062>
- [10] Cengiz, S.L., Kalkan, E., Bayir, A., Ilik, K. and Basefer, A. (2008) Timing of Thoracolumbar Spine Stabilization in Trauma Patients; Impact on Neurological Outcome and Clinical Course. A Real Prospective (rct) Randomized Controlled Study. *Archives of Orthopaedic and Trauma Surgery*, **128**, 959-966.
<https://doi.org/10.1007/s00402-007-0518-1>
- [11] Dobran, M., Iacoangeli, M. and Nocchi, N. (2015) Surgical Treatment of Cervical Spine Trauma: Our Experience and Results. *Asian Journal of Neurosurgery*, **10**, 207-211.
<https://doi.org/10.4103/1793-5482.161192>
- [12] Kpelao, E., Diop, A., Beketi, K., Tine, I., Thioub, M., Thiam, A.B., et al. (2013) Problématique de la prise en charge des traumatismes graves du rachis cervical en pays sous-développé. *EMC Neurochirurgie*, **59**, 111-114.
<https://doi.org/10.1016/j.neuchi.2013.04.008>
- [13] Shakya, B., Bista, P. and Shrestha, D. (2014) Instrumentation in Cervical Spine Injury: Neurological Outcome Measure Mentusing ASIA Impairment Scale. *Nepal Medical College Journal*, **16**, 156-160.
- [14] Fredø, H.L., Bakken, I.J., Lied, B., Rønning, P. and Helseth, E. (2014) Incidence of Traumatic Cervical Spine Fractures in the Norwegian Population: A National Registry Study. *Scandinavian Journal of Trauma, Resuscitation and Emergency Medicine*, **22**, 78. <https://doi.org/10.1186/s13049-014-0078-7>
- [15] Yadollahi, M., Paydar, S., Ghaem, H., Ghorbani, M., Mousavi, S.M., Taheri Akerdi, A., et al. (2016) Epidemiology of Cervical Spine Fractures. *Trauma Monthly*, **21**,

6-10. <https://doi.org/10.5812/traumamon.33608>

- [16] Passias, P.G., Poorman, G.W. and Segreto, F.A. (year) Traumatic Fractures of the Cervical Spine: Analysis of Changes in Incidence, Cause, Concurrent Injuries, and Complications among 488,262 Patients from 2005 to 2013. *World Neurosurgery*, **110**, e427-e437. <https://doi.org/10.1016/j.wneu.2017.11.011>

Abbreviations

ASIA: American Spinal Injury Association

CT-scan: Computerized Tomography

SCI: Cervical Spinal Cord Injury

MP: Methylprednisolone

NASCIS: National Acute Spinal Cord Injury Study