

Natural History of Symptomatic Meniscal Tears: Arthroscopic Evaluation of Chondral Damage at 4-Year Minimum

Andrés Pakuts, Luis Martin, Javier Contador

School of Medicine, Pontifical Catholic University of Chile, Santiago, Chile

Email: andrespakuts@gmail.com

How to cite this paper: Pakuts, A., Martin, L. and Contador, J. (2019) Natural History of Symptomatic Meniscal Tears: Arthroscopic Evaluation of Chondral Damage at 4-Year Minimum. *Open Journal of Orthopedics*, 9, 231-240.

<https://doi.org/10.4236/ojo.2019.911024>

Received: October 17, 2019

Accepted: November 22, 2019

Published: November 25, 2019

Copyright © 2019 by author(s) and Scientific Research Publishing Inc. This work is licensed under the Creative Commons Attribution International License (CC BY 4.0).

<http://creativecommons.org/licenses/by/4.0/>



Open Access

Abstract

Background: The natural history of meniscal tears is unclear. Studies have tried to clarify many aspects. Association with chondral injuries are of main relevance to the long-term status of the knee but evidence is limited. **Objective:** The aim of this study is to describe the intraarticular state of the knee focused on chondral injury in patients with persistent symptomatic meniscal tears that were untreated for a minimum period of 4 years. **Methods:** A total of 47 patients with symptomatic meniscal tears in whom surgery was indicated but was delayed mainly for administrative reasons, were recruited between January 1st, 2004 and April 30th, 2010 in a regional hospital. Follow up ended until circumstances allowed surgical resolution through arthroscopy. Only patients with meniscal tear in which diagnosis was confirmed and remained symptomatic were included. Patients with initial grade IV Kellgren-Lawrence osteoarthritis were excluded. Statistical chi-square and logistic regression analysis were used. **Results:** Mean follow up period was 5.8 years (range: 4.3 - 10.2 years). 57 meniscal injuries were found in 47 patients. 25 were lateral and 32 medial meniscal tears. Overall, 29 patients had articular cartilage damage (51%). Chondral injuries were found in 15 of 25 lateral meniscal lesions (60%) and 14 of 32 medial lesions (44%). Patients with lateral compartment meniscal injury had a relative risk (RR) of 2.5 of developing chondral injury (p-value < 0.01) and those with medial injury had a RR of 1.5 (p-value > 0.05). Compared to 51% of patients with associated chondral and meniscal damage (n = 29), only 12% of patients with healthy meniscus (n = 7) had chondral injury (p-value < 0.05). In patients with chondral injury (n = 29), 83% had femoral compromise and 66% had tibial injuries. 79% of chondral injuries were grade IV (ICRS grading scale). According to ISAKOS classification, 56% of patients with meniscal injury in zone 1 or 2, had chondral injury vs 22% of the ones with zone 3 compromise (inner zone) (p-value >

0.05). **Conclusion:** Persistent symptomatic meniscal tears after medium to long term (4 to 10 years) are associated with chondral damage in 51% of patients. Chondral damage associated with meniscal tears is usually deep and involves femur and tibial sides. Lateral menisci injury is significantly associated with articular cartilage damage in the ipsilateral compartment. This study demonstrates a significant association between meniscal injury and chondral damage.

Keywords

Natural History, Meniscal Tear, Chondral Injury

1. Introduction

Meniscal tears of the knee are high incidence injuries, with a rate between 1.1% and 1.4% in the general population [1] and a peak prevalence in middle age individuals as high as 22% [2]. The risk factors involved in the development of this kind of injuries are numerous. Demanding sports and knee instability, as it occurs in patients with anterior cruciate ligament injury, have been associated with meniscal tear development [3] [4]. Systematic reviews have found other factors involved such as age beyond 60 years, male gender and common activities like kneeling or climbing stairs [5].

Meniscal injuries can be acute or chronic degenerative tears. The first ones occur in association with rotation motion while the knee is flexed and the foot planted, that is why they are related to soccer, basketball, football and other sports with deceleration and changes in direction [6] [7] [8]. On the other side, degenerative tears occur in older patients with minimal or no trauma. Also, degenerative meniscal lesions are commonly revealed in MRI of asymptomatic middle age subjects [6].

Untreated meniscal tears have been associated with pain, reduced range of motion, articular effusion, functional limitations, articular surface and radiographic changes [9]-[14]. Patients who undergo partial meniscectomy have 20% more osteoarthritic changes compared to those who their meniscus is repaired [15]. Evidence regarding untreated meniscal injuries is sparse, nevertheless, the above denotes the relevance of this matter and the clear association between meniscal integrity and chondral damage or osteoarthritis progression [16] [17] [18].

There are few studies that investigate the natural course of this kind of injuries therefore the natural evolution remains unclear or unknown, specially related to its relationship with chondral damage [19] [20]. Chondral lesions associated with meniscal tears are related to poor outcomes and functional results [21] [22]. The aim of this study is to describe the intraarticular state of the knee specially focusing on chondral damage, in patients with symptomatic meniscal tears that remain symptomatic without receiving any treatment for a minimum period of 4

years after which an arthroscopic evaluation was performed to establish its possible association between chondral and meniscal damage.

2. Methods

The study was designed including patients with symptomatic meniscal tears that an arthroscopic treatment was indicated and for different reasons, mainly administrative, the surgery was postponed a minimum period of 48 months. After these minimum 4-year period they were re-evaluated and those who remained symptomatic were scheduled for an arthroscopic surgery. The diagnosis of meniscal tear was made clinically and confirmed in the majority of cases with X ray and magnetic resonance of the knee. Patients that initially presented osteoarthritis in a knee weight bearing X-ray (Rosemberg View: Grade 4 Kellgren & Lawrence), were not recruited. Sample size (at least 30) was decided in order to achieve normal distribution for the posterior statistical analysis. A total of 47 patients were included between January 1st, 2000 and June 30th, 2010 in a regional hospital. During these minimum 4-year period, all of them continued with normal daily activities, were laborly active and continued to be symptomatic. They were evaluated and an arthroscopic procedure was performed with special attention to meniscal and chondral status which was classified according to the ICRS [23]. A chondral injury grade II or more was considered significant. Statistical analysis was made according relative risk (RR), Chi-Squared and logistic regression with significance less than 5%. The confidence interval (CI) used is 95%. This study has the respective ethical requirements and authorization of the director of medical center in charge of the patients included.

3. Results

A total number of 57 meniscal injuries in the 47 patients were detected. Mean age of the sample was 50 years with a range between 29 and 71. Regarding gender, 29 patients were males (62%) and 18 were females (38%). The mean follow up period from surgical indication until arthroscopy was 5 years and 8 months with a range between 4.3 and 10.2 years. Within our cohort, there were 25 cases of lateral meniscus injury and 32 of the medial menisci, thus 10 patients had both menisci injured.

Tibiofemoral chondral injuries were detected in 29 compartments or cases (51%), and 28 cases had no macroscopic articular cartilage lesions (49%), **Figure 1**.

In the group of 25 lateral meniscus lesions, 15 cases (60%, CI: 38.6% - 78.8%) had concomitant chondral injury in that compartment and 10 cases (40%, CI: 21.1% - 61.3%) had no chondral damage, p-value 0.149. On the other hand, the group of 32 cases with medial meniscus injuries, 14 cases had chondral injury (44%, CI: 26.3% - 62.3%) and 18 cases had no chondral damage (56%, CI: 37.6% - 73.6%), p-value 0.313 (**Table 1**).

When comparing both compartments, we found that patients who initially had an injury of the lateral meniscus have a relative risk (RR) of 2.5 of developing

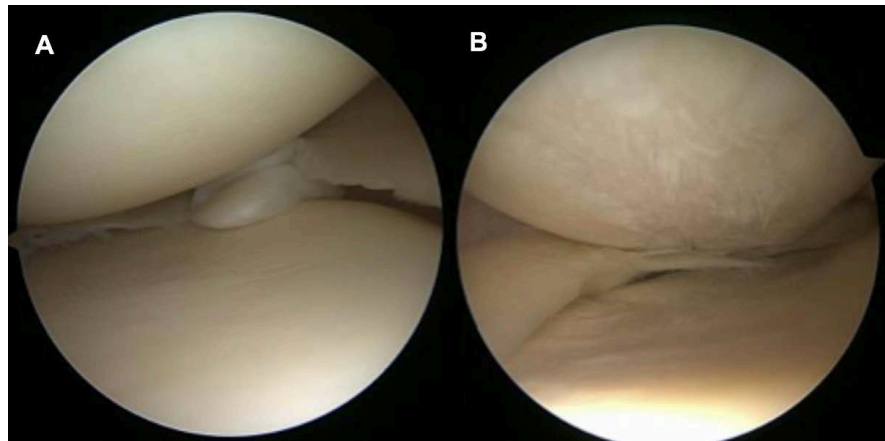


Figure 1. Arthroscopic view of the articular surface. (A): Healthy articular surface; (B): Chondral injury.

Table 1. Chondral injuries associated with meniscal injuries.

Compartment	Chondral Injury	Healthy Cartilage	p-Value
Lateral (n = 25)	15 (60%, CI: 38.6% - 78.8%)	10 (40%, CI: 21.1% - 61.3%)	0.149
Medial (n = 32)	14 (44%, CI: 26.3% - 62.3%)	18 (56%, CI: 37.6% - 73.6%)	0.313
Total: 57	29 (51%)	28 (49%)	-

a chondral injury (p-value < 0.01). Instead, patients with medial meniscus injury have a RR of 1.54 of developing the same kind of injury (p-value > 0.05). Our model concludes that a patient with lateral meniscus injury has 12.5 times more risk of developing a chondral injury at 4 year minimum (**Table 2**). The same model applied to explain chondral injury of the medial compartment was not significant.

If we look at the healthy compartment which is the one without meniscal damage, we found 7 cases of chondral injuries (12%, CI: 5% - 23.6%) compared to 29 cases (51%, CI: 37.2% - 64.3%) with meniscal and chondral lesions in the same compartment. The latter comparison was statistically significant (p-value < 0.05 RR 4.25).

Regarding the location of chondral lesions within the tibiofemoral compartments with injured meniscus (29 cases), 10 cases were only femoral (35%), 14 were femoral and tibial (45%), 5 cases only tibial (17%). There was no significant difference between compartments according to location (**Table 3**) (**Figure 2**).

According to ICRS classification, 1 case had grade II lesion, 5 cases grade III lesions (17%) and 23 cases presented grade IV lesions (79%). There was no significant difference between compartments (**Table 4**).

Finally, the location of the injury in the meniscus according to its vascularization or corresponding ISAKOS classification [24] and its association with chondral injury is showed in **Table 5**. All meniscal injuries in red-red zone presented chondral damage (100%). Furthermore, 56% (27 over 48, CI 41.1% - 70.5%) of patients with compromised red zone have chondral injury versus 22% of chondral

Table 2. Logistic regression model of chondral damage in the lateral compartment.

Variable	DF	Adj. Dev.	Adj. Mean	Chi-Square	Probability Relation	IC 95%	p-Value
Regression*	3	17.3	5.7	17.3	-	-	<0.001
Age	1	0.008	0.008	0.01	1.06	(0.987; 1.146)	0.9286
Lateral Meniscus Injury	1	15.5	15.5	15.6	12.51	(1.925; 81.343)	<0.001
Medial Meniscus Injury	1	1.7	1.7	1.7	0.28	(0.041; 1.978)	0.1898
Error	41	43.9	1.07	-	-	-	-
Total	44	61.2	-	-	-	-	-
Goodness of fit	-	-	-	-	-	-	0.487**

DF: degrees of freedom; Adj: Adjusted; Dev: Deviation. *R² of the model is 28.24%, it's deviance is 23.55% and AIC: 51.98. **Hosmer-Lemeshow test.

Table 3. Frequency of chondral lesions according to their location and injured meniscus.

Meniscal Injury	Femoral Injury	Tibial Injury	p-Value
Lateral (n = 15)	12	10	-
Medial (n = 14)	12	9	-
Total: 29	24 (83%, CI: 64.2% - 94.1%)	19 (66%, CI: 45.6% - 82%)	0.126

Table 4. Chondral injury according to ICRS grade and meniscal compartment.

ICRS	Medial Compartment	Lateral Compartment	Total	p-Value
Grade II	0	1 (6.6%, CI: 0.1% - 31.9%)	1 (3.4%, CI: 0.08% - 17.7%)	0.301
Grade III	2 (14.3%, CI: 1.7% - 42.8%)	3 (20%, CI: 4.3% - 48%)	5 (17.3%, CI 5.8% - 35.7%)	0.682
Grade IV	12 (85.7%, CI: 57.1% - 98.2%)	11 (73.3%, CI: 44.8% - 92.2%)	23 (79.3%, CI 60.2% - 92%)	0.402
Total	14 (48.3%, CI: 29.4% - 67.4%)	15 (51.7%, CI: 32.5% - 70.5%)	29 (100%)	0.793

Table 5. Frequency of meniscal injury and chondral injury according to tear location site.

Tear Location	Healthy Cartilage	Chondral Injury	Total	p-Value
ISAKOS zone 3 (White-White)	7	2 (22%, CI: 2.8% - 60%)	9	0.079*
ISAKOS zone 2 (White-Red)	21	23 (52%, CI: 36.6% - 67.5%)	44	-
ISAKOS zone 1 (Red-Red)	0	4 (100%)	4	-
Total	28	29	57	-

*Comparison between only white zone compromise vs any red zone compromise (ISAKOS 1 + 2).

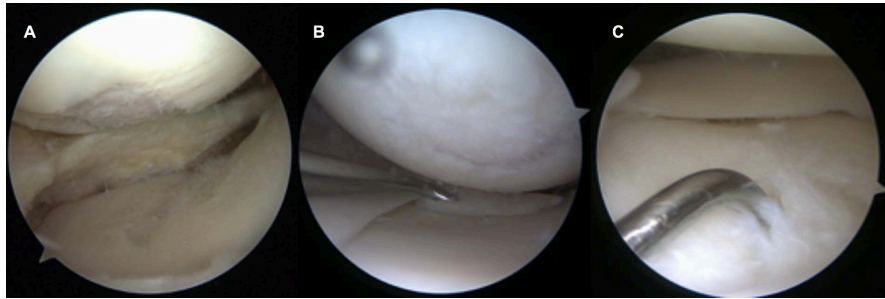


Figure 2. Arthroscopic view of chondral injuries according to their location. (A) Femoral & Tibial; (B) Femoral only; (C) Tibial only.

injury in the group with just white zone compromise (2 over 9, CI: 2.8% - 60%), p-value 0.079.

4. Discussion

The meniscal integrity is important for the articular function of the knee. They give shock absorption, load distribution, joint stability, lubrication and proprioception. Meniscal tears may play an important role in the genesis of chondral injury and osteoarthritis (OA) of the knee [25].

In the literature there are few studies of natural history of meniscus tears in spite of its high incidence. The few studies suggest that meniscus tears are associated with a greater incidence in chondral injury and OA but there are many confounding variables not controlled in these short-term studies [26]. After a literature review in different medical databases we didn't find any study regarding the natural history nor evolution of untreated symptomatic meniscal tears. Concordantly, Monk, in his systematic review, didn't find any study comparing nonoperative management in the treatment of meniscal injuries [27]. The above denotes the lack of evidence regarding this matter.

Despite treatment more than 40% of individuals with acute tears of ligaments/meniscus or injuries at articular surfaces develop OA of the knee [28]. According to Maffulli, long-term studies of meniscectomized knees show that almost every knee sustains arthritic changes through time, suggesting the relevance of meniscal integrity in the normal function of the knee [29]. Jorgensen in his prospective cohort of 147 meniscectomized patients found 89% of radiographic changes at 14.5 years versus 40% at 4.5 years, denoting the progressive evolution of articular surface damage [12]. Boszotta in his cohort of 31 patients found that 40% of patients developed early signs of OA after 7 years of partial meniscectomy [13]. Meniscal tears are associated with greater pain, stiffness, effusion, functional limitations and articular surface changes, concordantly with the findings in our study [9]-[14].

At this point we can't deny meniscal tear as a risk factor in the development of OA as we demonstrate in the present study that a lateral meniscus injury increases 12.5-fold the chance of developing chondral injury after at least 4 years of follow up. Meniscal tears appear to be one of the very first events in the de-

velopment of OA in injured patients and there is an association between this kind of injuries and cartilage defects and alterations in bone structures [9] [30]. McNicholas *et al.*, in a prospective study of 53 patients with a long-term follow up of 30 years that compared total meniscectomy with non-operative management, found that total meniscectomized patients had 3 times more joint narrowing and osteophytes at the 30-year review with plain x-ray [31].

The treatment of meniscal tears isn't completely resolved, although is mainly in favor of the preservation of menisci [32] [33] [34]. Melrose's revision shows that surgical removal (partial or complete) of injured menisci has been associated with increased premature onset of OA [25]. Concordantly, complete surgical removal has a RR of OA of 14 after 21 years according to Roos [14]. Moreover 80% of patients with repaired meniscus have less radiographic progression of OA [33].

All the above findings support the relationship between meniscectomy and cartilage lesions but there is no clear evidence in the literature between a non-treated symptomatic meniscal injury and chondral lesions. There are different reasons for a lack of such studies and probably ethical motive is relevant. In many countries public health care system does not resolve adequately, especially in timing, pathologies like symptomatic meniscal tears and in some cases, it can be shamefully for years. We decided to look at this group of patients in a middle term follow up of minimum 4 years with a special focus in articular cartilage status.

As we discussed, a treated meniscal injury by meniscectomy is related to further chondral lesions, so we expected to find same results in a symptomatic meniscal tear that continued to be with symptoms after at least 4 years. Our study supports this relationship, especially in the lateral compartment where there was stronger significance. It must be noted that still, there is a group of almost half of the patients (49%) that did not develop any macroscopic chondral damage despite remaining laborly active and many of them sports participative. We did not find protective factors related to this group.

If we look at the location of chondral damage related to ipsilateral meniscal tear, we found that almost half of the patients (45%) had tibial and femoral lesions and in the ones with one-sided damage femoral injuries, were twice as frequent than tibial injuries (35% vs 17%). A fact that we could not explain or compare with other studies. Nor the fact that patients that presented with concomitant chondral and meniscal damage had a significant higher rate of deep cartilage compromise (79% with grade IV ICRS injuries).

We are far from establishing the natural history of meniscal tears, our study presents some pitfalls. Patients initially proposed for meniscal surgery could have evolved asymptomatic without treatment or being treated conservatively during the follow up. We could not determine the evolution in the chondral damage in this minimum 4-year period as we don't certainly know the initial chondral status through arthroscopic view. We have MRI initial status and arthroscopic final status that are not accurately comparable.

Despite these facts, this study is the first report of this kind in the literature that we know, to accurately determine the chondral status of the knee by direct arthroscopic evaluation in patients with prolonged symptoms related to meniscal tears.

5. Conclusions

According to our findings, symptomatic meniscal tears after medium-long term (4 to 10 years) are associated with chondral injury in 51% of patients. Almost half of patients can remain without any chondral damage.

We found a significant association between meniscal tear and chondral injury. Chondral damage associated with meniscal tears is usually deep (79% grade IV) and involves femur in 83% and tibia in 66%, with 45% both sided. Lateral menisci injury is significantly associated with articular cartilage damage in the ipsilateral compartment.

Acknowledgements

Andrés Pakuts is specialist in orthopedic surgery by the Pontifical Catholic University of Chile. Luis Martin & Javier Contador are currently undergraduates in the same institution.

Conflicts of Interest

We declare no conflict of interests.

References

- [1] Nielsen, A.B. and Yde, J. (1991) Epidemiology of Acute Knee Injuries: A Prospective Hospital Investigation. *The Journal of Trauma: Injury, Infection, and Critical Care*, **31**, 1644-1648. <https://doi.org/10.1097/00005373-199112000-00014>
- [2] Khan, H.I., Aitken, D., Ding, C., Blizzard, L., Pelletier, J., *et al.* (2016) Natural History and Clinical Significance of Meniscal Tears over 8 Years in a Midlife Cohort. *BMC Musculoskeletal Disorders*, **17**, 4. <https://doi.org/10.1186/s12891-015-0862-1>
- [3] Majewski, M., Stoll, R., Widmer, H., Müller, W. and Friederich, N.F. (2006) Mid-term and Long-Term Results after Arthroscopic Suture Repair of Isolated, Longitudinal, Vertical Meniscal Tears in Stable Knees. *The American Journal of Sports Medicine*, **34**, 1072-1076. <https://doi.org/10.1177/0363546505284236>
- [4] Michalitsis, S., Vlychou, M., Malizos, K.N., Thriskos, P. and Hantes, M.E. (2013) Meniscal and Articular Cartilage Lesions in the Anterior Cruciate Ligament-Deficient Knee: Correlation between Time from Injury and Knee Scores. *Knee Surgery, Sports Traumatology, Arthroscopy*, **23**, 232-239. <https://doi.org/10.1007/s00167-013-2497-9>
- [5] Snoeker, B.A., Bakker, E.W., Kegel, C.A. and Lucas, C. (2013) Risk Factors for Meniscal Tears: A Systematic Review Including Meta-Analysis. *Journal of Orthopaedic & Sports Physical Therapy*, **43**, 352-367. <https://doi.org/10.2519/jospt.2013.4295>
- [6] Cardone, D. and Jacobs, B. (2019) Meniscal Injury of the Knee. UpToDate Inc., Waltham, MA. <https://www.uptodate.com>
- [7] Smith, B.W. and Green, G.A. (1995) Acute Knee Injuries: Part I. History and Phys-

- ical Examination. *American Family Physician*, **51**, 615-621.
- [8] Jackson, J.L., O'Malley, P.G. and Kroenke, K. (2003) Evaluation of Acute Knee Pain in Primary Care. *Annals of Internal Medicine*, **139**, 575-588.
<https://doi.org/10.7326/0003-4819-139-7-200310070-00010>
- [9] Ding, C., Martel-Pelletier, J., Pelletier, J.P., Abram, F., Raynauld, J.P., Cicuttini, F. and Jones, G. (2007) Meniscal Tear as an Osteoarthritis Risk Factor in a Largely Non-Osteoarthritic Cohort: A Cross-Sectional Study. *The Journal of Rheumatology*, **34**, 776-784.
- [10] LaPrade, R.F., Moulton, S.G., Cram, T.R., Geeslin, A.G., LaPrade, C.M. and Engebretsen, L. (2015) Medial and Lateral Meniscal Inside-Out Repairs. *JBJS Essential Surgical Techniques*, **5**, e24. <https://doi.org/10.2106/JBJS.ST.N.00097>
- [11] Cohen, S.B., Short, C.P., O'Hagan, T., Wu, H.T., Morrison, W.B. and Zoga, A.C. (2012) The Effect of Meniscal Tears on Cartilage Loss of the Knee: Findings on Serial MRIs. *The Physician and Sportsmedicine*, **40**, 66-76.
<https://doi.org/10.3810/psm.2012.09.1983>
- [12] Jørgensen, U., Sonne-Holm, S., Lauridsen, F. and Rosenklint, A. (1987) Long-Term Follow-up of Meniscectomy in Athletes. A Prospective Longitudinal Study. *The Journal of Bone and Joint Surgery. British Volume*, **69**, 80-83.
<https://doi.org/10.1302/0301-620X.69B1.3818740>
- [13] Boszotta, H., Helperstorfer, W., Köndorfer, G., Prünner, K. and Ohrenberger, G. (1994) Long-Term Results of Arthroscopic Meniscectomy. *Aktuelle Traumatologie*, **24**, 30-34.
- [14] Roos, H., Laurén, M., Adalberth, T., Roos, E.M., Jonsson, K. and Lohmander, L.S. (1998) Knee Osteoarthritis after Meniscectomy: Prevalence of Radiographic Changes after Twenty-One Years, Compared with Matched Controls. *Arthritis & Rheumatism*, **41**, 687-693.
[https://doi.org/10.1002/1529-0131\(199804\)41:4<687::AID-ART16>3.0.CO;2-2](https://doi.org/10.1002/1529-0131(199804)41:4<687::AID-ART16>3.0.CO;2-2)
- [15] Stein, T., Mehling, A.P., Welsch, F., von Eisenhart-Rothe, R. and Jäger, A. (2010) Long-Term Outcome after Arthroscopic Meniscal Repair versus Arthroscopic Partial Meniscectomy for Traumatic Meniscal Tears. *The American Journal of Sports Medicine*, **38**, 1542-1548. <https://doi.org/10.1177/0363546510364052>
- [16] Crema, M.D., Guermazi, A., Li, L., et al. (2010) The Association of Prevalent Medial Meniscal Pathology with Cartilage Loss in the Medial Tibiofemoral Compartment over a 2-Year Period. *Osteoarthritis & Cartilage*, **28**, 336-343.
<https://doi.org/10.1016/j.joca.2009.11.003>
- [17] Henry, S., Mascarenhas, R., Kowalchuk, D., Forsythe, B., Irrgang, J.J. and Harner, C.D. (2012) Medial Meniscus Tear Morphology and Chondral Degeneration of the Knee: Is There a Relationship? *Arthroscopy*, **28**, 1124-1134.
<https://doi.org/10.1016/j.arthro.2011.12.020>
- [18] Ding, J., Zhao, J., He, Y., Huangfu, X. and Zeng, B. (2009) Risk Factors for Articular Cartilage Lesions in Symptomatic Discoid Lateral Meniscus. *Arthroscopy*, **25**, 1423-1426. <https://doi.org/10.1016/j.arthro.2009.06.024>
- [19] Boks, S.S., Vroegindewij, D., Koes, B.W., Hunink, M.G. and Bierma-Zeinstra, S.M. (2006) Follow-up of Posttraumatic Ligamentous and Meniscal Knee Lesions Detected at MR Imaging: Systematic Review. *Radiology*, **238**, 863-871.
<https://doi.org/10.1148/radiol.2382050063>
- [20] Howell, J. and Handoll, H. (2000) Surgical Treatment for Meniscal Injuries of the Knee in Adults. *Cochrane Database of Systematic Reviews*.
<https://doi.org/10.1002/14651858.CD001353>

- [21] Logerstedt, D.S., Scalzitti, D.A., Bennell, K.L., Hinman, R.S., Silvers-Granelli, H., Ebert, J., *et al.* (2018) Knee Pain and Mobility Impairments: Meniscal and Articular Cartilage Lesions Revision. *Journal of Orthopaedic & Sports Physical Therapy*, **48**, A1-A50. <https://doi.org/10.2519/jospt.2018.0301>
- [22] Kijowski, R., Woods, M.A., Mcguine, T.A., Wilson, J.J., Graf, B.K. and Smet, A.A.D. (2011) Arthroscopic Partial Meniscectomy: MR Imaging for Prediction of Outcome in Middle-Aged and Elderly Patients. *Radiology*, **259**, 203-212. <https://doi.org/10.1148/radiol.11101392>
- [23] Brittberg, M. and Winalski, C.S. (2003) Evaluation of Cartilage Injuries and Repair. *The Journal of Bone and Joint Surgery-American*, **85**, 58-69. <https://doi.org/10.2106/00004623-200300002-00008>
- [24] Anderson, A.F., Irrgang, J.J., Dunn, W., Beaufils, P., Cohen, M., Cole, B.J., *et al.* (2011) Interobserver Reliability of the International Society of Arthroscopy, Knee Surgery and Orthopaedic Sports Medicine (ISAKOS) Classification of Meniscal Tears. *The American Journal of Sports Medicine*, **39**, 926-932. <https://doi.org/10.1177/0363546511400533>
- [25] Melrose, J., Fuller, E.S. and Little, C.B. (2017) The Biology of Meniscal Pathology in Osteoarthritis and Its Contribution to Joint Disease: Beyond Simple Mechanics. *Connective Tissue Research*, **58**, 282-294. <https://doi.org/10.1080/03008207.2017.1284824>
- [26] Chambers, H.G. and Chambers, R.C. (2019) The Natural History of Meniscus Tears. *Journal of Pediatric Orthopaedics*, **39**, S53-S55. <https://doi.org/10.1097/BPO.0000000000001386>
- [27] Monk, P., Roberts, P., Palmer, A.J., Bayliss, L., Mafi, R., Beard, D., *et al.* (2017) The Urgent Need for Evidence in Arthroscopic Meniscal Surgery. *The American Journal of Sports Medicine*, **45**, 965-973. <https://doi.org/10.1177/0363546516650180>
- [28] Anderson, D., Chubinskaya, S., Guilak, F., Martin, J.A., Oegema, T.R., Olson, S.A. and Buckwalter, J.A. (2011) Post-Traumatic Osteoarthritis: Improved Understanding and Opportunities for Early Intervention. *Journal of Orthopaedic Research*, **29**, 802-809. <https://doi.org/10.1002/jor.21359>
- [29] Maffulli, N., Longo, U.G., Campi, S. and Denaro, V. (2010) Meniscal Tears. *Open Access Journal of Sports Medicine*, **2010**, 45-54. <https://doi.org/10.2147/OAJSM.S7753>
- [30] Englund, M., Roos, E.M., Roos, H.P. and Lohmander, L.S. (2001) Patient-Relevant Outcomes Fourteen Years after Meniscectomy: Influence of Type of Meniscal Tear and Size of Resection. *Rheumatology*, **40**, 631-639. <https://doi.org/10.1093/rheumatology/40.6.631>
- [31] McNicholas, M.J., Rowley, D.I., McGurty, D., Adalberth, T., Abdon, P., Lindstrand, A. and Lohmander, L.S. (2000) Total Meniscectomy in Adolescence. A Thirty-Year Follow-up. *The Journal of Bone and Joint Surgery. British Volume*, **82**, 217-221.
- [32] Beaufils, P. and Pujol, N. (2017) Management of Traumatic Meniscal Tear and Degenerative Meniscal Lesions. Save the Meniscus. *Orthopaedics & Traumatology: Surgery & Research*, **103**, S237-S244. <https://doi.org/10.1016/j.otsr.2017.08.003>
- [33] Verdonk, R., Madry, H., Shabshin, N., Dirisamer, F., Peretti, G.M., Pujol, N., *et al.* (2016) The Role of Meniscal Tissue in Joint Protection in Early Osteoarthritis. *Knee Surgery, Sports Traumatology, Arthroscopy*, **24**, 1763-1774. <https://doi.org/10.1007/s00167-016-4069-2>
- [34] Moulton, S.G., Bhatia, S., Civitarese, D.M., Frank, R.M., Dean, C.S. and LaPrade, R.F. (2016) Surgical Techniques and Outcomes of Repairing Meniscal Radial Tears: A Systematic Review. *Arthroscopy*, **32**, 1919-1925.