



# Evaluating the Protective and Ameliorative Potential of Unripe Palm Kernel Seeds on Monosodium Glutamate-Induced Uterine Fibroids

Orinamhe Godwin Agbadua<sup>1,2\*</sup>, Lilian Etinosa Idusogie<sup>1</sup>, Amadi Samuel Chukwuebuka<sup>1</sup>, Chukwu Sunday Nnamdi<sup>1</sup>, Samuel Sylvester<sup>1</sup>

<sup>1</sup>Department of Biochemistry, Faculty of Life Sciences, University of Benin, Benin, Nigeria

<sup>2</sup>Institute of Pharmacognosy, Faculty of Pharmacy, University of Szeged, Szeged, Hungary

Email: \*orinamhe.agbadua@pharmacognosy.hu, liliansogie@yahoo.com, amadi.ebuka1942@gmail.com, sunnychukwu4all@gmail.com, sammysyle@gmail.com

**How to cite this paper:** Agbadua, O.G., Idusogie, L.E., Chukwuebuka, A.S., Nnamdi, C.S. and Sylvester, S. (2020) Evaluating the Protective and Ameliorative Potential of Unripe Palm Kernel Seeds on Monosodium Glutamate-Induced Uterine Fibroids. *Open Access Library Journal*, 7: e6461.

<https://doi.org/10.4236/oalib.1106461>

**Received:** May 26, 2020

**Accepted:** June 8, 2020

**Published:** June 11, 2020

Copyright © 2020 by author(s) and Open Access Library Inc.

This work is licensed under the Creative Commons Attribution International License (CC BY 4.0).

<http://creativecommons.org/licenses/by/4.0/>



Open Access

## Abstract

The study investigated the protective and curative effects of unripe palm kernel seeds on monosodium glutamate-induced uterine fibroid in rats. The rats were in eight experimental groups according to the time of administration of the unripe palm kernel seeds: the first four groups investigated protective effects of UPK for 28 days and the last four groups investigated the curative effects of UPK after treatment with MSG for 28 days. MSG was administered to the animals by oral gavage at a dose of 200 mg/kg bd wt and UPK was administered as feed at a dose of 1.14 mg/g bd wt during the period of study. Histopathology studies of the uterus in addition to serum total protein, total cholesterol, estrogen and progesterone levels were determined. Significant increased estrogen and progesterone levels were observed in MSG-treated animals. UPK prevented and also led to the reversal of these biomarkers in this study. MSG also resulted in endometrial epithelium distortion and lamina propria fibrosis with UPK ameliorating the distortion observed in the uterus. These findings suggest that UPK contains bioactive constituents that are useful in preventing and reversing MSG-induced uterine hyperplasia.

## Subject Areas

Biological Chemistry, Medicinal Chemistry

## Keywords

Fibroid, Estrogen, Palm Kernel

## 1. Introduction

African oil palm (*Elaeis guineensis*), native to west and southwest Africa, is mainly grown for its industrial production of oil. The fruit produces two types of oil: the palm oil from the mesocarp and the kernel oil from its kernel [1] [2]. The various parts of the tree have been reported to possess several medicinal uses [3].

Uterine fibroids are common non-cancerous or benign tumors that develop in or around the uterus, often affecting women in reproductive age [4]. Several genetic, biological and hormonal factors have been shown to contribute to the development and growth of fibroid, with uterine fibroid often most prevalent in black women [5]. Ample evidence supports hormones, estrogen and progesterone, as important factors in the etiology of uterine fibroids, with high level of estrogen reported to be the most common cause of fibroid [6] [7] [8].

Monosodium glutamate, a sodium salt of glutamic acid, is used in the food industry as a flavor enhancer and a popular food additive [9] [10]. Studies have shown that monosodium glutamate (MSG) induces uterine fibroid in rats by increasing the levels of total protein, cholesterol and estradiol [11] [12] [13].

Current treatment of uterine fibroids involves evasive and non-evasive methods like myomectomy, hysterectomy, hormone replacement therapy and uterine artery embolization [14] [15]. Given the risks, side effects associated with these methods and health care costs, there is an increased demand to find alternative and cheap means for the treatment and management of numerous disease conditions. Herbal practitioners have often recommended daily doses of unripe African oil palm (*Elaeis guineensis*) kernel seeds over a period of time, and this has been reported to be successful in reducing fibroids. However, there is unavailability of scientific data on the mechanism of this action and thus, this research was aimed at discovering the mechanism(s) by which unripe palm kernel seed is used in managing and/or treating uterine fibroid in female Wistar rats.

## 2. Materials and Methods

### 2.1. Experimental Animals

Forty female albino rats of Wistar strain with weights ranging from 90 - 110 g were purchased from the Department of Biochemistry, University of Benin. The animals were allowed to acclimatize for 14 days under standard laboratory conditions (12-hour light/dark cycle, standard conditions of temperature and humidity, and good hygiene practices) during which they were given chow and clean drinking water. The rats used in this study showed regular estrous cycle length (4 to 5 days) with these cycles assessed by observing the vaginal smear in the morning according to the procedure described by Solomon *et al.* [16].

### 2.2. Oil Palm Kernel

Unripe oil palm kernel (UPK) fruits were purchased from Nigeria Institute for Oil Palm Research (NIFOR), Edo State. Fruit samples were authenticated and identified at the Department of Plant Biology and Biotechnology, University of

Benin, and a specimen with voucher number UBH-E444, deposited. The unripe seed nuts were cracked open with nut crackers and chaffs separated from the seeds, after which they were refrigerated to avoid desiccation and fermentation.

### **2.3. Monosodium Glutamate**

A stock solution of monosodium glutamate (Sigma Aldrich Chemical Co., St Louis, USA) was prepared according to methods described by Olowofolahan *et al.* [17] by dissolving 200 mg of the salt in 200 mL distilled water. The stock MSG was kept under room temperature for the total period of administration.

### **2.4. Ethical Approval**

Experimental protocols were carried out according to the approval and guidelines given by the University of Benin Ethical Committee. These rules, similar to international guidelines on animal handling, conformed to the acceptable guidelines on the ethical use of animals in research.

### **2.5. Experimental Design**

After the period of acclimatization, when the rats reached an average weight of 150 g, the rats were divided into two groups: protective and curative; with each group containing four sub-groups of five rats each.

#### *Protective studies:*

Group A rats received neither MSG nor UPK seeds during the period of study (this served as the control group). Group B rats received MSG for 28 days. Group C rats received UPK seeds for 28 days. Rats in group D received MSG and UPK seeds for 28 days.

#### *Curative studies:*

Group E rats received neither MSG nor UPK seeds for 42 days, the period of study (this was the control group). Group F rats received no MSG, but were given UPK seeds from day 28 to day 42.

Group G rats received MSG for 28 days and thereafter stopped, with normal rat chow continued till day 42. Group H rats received MSG for 28 days, with UPK seeds started thereafter till day 42.

Monosodium glutamate was administered daily as a single oral dose, by oral gavage, at 200 mg/kg body weight of animals. The unripe palm kernel seeds were also administered based on the weight of the individual rat. Seeds were crushed to obtain smaller pieces which were sizeable for administration to experimental animals. Rats were given 1.14 mg UPK seed/g rat body weight as food, with the amount given calculated from the corresponding amount prescribed by the herbal practitioners to an average female human (in weight) during the period of treatment, which is 25 seeds daily/60kg weight of average female.

### **2.6. Sample Collection and Preparation**

At the end of the period of treatment, the animals were sacrificed by chloroform

anesthesia. Blood was collected by cardiac puncture into EDTA sterilized sample containers. Samples were centrifuged (3000 rpm, 20 min) and serum collected for biochemical analyses. The uterus samples were harvested and preserved using 10% neutral buffered formalin placed in pre-labelled universal containers for histology.

## 2.7. Biochemical Assay and Histology Studies

Total protein and total cholesterol were determined spectrophotometrically as described in the Randox kit (CH200 and TP4001 respectively, Randox Laboratories Ltd., Crumlin, UK). Estrogen and progesterone levels were measured by modifications of Competitive Enzyme Immunoassay as described by Meyer *et al.* [18]. Using all standard operating procedures, uterus samples were dissected and placed in labelled tissue cassettes with thickness of tissues not exceeding 3 - 5 mm. Tissues were processed using the Leica TP2010 automatic tissue processor (Leica Microsystems, Germany) for 18 hours passing the tissues through fixation (using 10% neutral buffered formalin), dehydration (using ascending grades of isopropyl alcohol), cleared using xylene and finally impregnated by molten paraffin wax. Paraffin wax-embedded tissues were subsequently processed into ultra-thin sections of 5 microns using a thermo-scientific semi-automated rotary microtome, dried overnight and subjected to hematoxylin and eosin staining. Stained slides were mounted on DPX and subsequently viewed under the microscope (Leica DM 500 microscope, Germany), and photomicrographs taken.

## 2.8. Statistical Analysis

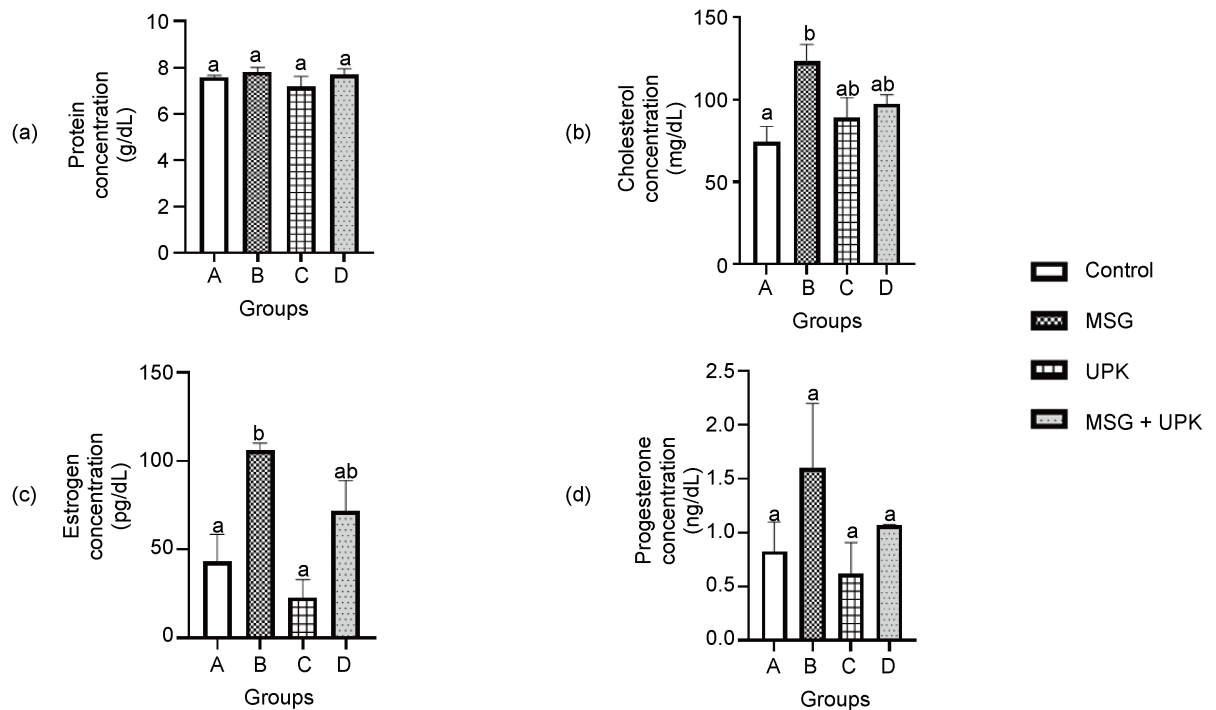
Results are expressed as Mean  $\pm$  SEM. Statistical differences were derived using one-way analysis of variance (ANOVA) with Turkey's *post hoc* test. A p-value < 0.05 was considered statistically significant. Bar graphs were obtained using Graph Pad Prism software 8.01.

## 3. Results

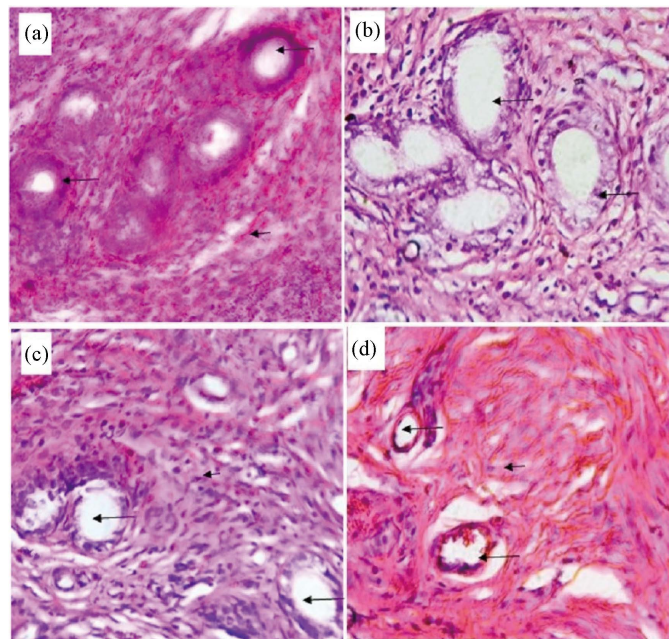
### 3.1. Protective Effects of Unripe Palm Kernel Seeds on Monosodium Glutamate-Induced Uterine Fibroid

The effect of unripe palm kernel seeds on preventing MSG-induced changes in the serum levels of protein, cholesterol, estrogen and progesterone is shown in **Figure 1**. Treatment with MSG significantly led to an increase in serum cholesterol and estrogen levels; 123.20 mg/dL and 106 pg/mL respectively, when compared to rats in the control group (78.48 mg/dL and 43.00 pg/mL).

**Figure 2** shows the photomicrographs of the uteri of rats in the protective study group. Rats given only unripe palm kernel seeds showed prominent endometrial glands (long arrow) embedded in the lamina propria (short arrow) and visible close up of simple columnar epithelium and lamina propria, which corresponded to the photomicrograph of the control group. Monosodium glutamate administration resulted in uteri with endometrial epithelium surrounding



**Figure 1.** Protective effect of unripe palm kernel seeds on serum biochemical levels in MSG-treated female rats: (a) total protein; (b) total cholesterol; (c) estrogen; (d) progesterone. Results are expressed as mean  $\pm$  SEM ( $n = 4$  for protein and cholesterol analysis and  $n = 2$  for hormonal analysis). Values with different superscript vary significantly ( $p < 0.05$ ).



**Figure 2.** Photomicrographs of the endometrial epithelium of rats in the protective study, H & E (Magnification  $\times 400$ ). (a) Control group showing normal uteri anatomy, germinal endometrial glands (long arrow) embedded in the lamina propria (short arrow); (b) Rats given 200 mg MSG/kg bd wt. show distorted elongated epithelial cells (long arrows); (c) Rats given 1.14 mg UPK seed/g bd wt. shows normal anatomy; (d) Rats given 200 mg MSG/kg bd wt. and 1.14 mg UPK seed/g bd wt. shows with little evidence of fibrosis in the lamina propria (long arrow).

the lumen having distorted elongated epithelial cells. There was also evidence of distortion and hyperkeratosis of chromatin. Co-administration of MSG and UPK resulted in lamina propria with little fibrosis compared to the rats which received only MSG, thus suggesting some form of mitigation of the effect of MSG by the UPK seeds.

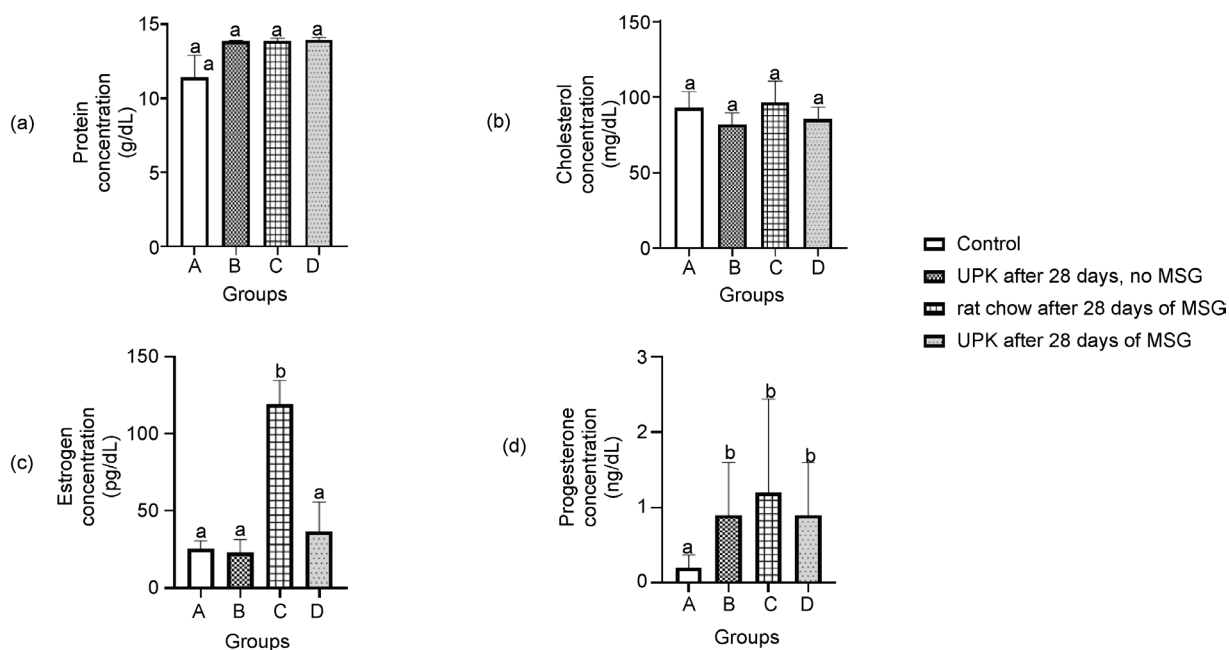
### 3.2. Curative Effect of Unripe Palm Kernel Seeds after Monosodium Glutamate-Induced Uterine Fibroid

The effect of unripe palm kernel seeds on ameliorating MSG-induced changes in the serum levels of protein, cholesterol, estrogen and progesterone is shown in **Figure 3**. Rats treated with MSG only for 28 days had significantly high levels of estrogen (119.00 pg/mL) and progesterone (1.2 ng/mL) compared to other treatment groups. Subsequent administration of unripe palm kernel (UPK) seeds for 14 days after treatment with MSG to female rats reversed the levels of these hormones by reducing levels of estrogen (36.50 pg/mL) and progesterone (0.90 ng/mL) to levels, even comparable to the control group.

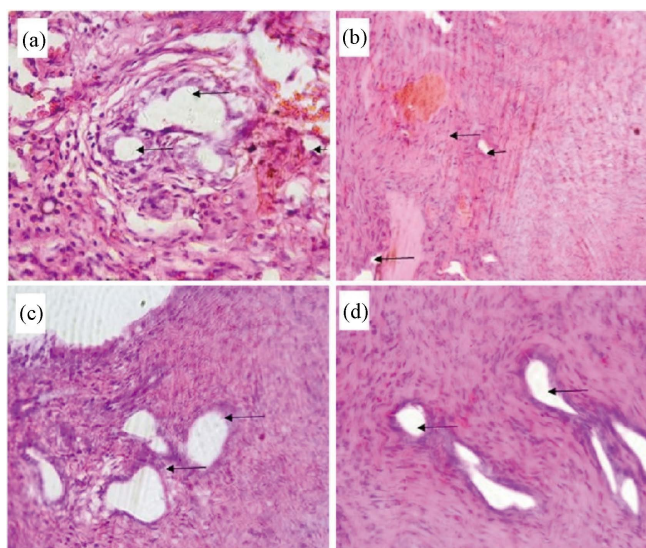
The photomicrographs of the uterus of rats in the curative treatment design are presented in **Figure 4**. Rats which received MSG only had atrophied endometrial epithelium and distortion in the lamina propria, which are early signs of benign tumor growth. Adding UPK seeds to the diet of the female rats reduced the distortion observed in the epithelial cells and lamina propria.

## 4. Discussion

The potential benefits of unripe oil palm kernel seeds in the prevention and



**Figure 3.** Curative effect of unripe palm kernel seeds on serum biochemical levels of MSG-treated female rats: (a) total protein; (b) total cholesterol; (c) estrogen; (d) progesterone. Results are expressed as mean  $\pm$  SEM ( $n = 4$  for protein and cholesterol analysis and  $n = 2$  for hormonal analysis). Values with different superscript vary significantly ( $p < 0.05$ ).



**Figure 4.** Photomicrograph of the endometrial epithelium of rats in the curative group (Magnification  $\times 400$ ). (a) Rats in control group with prominent endometrial glands (long arrow) embedded in the lamina propria (short arrow); (b) Rats given 1.14 mg UPK seed/g bd wt. shows areas of mild distortion in epithelium and lamina propria (short arrow); (c) Rats given 200 mg MSG/kg bd wt. show areas of fibrosis (long black arrow); (d) Rats given 1.14 mg UPK seed/g bw after 200 mg MSG/kg bd wt. with some evidence of distortion of chromatin (black arrow).

treatment of uterine fibroids was investigated in this study. Ovarian steroid hormones have been shown to be important biomarkers associated with the growth and development of uterine fibroid. While estrogen has been considered the major factor, there is growing evidence suggesting that progesterone and its receptors, play a key role in the growth and development of uterine fibroid [19].

Monosodium glutamate led to an increase in the levels of estrogen and progesterone, which corroborates reports of [17] [20] [21] [22] who observed similar increase in these biochemical markers. Monosodium glutamate increases estrogen levels by activating aromatase, an enzyme that catalyzes estrogen (estradiol) synthesis by converting testosterone to  $\beta$ -estradiol and subsequent aromatisation of  $\beta$ -estradiol [12]. Monosodium glutamate also led to an increase in serum total cholesterol levels which agrees with previous studies [12] [17] [20] [23]. Cholesterol is an important precursor in the biosynthesis of several steroid hormones which are powerful signal molecules regulating a host of functions in living organisms [24]. The elevated levels of cholesterol in rats treated with monosodium glutamate only may aid in explaining the observed elevated serum estrogen and progesterone levels. Histopathology studies of the uterus revealed distorted or atrophied endometrial epithelium and evidence of fibrosis in the lamina propria of rats treated with monosodium glutamate, which is similar to reports by [20].

Co-treatment with monosodium glutamate and unripe palm kernel seeds led to a decrease in estrogen levels. This agrees with findings of Oyebo *et al.* [20]

who studied the protective effects of alpha stone decoction on monosodium glutamate-induced uterine fibroid. It also agrees with other studies by Obochi *et al.* [12] and Olowofolahan *et al.* [17], who investigated the effects of garlic extracts and extracts of *Drymaria cordota* respectively, on MSG-induced uterine fibroid. One of the proposed mechanisms of action of unripe palm kernel seeds against uterine fibroid growth and development can be attributed to the inhibition of aromatase, thus preventing the synthesis of estrogen. The protective effect of unripe oil palm kernel seeds was also confirmed by a decrease in serum progesterone levels in the co-treated rats as observed in previous study [19]. Reis *et al.* [25] showed that estradiol and progesterone are important in the transformation of myometrial cells into leiomyoma cells with progesterone required for the complete development and proliferation of leiomyoma cells. As estrogen and progesterone are key hormones in the pathogenesis of leiomyoma formation [26], decrease in the serum levels of these hormones associated with unripe palm kernel seeds may explain the use of this treatment method by herbal practitioners. The ability of unripe palm kernel seeds to reverse induced fibroids was also investigated by administering the seeds after treatment with monosodium glutamate. Unripe palm kernel seeds reversed the elevated estrogen and progesterone levels caused by monosodium glutamate.

Unripe palm kernel seeds co-treatment also resulted in decreased the cholesterol levels as observed in similar studies which involved several other ameliorative natural products [12] [17] [20]. The decrease in serum cholesterol levels may be another mechanism of action by which the unripe palm kernel seeds acts in protecting against uterine fibroid development. Photomicrographs of the uteri of the female rats which were co-treated with unripe palm kernel seeds, and the rats which received unripe palm kernel seeds showed little evidence of fibrosis in the lamina propria, suggesting a protection against the development of leiomyoma and reduction in its growth.

This study provides scientific explanation to the claims by herbal practitioners who recommend daily doses of unripe palm kernel seeds in the management and treatment of fibroids. Unripe palm kernel seeds reduced the estrogen and decrease in progesterone levels, with a concomitant decrease in cholesterol levels, all of which have been reported to be the mechanism by which other natural products affect uterine fibroids.

## 5. Conclusion

In conclusion, these findings suggest that unripe palm kernel provides a natural, readily available and cheap alternative in the management and treatment of fibroids. Unripe palm kernel seeds may contain bioactive constituents useful in the management of fibroids. Unripe palm kernel reduces serum hormone levels which play roles in the etiology of uterine fibroid. Further work would be important in determining the potential effects or toxicity associated with daily consumption of unripe palm kernel seeds over an extended period of time.



## Acknowledgement

The authors acknowledge the Department of Anatomy, University of Benin Teaching Hospital (UBTH) for the help with histology studies. The authors would also like to express gratitude to MeRB Africa, Benin city, for providing laboratory space for biochemical analysis.

## Declaration of Interest Statement

The authors declare that there is no conflict of interest.

## References

- [1] Obahiagbon, F.I. (2012) A Review: Aspects of the African Oil Palm (*Elaeis guineensis* Jacq.) and the Implications of Its Bioactivities in Human Health. *American Journal of Biochemistry and Molecular Biology*, **2**, 106-119. <https://doi.org/10.3923/ajbmb.2012.106.119>
- [2] Aba, S.C. and Baiyeri, K.P. (2012) The Oil Palm. In: Eze, S.C., Onyeonagu, C.C., Ezeaku, P.I. and Machebe, N.S., Eds., *Handbook of Practical Agriculture*, Chenglo Ltd., Enugu, 224-229.
- [3] Owoyele, B.V. and Owolabi, G.O. (2014) Traditional Oil Palm (*Elaeis guineensis* Jacq.) and Its Medicinal Uses: A Review. *TANG (HUMANITAS MEDICINE)*, **4**, 1-8. <https://doi.org/10.5667/tang.2014.0004>
- [4] Dolmans, M., Donnez, J. and Fellah, L. (2019) Uterine Fibroid Management: Today and Tomorrow. *Journal of Obstetrics and Gynaecology Research*, **45**, 1222-1229. <https://doi.org/10.1111/jog.14002>
- [5] Eltoukhi, H.M., Modi, M.M., Weston, M., Armstrong, A.Y. and Stewart, E.A. (2014) The Health Disparities of Uterine Fibroids for African American Women: A Public Health Issue. *American Journal of Obstetrics & Gynecology*, **210**, 194-199. <https://doi.org/10.1016/j.ajog.2013.08.008>
- [6] Borahay, M.A., Asoglu, M.R., Mas, A., Adam, S., Kilic, G.S. and Al-Hendy, A. (2017) Estrogen Receptors and Signaling in Fibroids: Role in Pathobiology and Therapeutic Implications. *Reproductive Sciences*, **24**, 1235-1244. <https://doi.org/10.1177/1933719116678686>
- [7] Cohen, D., Mazur, M.T., Jozefczyk, M.A. and Badway, A. (1994) Hyalinization and Cellular Changes in Uterine Leiomyomata after Gonadotrophin-Releasing Hormone Agonist Therapy. *The Journal of Reproductive Medicine*, **39**, 377-380.
- [8] Johnston, S.R. and Dowsett, M. (2003) Aromatase Inhibitors for Breast Cancer: Lessons from the Laboratory. *Nature Reviews Cancer*, **3**, 821-831. <https://doi.org/10.1038/nrc1211>
- [9] Bera, T.K., Kar, S.K., Yadav, P.K., Mukherjee, P., Yadav, S. and Joshi, B. (2017) Effects of Monosodium Glutamate on Human Health: A Systematic Review. *World Journal of Pharmaceutical Sciences*, **5**, 139-144.
- [10] Yamaguchi, S and Ninomiya, K. (2000) Umami and Food Palatability. *The Journal of Nutrition*, **130**, 921-926. <https://doi.org/10.1093/jn/130.4.921S>
- [11] Eweka, A.O. and Adjene, J.O. (2007) Histological Studies of the Effects of *Monosodium glutamate* on the Medial Geniculate Body of Adult Wister Rat. *The Electronic Journal of Biomedicine*, **22**, 9-13.
- [12] Obochi, G.O., Malu, S.P., Obi-Abang, M., Alozie, Y. and Iyam, M. (2009) Effect of

- Garlic Extracts on MSG Induced Fibroid in Wistar Rats. *Pakistan Journal of Nutrition*, **8**, 970-976. <https://doi.org/10.3923/pjn.2009.970.976>
- [13] Koffuor, A.G., Annan, K., Kyekyeku, J.O., Fiadjoe, H.K. and Enyan, E. (2013) Effect of Ethanolic Stem Bark Extract of *Blighia unijugata* (Sapindaceae) on Monosodium Glutamate-Induced Uterine Leiomyoma in Sprague Dawley Rats. *British Journal of Pharmaceutical Research*, **3**, 880-896. <https://doi.org/10.9734/BJPR/2013/5402>
- [14] Farris, M., Bastianelli, C., Rosato, E., Brosens, I. and Benagiano, G. (2019) Uterine Fibroids: An Update on Current and Emerging Medical Treatment Options. *Therapeutics and Clinical Risk Management*, **15**, 157-178. <https://doi.org/10.2147/TCRM.S147318>
- [15] Sohn, G.S., Cho, S., Kim, Y.M., Cho, C.H., Kim, M.R. and Lee, S.R. (2018) Current Medical Treatment of Uterine Fibroids. *Obstetrics & Gynecology Science*, **61**, 192-201. <https://doi.org/10.5468/ogs.2018.61.2.192>
- [16] Solomon, T.L., Mekbeb, Z., Eyasu, A.M. and Asfaw, D. (2010) Effect of *Rumex steudelii* Methanolic Root Extract on Ovarian Folliculogenesis Anduterine Histology in Female Albino Rats. *African Health Sciences*, **10**, 353-361.
- [17] Olowofolahan, A.O., Aina, O.O., Hassan, E.T. and Olorunsogo, O.O. (2017) Ameliorative Potentials of Methanol Extract and Chloroform Fraction of *Drymaria cordata* on MSG-Induced Uterine Hyperplasia in Female Wistar Rats. *European Journal of Medicinal Plants*, **20**, 1-9. <https://doi.org/10.9734/EJMP/2017/36335>
- [18] Dou, M., Zhu, K., Fan, Z., Zhang, Y., Chen, X., Zhou, X., Ding, X., Li, L., Gu, Z., Guo, M., Yan, M., Deng, X., Shen, P. and Wang, S. (2017) Reproductive Hormones and Their Receptors May Affect Lung Cancer. *Cellular Physiology and Biochemistry*, **44**, 1425-1434. <https://doi.org/10.1159/000485538>
- [19] Cermik, D., Arici, A. and Taylor, H.S. (2002) Coordinated Regulation of HOX Gene Expression in Myometrium and Uterine Leiomyoma. *Fertility and Sterility*, **78**, 979-984. [https://doi.org/10.1016/S0015-0282\(02\)03366-6](https://doi.org/10.1016/S0015-0282(02)03366-6)
- [20] Oyeboode, O.T., Obiekwe, M.E. and Olorunsogo, O.O. (2019) Protective Effects of Alpha Stone on Monosodium Glutamate-Induced Uterine Hyperplasia in Female Wistar Rats. *Journal of Ayurveda and Integrative Medicine*, in Press. <https://doi.org/10.1016/j.jaim.2019.05.001>
- [21] Olanrewaju, A.J., Olatunji, S.Y., Owolabi, J.O., Oribamise, E.I., Omotuyi, O.I. and Desalu, A.B.O. (2017) Adeno-Hypophyseal Consequence of Uterine Fibroid and the Effects of Ginger Extract on the Monosodium Glutamate-Induced Tumor. *Journal of Advances in Medicine and Medical Research*, **24**, 1-11. <https://doi.org/10.9734/JAMMR/2017/35226>
- [22] Zia, M.S., Qamar, K., Hanif, R. and Khalil, M. (2014) Effect of Monosodium Glutamate on the Serum Estrogen and Progesterone Levels in Female Rat and Prevention of This Effect with Diltiazem. *Journal of Ayub Medical College Abbottabad*, **26**, 18-20.
- [23] Tousson, E., El-Atrash, A. and Karson, Y. (2019) Protective Role of Rocket Seed (*Eruca sativa*) Extract against Monosodium Glutamate-Induced Hepato-Renal Toxicity in Male Rats. *Asian Journal of Research in Medical and Pharmaceutical Sciences*, **8**, 1-10. <https://doi.org/10.9734/ajrimps/2019/v8i3-430136>
- [24] Payne, A.H. and Hales, D.B. (2004) Overview of Steroidogenic Enzymes in the Pathway from Cholesterol to Active Steroid Hormones. *Endocrine Reviews*, **25**, 947-970. <https://doi.org/10.1210/er.2003-0030>
- [25] Reis, F., Bloise, E. and Ortiga-Carvalho, T. (2015) Hormones and Pathogenesis of Uterine Fibroids. *Best Practice & Research Clinical Obstetrics & Gynaecology*, **34**,

13-24. <https://doi.org/10.1016/j.bpobgyn.2015.11.015>

- [26] Kim, J.J. and Sefton, E.C. (2012) The Role of Progesterone Signaling in the Pathogenesis of Uterine Leiomyoma. *Molecular and Cellular Endocrinology*, **358**, 223-231. <https://doi.org/10.1016/j.mce.2011.05.044>