

# The Utility of the Galea in Scalp Reconstruction

Jack D. Sudduth, John M. Sullivan, Marc E. Walker\*

Division of Plastic and Reconstructive Surgery, Department of Surgery, University of Mississippi Medical Center, Jackson, MS, USA

Email: \*mwalker6@umc.edu

**How to cite this paper:** Sudduth, J.D., Sullivan, J.M. and Walker, M.E. (2023) The Utility of the Galea in Scalp Reconstruction. *Modern Plastic Surgery*, 13, 16-22. <https://doi.org/10.4236/mps.2023.131002>

**Received:** November 1, 2022

**Accepted:** January 13, 2023

**Published:** January 16, 2023

Copyright © 2023 by author(s) and Scientific Research Publishing Inc.

This work is licensed under the Creative Commons Attribution International License (CC BY 4.0).

<http://creativecommons.org/licenses/by/4.0/>



Open Access

## Abstract

Total scalp avulsion is a time-sensitive, catastrophic injury requiring quick, complex decision-making. Traditionally, these injuries were treated with split-thickness skin grafts. With advancements in microsurgery, treatments evolved to scalp replantation, becoming the standard of care in scalp reconstruction. Although the integrity of the scalp's blood vessels is pivotal for successful replantation, the authors believe that scalp replantation should be considered at all costs. In the presented case, a 54-year-old female presented to the emergency room following an incident with an auger that completely avulsed her scalp. She was taken back to the operating room, where scalp replantation was performed. Following replantation, scalp necrosis led to serial debridings in the operating room, and eventually, all of the scalp was debrided down to healthy tissue. Surprisingly, the galea survived despite this, which provided a healthy base for skin grafts. Before definitive coverage was placed, it was decided to utilize a bilaminar acellular dermal matrix along with negative pressure wound therapy to create a more robust bed of granulation tissue. After three weeks of this treatment plan, the patient returned to the operating room, where a healthy, viable bed of granulating tissue was revealed beneath the dermal matrix. Split-thickness skin grafts were taken from her thighs bilaterally and sewn together in a quilt-like fashion to cover the wound bed. The entirety of the graft healed without complication except for one small area that required full-thickness skin grafting in an outpatient setting. Even though the replantation ultimately failed, it allowed the galea to survive, which saved the patient from undergoing a free tissue transfer and allowed her scalp to be reconstructed with split-thickness skin grafts. Even in the setting of polytrauma, the authors hope that anyone treating a scalp avulsion would consider scalp replantation at all costs.

## Keywords

Scalp Reconstruction, Scalp Replantation, Failed Replantation, Galea, Polytrauma, Split-Thickness Skin Grafts, Bilaminar Acellular Dermal Matrix

## 1. Introduction

Total scalp avulsion is a rare and devastating injury. Specific case examples of this typically involve an individual becoming entwined in a rotating piece of heavy machinery. The scalp is typically separated at the loose areolar layer, removing the skin, connective tissue, and galea aponeurotica while leaving the periosteum intact. Other facial structures such as the eyelids or ears can also be involved.

Historically, the treatment of choice for repairing scalp avulsions was with split-thickness skin grafts (STSG). [1] [2] [3] [4] The outcomes of scalp reconstruction with split-thickness skin grafts were less than satisfactory since the new scalp was fragile and not aesthetically pleasing, always requiring a wig. A transition was made to defatting the scalp and using it as a full-thickness skin graft to preserve the hair follicles and avoid having to wear a wig, but this had varying—and primarily poor—outcomes. [5] [6] In 1976, Miller published the first case of successful microvascular scalp replantation, which, in the correct scenario, became the standard of care. [7] However, successful replantation hinges on the integrity of the avulsed vessels. [8] Because replantation is not always viable, choosing a scalp reconstruction method can become rather complex. Additional options for reconstruction include local flaps, free flaps, tissue expansion, and negative pressure wound therapy (NPWT). Because of the number of options, Cen *et al.* published a clinical decision-making tree for scalp reconstruction. [9]

Various case reports have been published for scalp reconstruction, mostly of microvascular replantation. [10] [11] [12] [13] [14] While this is the current standard of care, it is not always successful or, in some cases, possible, and occasionally, alternative solutions are needed. Recently, publications have utilized older methods of split-thickness skin grafts for reconstruction. [8] [15] In the presented case, this was taken one step further by utilizing a bilaminar acellular dermal matrix, Integra, as an intermediary step prior to skin grafting to increase the integrity of the soft tissue reconstruction. Although the scalp replantation ultimately failed, the choice for coverage combined the use of Integra, negative pressure wound therapy, and split-thickness skin grafts based on the foundation of a surviving galea.

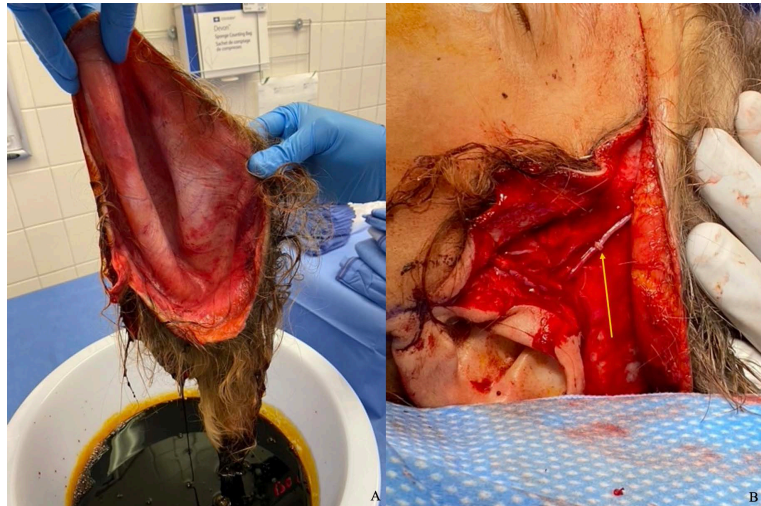## 2. Case Report

In January 2021, a 54-year-old female with a history of intravenous drug abuse presented to the emergency room intubated and sedated after an incident with an auger. The auger entrapped her hair and avulsed her scalp circumferentially while also completely transecting the upper half of the right ear. Additionally, to free her hair from the machine, she received multiple hand and wrist fractures bilaterally, including a partial digital amputation on her right hand. She was taken to the operating room for possible scalp replantation, surgical debridement, and fixation of the upper extremity injuries with possible replantation of the partially amputated digit. A three-team approach was taken to address the

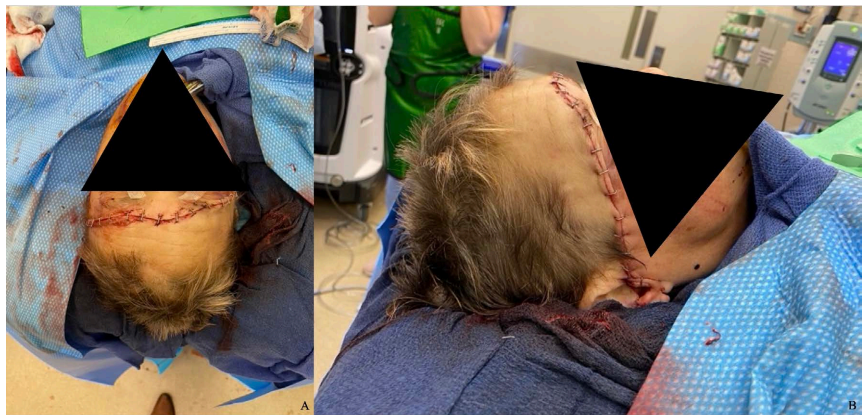issues at hand. The first team analyzed the avulsed scalp on a sterile back table for possible vessels that could be used for replantation [Figure 1(A)]. The second team investigated the head and found both the superficial temporal arteries and one vein that could be used for possible scalp replantation. The third team began investigating and repairing the upper extremity injuries and fractures. Given the nature of the injury and the polytrauma associated with the patient, the finger was not replanted. Scalp replantation was attempted with bilateral superficial temporal artery anastomosis and left-sided temporal vein anastomosis [Figure 1(B)]. Before leaving the operating room, a handheld doppler was used to identify individual cutaneous perforators marked with a Prolene stitch.

Following surgery, the patient was transferred to the intensive care unit for monitoring [Figure 2(A) & Figure 2(B)]. The patient was started on 81 mg aspirin, Lovenox, and broad-spectrum antibiotics postoperatively. In the preceding days following replantation, the scalp began to show signs of venous congestion on the right parietal region that extended to the right ear. Leech therapy was initiated on day two and continued through day four. After it was clear that portions of the right parietal scalp were developing necrosis, the patient was taken to the operating room for surgical investigation and debridement. The necrotic portions were debrided to healthy underlying tissue within the galeal layer. Over the coming days, the cutaneous skin extending to the occiput of the scalp continued to declare itself as non-viable. The patient returned to the operating room, where the posterior ischemic tissue was removed down to viable galeal tissue. Progression of ischemic necrosis continued for two weeks, requiring multiple return trips to the operating room. Unfortunately, the entire skin of the scalp was eventually debrided away, but interestingly, the galeal tissue had successfully been revascularized except for a few 3 - 4 cm areas. These areas of total tissue necrosis resulted in exposed calvarium.

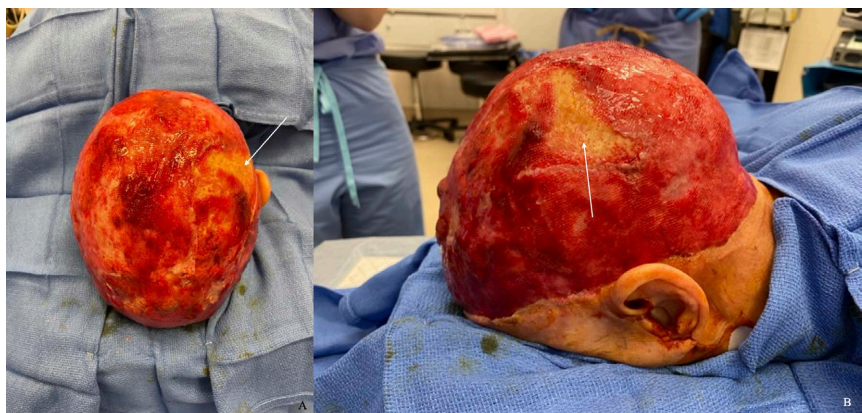
The galea remained viable after the final debridements, and it was determined that it would be stable to receive a graft. However, because of the tenuous progression of this case and the exposed calvarium, the decision was made to add an intermediate step before grafting. A bilaminar acellular dermal matrix, Integra, was chosen to help make the wound bed more robust and hopefully improve the long-term reconstruction. Before the application, the galea was debrided for a final time, and any areas of exposed cranium were burred until punctate bleeding was present. A negative pressure dressing was placed over the Integra and replaced weekly for three weeks. The silicone sheeting was removed, revealing a well-vascularized and well-incorporated dermal matrix [Figure 3(A) & Figure 3(B)]. Split thickness skin grafts taken from bilateral thighs were meshed and used to cover the vascularized wound bed. The entirety of the skin grafts, except for one area over previously exposed calvarium, healed without complication. The one area of 3 cm was eventually grafted with a full-thickness skin graft in an outpatient setting. Ultimately, the patient healed with complete scalp coverage [Figure 4(A) & Figure 4(B)].



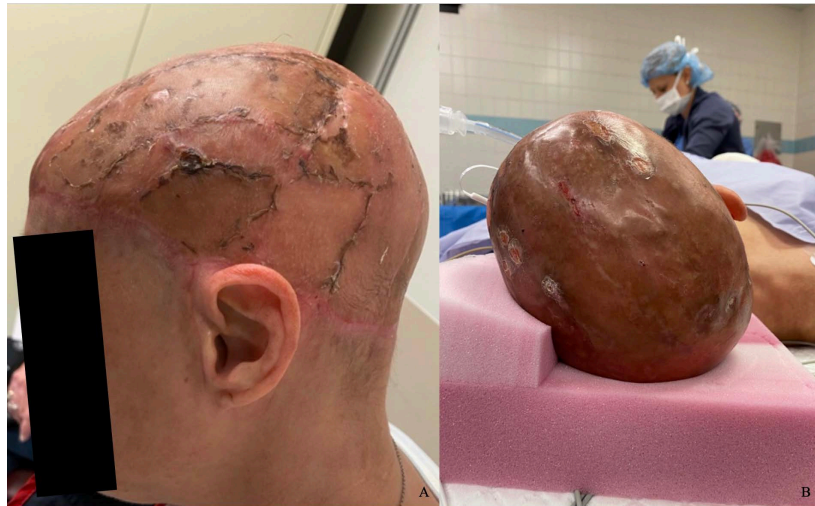**Figure 1.** (A) Avulsed scalp prior to replantation; (B) Scalp replantation demonstrating a venous anastomosis with a venous coupler (yellow arrow).



**Figure 2.** (A) Anterior view status post scalp replantation; (B) Right lateral view status post scalp replantation.



**Figure 3.** (A) Coronal view of superior scalp 5 weeks status post-accident demonstrating healthy granulation tissue over the galea after ADM removal and a small area of exposed calvarium (white arrow); (B) Left sagittal view of superior scalp 5 weeks status post-accident demonstrating healthy granulation tissue over the galea after ADM removal and a small area of exposed calvarium (white arrow).



**Figure 4.** (A) 4 weeks status post split-thickness skin graft placement with sutures still in place; (B) 13 weeks status post split-thickness skin grafts demonstrating a healed scalp. Presenting for small full-thickness skin graft placement.

### 3. Discussion

Scalp reconstruction after total scalp avulsion is a complex, time-sensitive operation typically repaired with scalp replantation. [12] In the polytrauma setting there are often more severe and pressing injuries. In this case, despite the various injuries inflicted by the auger, scalp replantation was attempted. With the repair of only two arteries and one vein, a large portion of the underlying galeal layer remained viable even as the more superficial tissue developed necrosis. Because of the galea's successful revascularization, the patient was able to receive STSGs and forego a free microvascular flap.

While it is essential to weigh the risks and benefits of proceeding with scalp replantation, especially in polytrauma patients, because of the chance of survival of the scalp's deeper, more vascular layers, replantation should be considered at all costs. It is likely, in this case, that the superficial layers of the scalp necrosed from its perforators being crushed or sheared at the time of the accident. Despite this, the replantation provided enough flow for the galea to remain viable. Dadaçi *et al.* reported a similar finding in a patient that underwent scalp replantation. The patient developed necrosis of the scalp and required serial debridements of the entire scalp, but the galea survived and was covered with STSGs. [11] They did not report using an ADM, however. An ADM, such as Integra, is prudent to consider as an adjuvant treatment to enhance coverage and provide a stable wound bed for STSGs, especially over exposed calvarium. ADM has been shown to facilitate vascularization over native and exposed structures to help create a vigorous bed of granulation tissue. [16] In this case, applying Integra with NPWT served the additional purpose of building a base of tissue that would disguise any surface irregularities.

The authors believe that salvaging the galea during serial provided the best opportunity for successful grafting. Alternatively, removing the galea and bur-

ring down the entire skull before utilizing Integra and STSGs would have provided no additional chance of successful coverage. The galea additionally increased the scalp's thickness, providing more protection from subsequent trauma. Using Integra for coverage of an entire scalp may seem cost prohibitive but having a more potent bed of tissue to graft on increases the chances of successfully taking STSGs.

In this case, the authors hope to show the importance of always considering scalp replantation even in the setting of polytrauma. If the replantation fails, the galea could still survive, providing vascularized tissue that readily accepts STSGs.

### Ethical Statement

All procedures followed were in accordance with the ethical standards of the responsible committee on human experimentation (institutional and national) and with the Helsinki Declaration of 1975, as revised in 2008 (5). Informed consent was obtained from all patients for being included in the study. Additional informed consent was obtained from all patients for which identifying information is included in this article.

### Conflicts of Interest

The authors declare no conflicts of interest regarding the publication of this paper.

### References

- [1] Wynn, S.K. (1951) Free Pattern Skin Graft in Total Scalp Avulsion. *Plastic and Reconstructive Surgery* (1946), **7**, 225-236. <https://doi.org/10.1097/00006534-195103000-00004>
- [2] Whalen, W.P. (1957) Avulsion of the Scalp. *Plastic and Reconstructive Surgery* (1946), **19**, 225-228. <https://doi.org/10.1097/00006534-195703000-00006>
- [3] Robinson, F. (1952) Complete Avulsion of the Scalp. *British Journal of Plastic Surgery*, **5**, 37-50. [https://doi.org/10.1016/S0007-1226\(52\)80005-0](https://doi.org/10.1016/S0007-1226(52)80005-0)
- [4] Pandya, N.J., Gupta, J.L., Bhatnagar, S.K. and Srivastava, J.L. (1977) Avulsion Injury of the Scalp. *Plastic and Reconstructive Surgery*, **59**, 448. <https://doi.org/10.1097/00006534-197703000-00035>
- [5] Jeremiah, B.S. (1971) Avulsion of the Scalp and Its Reconstruction. *Plastic and Reconstructive Surgery*, **48**, 604. <https://doi.org/10.1097/00006534-197112000-00024>
- [6] Dickson, L., Kattan, A. and Thoma, A. (2010) Two-Technique Reconstruction Following Traumatic Scalp Avulsion: Replantation and Composite Graft. *Plastic and Reconstructive Surgery*, **125**, 151e-152e. <https://doi.org/10.1097/PRS.0b013e3181d45b69>
- [7] Miller, G.D., Anstee, E.J. and Snell, J.A. (1976) Successful Replantation of an Avulsed Scalp by Microvascular Anastomoses. *Plastic and Reconstructive Surgery*, **58**, 133-136. <https://doi.org/10.1097/00006534-197608000-00001>
- [8] Fijalkowska, M. and Antoszewski, B. (2018) Complications after Scalp Suturing Post-traumatic Avulsion. *Journal of Craniofacial Surgery*, **29**, e670-e672. <https://doi.org/10.1097/SCS.0000000000004764>

- [9] Cen, H., Jin, R., Yu, M. and Weng, T. (2021) Clinical Decision Model for the Reconstruction of 175 Cases of Scalp Avulsion/Defect. *American Journal of Otolaryngology*, **42**, Article ID: 102752. <https://doi.org/10.1016/j.amjoto.2020.102752>
- [10] Anbar, R.A., et al. (2012) Scalp Reconstruction Prodedures. *Revista Brasileira de Cirurgia Plástica*, **27**, 156-159. <https://doi.org/10.1590/S1983-51752012000100026>
- [11] Dadaci, M., Yildirim, M.E.C. and Ince, B. (2019) Experience of Replantation and Reconstruction in Total Scalp, Partial Forehead, and Ear Avulsions. *Journal of Craniofacial Surgery*, **30**, 2268-2270. <https://doi.org/10.1097/SCS.0000000000005993>
- [12] Kalra, G.S., Goil, P. and Chakotiya, P.S. (2013) Microsurgical Reconstruction of Major Scalp Defects Following Scalp Avulsion. *Indian Journal of Plastic Surgery*, **46**, 486-492. <https://doi.org/10.4103/0970-0358.121984>
- [13] Kashyap, N., Singhal, M., Tiwari, R., Chauhan, S. and Manas, R. (2020) Scalp Avulsion Injuries and Replantation: Is Deep Temporal Artery an Alternate Option? *Annals of Plastic Surgery*, **84**, 178-182. <https://doi.org/10.1097/SAP.0000000000002005>
- [14] Jennings, M., Willet, J., Cook, S., Harbison, J., Caplash, Y. and Solanki, N.S. (2021) Total Scalp Avulsion: Practical Tips for Successful Replantation. *ANZ Journal of Surgery*, **92**, 880-881. <https://doi.org/10.1111/ans.17148>
- [15] Liu, C. and Liao, N. (2003) Treatment of Overtime Avulsion of Scalp with Split Thickness Scalp Skin Grafting: 7 Cases of Reports. *Chinese Journal of Reparative and Reconstructive Surgery*, **17**, 388-390.
- [16] Iorio, M.L., Shuck, J. and Attinger, C.E. (2012) Wound Healing in the Upper and Lower Extremities: A Systematic Review on the Use of Acellular Dermal Matrices. *Plastic and Reconstructive Surgery*, **130**, 232S-241S. <https://doi.org/10.1097/PRS.0b013e3182615703>