





The Diagnostic Value of Metagenomic Next-Generation Sequencing in *Angiostrongylus cantonensis* Encephalitis/Meningitis

Xiaowei Fan^{1*} , Qiang Wang^{1*} , Peiqing Li¹ , Bin Ai² , Yongling Song¹ , Qiuyan Peng¹, Hongli Wang^{3#} 

¹Pediatric Emergency Department, Guangzhou Women and Children's Medical Center, Guangzhou Medical University, Guangzhou, China

²Pediatric Radiology Department, Guangzhou Women and Children's Medical Center, Guangzhou Medical University, Guangzhou, China

³Pediatric Gastroenterology Department, Guangzhou Women and Children's Medical Center, Guangzhou Medical University, Guangzhou, China

Email: *WHL18198903630@163.com

How to cite this paper: Fan, X.W., Wang, Q., Li, P.Q., Ai, B., Song, Y.L., Peng, Q.Y. and Wang, H.L. (2021) The Diagnostic Value of Metagenomic Next-Generation Sequencing in *Angiostrongylus cantonensis* Encephalitis/Meningitis. *Journal of Behavioral and Brain Science*, 11, 216-226.
<https://doi.org/10.4236/jbbs.2021.119017>

Received: August 25, 2021

Accepted: September 20, 2021

Published: September 23, 2021

Copyright © 2021 by author(s) and Scientific Research Publishing Inc. This work is licensed under the Creative Commons Attribution International License (CC BY 4.0).
<http://creativecommons.org/licenses/by/4.0/>



Open Access

Abstract

Objective: *Angiostrongylus cantonensis* (*A. cantonensis*) is an important parasite, which causes neurological infection in children, and is generally difficult to diagnose. We analyzed the significance of metagenomic next-generation sequencing in diagnosing *A. cantonensis* encephalitis/meningitis in children to provide a reference for clinical diagnosis. **Methods:** The case collection of *A. cantonensis* encephalitis/meningitis was from July 2018 to August 2020. The patients' clinical characteristics and pathogen were described, and diagnostic sensitivity methods for *A. cantonensis* encephalitis/meningitis were compared and analyzed, including parasite antibody detection and metagenomic next-generation sequencing (mNGS) detection in different samples. **Results:** Eleven cases were diagnosed with *A. cantonensis* encephalitis/meningitis, including six males (54.5%) and five females (45.5%), and the age ranged from 1 to 13 years with a median of 21 months (IQR: 15.6, 96). All patients were undiagnosed upon admission, of which ten cases had neurological symptoms or signs, six cases (54.5%) had a history of definite or suspicious exposure to parasites, and eight cases (72.7%) had abnormal changes in cranial MRI. The results of *A. cantonensis* antibodies in the peripheral blood and cerebrospinal fluid (CSF) were compared with CSF's metagenomic next-generation sequencing (mNGS). The antibody-positive rate of peripheral blood was 54.5%,

*These authors contributed equally to this work.

#Corresponding author.

CSF antibody-positive rate was 27.2%, and mNGS-positive rate of CSF was 81.8%, and the positive diagnostic rate of the latter was significantly higher than the former two ($p = 0.035 < 0.05$ and $p = 0.030 < 0.05$, respectively). **Conclusion:** Metagenomic next-generation sequencing has a higher positive rate for diagnosing infection and plays an important role in clarifying diagnosis and reducing misdiagnosis.

Keywords

Angiostrongylus cantonensis Encephalitis, Meningitis, Diagnosis, Metagenomic Next-Generation Sequencing

1. Introduction

Angiostrongylus cantonensis is parasites prevalent in Southeast Asia and the Pacific Ocean. Humans can be infected by ingesting uncooked intermediate hosts, such as snails, crabs, freshwater shrimp, frogs, and certain fishes, or through contact with soil or water sources contaminated by parasites [1]. It can develop into stage IV and stage V larvae in the human host but not into adults. Its larvae are neurotrophic and migrate to the nervous tissue after infecting the human body, which can cause acidophilic meningitis, but can also cause encephalitis, encephalomyelitis, and even eye involvement [2].

The diagnosis of *A. cantonensis* encephalitis/meningitis is mainly based on epidemiological history, clinical manifestations, cerebrospinal fluid acidophilia, and immune examination. The gold standard for diagnosis is the discovery of *A. cantonensis* in CSF. However, it is usually difficult. Although antibody detection of serum and CSF are the most commonly used clinical diagnostic methods, they both lack sensitivity [3]. Alternatively, the clinical metagenomic next-generation sequencing (mNGS) has developed rapidly in recent years and has played an important role in the accurate diagnosis of infectious diseases. The mNGs technique is advantageous because there is no need to preset, cultivate, and no preferences; results are obtained by extracting the sum of all microbial genetic material (DNA and RNA) from clinical specimens, constructing a library, and analyzing by high-throughput sequencing and suitable bio-informatics algorithms; and it is fast and has comprehensive identification of all types of microorganisms (bacteria, fungi, viruses, parasites, etc.) detection technology [4]. It is also extremely competitive in the pathogenic diagnosis of the most difficult-to-diagnose cases or immunocompromised patients [4].

Although the infection of *A. cantonensis* is uncommon, it can usually cause severe clinical manifestations and neurological sequelae. Due to the low positive rate of pathogenic diagnosis, the clinical treatment of the disease could be delayed or even missed, which increases the risk of deterioration and sequelae. Here, we study children with *A. cantonensis* encephalitis/meningitis in the past three

years and compared the sensitivity and specificity of different diagnostic methods to provide a clinical diagnostic reference.

2. Patients and Methods

Clinical data

This is a retrospective study of patients diagnosed with *A. cantonensis* encephalitis/meningitis in Guangzhou Women and Children's Medical Center from July 2018 to August 2020, who were undiagnosed upon admission. The diagnosis meets the following criteria [5]: 1) a clear epidemiological history; 2) clear infection, mainly symptoms of CNS infection; 3) eosinophil elevation in cerebrospinal fluid by more than 10%; 4) pathogen examination: larvae, *A. cantonensis* antibody positive in serum or cerebrospinal fluid. Comprehensive assessment of the appeal of four criteria, while excluding infection from other causes. All patients were treated with albendazole combined with low-dose glucocorticoids [6].

Methods

The clinical data for all included cases were recorded, including demographic features, clinical manifestations, laboratory and imaging results, treatments, and outcomes. *A. cantonensis* antibodies in peripheral blood and CSF were tested by Guangzhou Golden Field Medical Laboratory Co., Ltd. Cerebrospinal fluid mNGS were tested by Shenzhen MGI Technology Co., Ltd.

Statistical analysis

Statistical analysis was conducted using SPSS v.26.0 (IBM, Armonk, NY, USA). Categorical variables are described as n (%). Continuous variables with normal distribution are expressed as mean \pm standard deviation (SD). Continuous variables with non-normal distribution are expressed as the median (interquartile range, IQR). Use the χ^2 test to compare differences between groups. The bilateral *p*-value < 0.05 is considered statistically significant.

3. Results

Characteristics of cases

A total of 11 patients were diagnosed with *A. cantonensis* encephalitis/meningitis in Guangzhou Women and Children's Medical Center from July 2018 to August 2020, whose clinical data were collected. All of them were undiagnosed upon admission, including six males (54.5%) and five females (45.5%), and the age ranged from 1 to 13 years with a median of 21 months (IQR: 15.6, 96). Among them, one case (9.1%) had a clear history of raw snail-eating, three cases (27.3%) had edible shrimp and oysters, two cases (18.2%) had contact with field water sources, and five cases (45.5%) had no obvious exposure history of the parasite. Among them, nine cases (81.8%) had fever and vomiting, five cases (45.5%) had a headache, one case (9.1%) had convulsions, and five cases (45.5%) had mental changes. The interval between onset and definite diagnosis was 5 - 102 d, with a median of 26 d (IQR: 20, 38). The total length of hospital stay was 17 - 92 d, with

a median of 27 d (IQR: 18, 39) (see **Table 1**).

General laboratory results

After admission, the peripheral blood leukocytes were $11.5 \pm 4.3 \times 10^9/L$, and eosinophils were $1.8 \pm 1.3 \times 10^9/L$. Lumbar puncture showed that CSF pressure range was 250 to over 330 mmH₂O, CSF leukocytes were $426 \pm 194 \times 10^6/L$, the ratio of eosinophils to leukocytes was 0% - 50% (median 10%, IQR: 1%, 19%), CSF protein was 0.66 ± 0.26 g/L, and the glucose concentration was 2.32 ± 0.94 mmol/L (see **Table 2**). Thus, there were eight cases (72.7%) of eosinophilia in cerebrospinal fluid, which met the standard of eosinophilic meningitis (eosinophilic meningitis is defined by the presence of ten or more eosinophils/ μ L in the CSF or eosinophilia of at least 10% CSF leukocyte count [7]).

Imaging and neurophysiology

A chest X-ray in all patients, found four cases (36.4%) were normal, 7 cases (63.6%) had a lung infection, and one (9.1%) had lung consolidation. All patients underwent head magnetic resonance imaging (MRI) examination, and eight positive

Table 1. Patients characteristics.

Case	Sex	Age (m)	epidemiological history	Symptoms of onset	Accompanying symptoms	The time from onset to diagnosis (d)	Hospital stays (d)
1	F	28	-	Fever, vomiting, headache	Change in mental status	5	46
2	M	84	Poached Prawns	Fever, vomiting, headache	-	28	18
3	F	16	-	Fever, vomiting,	Lethargy, dysphoria	38	28
4	M	132	Eat raw river snail	Vomiting, headache	blurred vision	22	26
5	M	96	Eat oysters	Vomiting, headache	-	13	18
6	M	16	Eat oysters	Fever, vomiting	-	31	27
7	M	156	Play in a pond outdoors	Fever, headache	-	26	17
8	M	21	-	Fever, vomiting	Seizure, Change in mental status	102	92
9	F	15	Play in a ditch outdoors	Fever, vomiting	Change in mental status	20	39
10	F	21	-	Fever	-	38	27
11	F	17	-	Fever, vomiting	Change in mental status	24	29

Table 2. General laboratory results.

Case	PB leukocyte ($\times 10^9/L$)	PB Eosnophils ($\times 10^9/L$)	CSF pressure (mmH ₂ O)	CSF leukocyte ($\times 10^6/L$)	CSF Eosnophils (%)	CSF protein (g/L)	CSF glucose (mmol/L)	PB Angiostrongylus- induced antibodies	CSF Angiostrongylus- induced antibodies	CSF mNGS
1	11.3	1.70	>330	313	5	0.52	3.58	+	-	1
2	12.9	2.58	250	414	0	0.82	2.81	+	+	1004
3	7.2	1.22	/	80	0	0.41	2.08	-	-	377
4	11.1	1.67	320	481	10	0.61	2.5	-	-	213
5	13.6	1.22	>330	868	10	0.45	3.03	-	-	934
6	9.3	0.93	280	331	1	0.92	0.88	-	-	15630
7	6.9	1.10	>330	419	50	0.53	3.14	+	+	16798
8	9.4	1.88	300	331	22	1.2	1.49	-	-	2424
9	10	0.7	300	388	19	0.35	3.31	+	-	1
10	12.3	1.85	280	480	10	0.83	1.49	+	-	1041
11	11.9	5.50	/	586	10	0.6	1.31	+	+	1664
Reference value	5 - 12	0.025 - 0.6	<280	0-5		0.15 - 0.45	2.8 - 4.2			
Mean	11.5	1.8		426		0.66	2.32			
SD	4.3	1.3		194		0.26	0.94			

Note: PB, peripheral blood; CSF, cerebrospinal fluid; mNGS, metagenomic next-generation sequencing; /, not available; +, positive; -, negative; SD, Standard Deviation.

cases (72.7%) were found, including meningitis changes and abnormal reinforcement of brain parenchymal (see **Table 3**, **Figure 1**, **Figure 2**). Except for seven cases (63.6%) with normal electroencephalogram (EEG), one case (9.1%) showed slow background activity and a large amount of 3.5 - 5 hz slow-wave burst in each lead, and three cases (27.3%) showed boundary EEG changes with increased slow background activity.

Diagnostic test

The results of *A. cantonensis* in peripheral blood and cerebrospinal fluid (CSF) were compared with the metagenomic next-generation sequencing (mNGS) of CSF. The antibody-positive rate of peripheral blood was 54.5% (6/11), CSF antibody-positive rate was 27.2% (3/11), and mNGS-positive rate of CSF was 81.8% (9/11), and the positive diagnostic rate of the latter was significantly higher than the former two ($p = 0.035 < 0.05$ and $p = 0.030 < 0.05$, respectively) (see **Table 4**), and after the treatment, it was found that the mNGS reads in the CSF decreased, indicating the anti-*A. cantonensis* treatment was effective (see **Figure 3**).

Treatment and prognosis

The patients were given empirical antibiotic treatment and completed pathogenic sampling and testing after admission. After the diagnosis was confirmed, albendazole (20 mg/kg-d * 10 d, 2 courses) combined with low-dose methylprednisolone (0.2 mg/kg-d * 5 - 10 d) treatment were conducted. Except for one

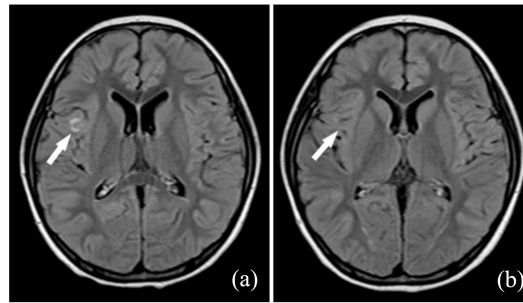


Figure 1. Case 2 MRI. A 1.4-year-old girl with fever and headache for three weeks. (a) Contrast-enhanced MRI T2WI-FLAIR sequence showed a linear abnormal signal focus on the surface of the cerebral gyrus; (b) After the treatment, the lesions disappeared

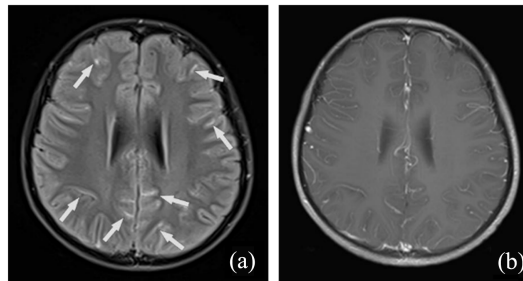


Figure 2. Case 4 MRI. An 11-year-old boy with vomiting and headache for two weeks. (a) MR enhanced T2WI-FLAIR sequence showed multiple linear enhancement of the pia mater with meningitis; (b) It is difficult to distinguish the meningeal enhancement with enhanced T1WI sequence from the blood vessels on the brain surface, so it is difficult to show lesions in the T1WI sequence.

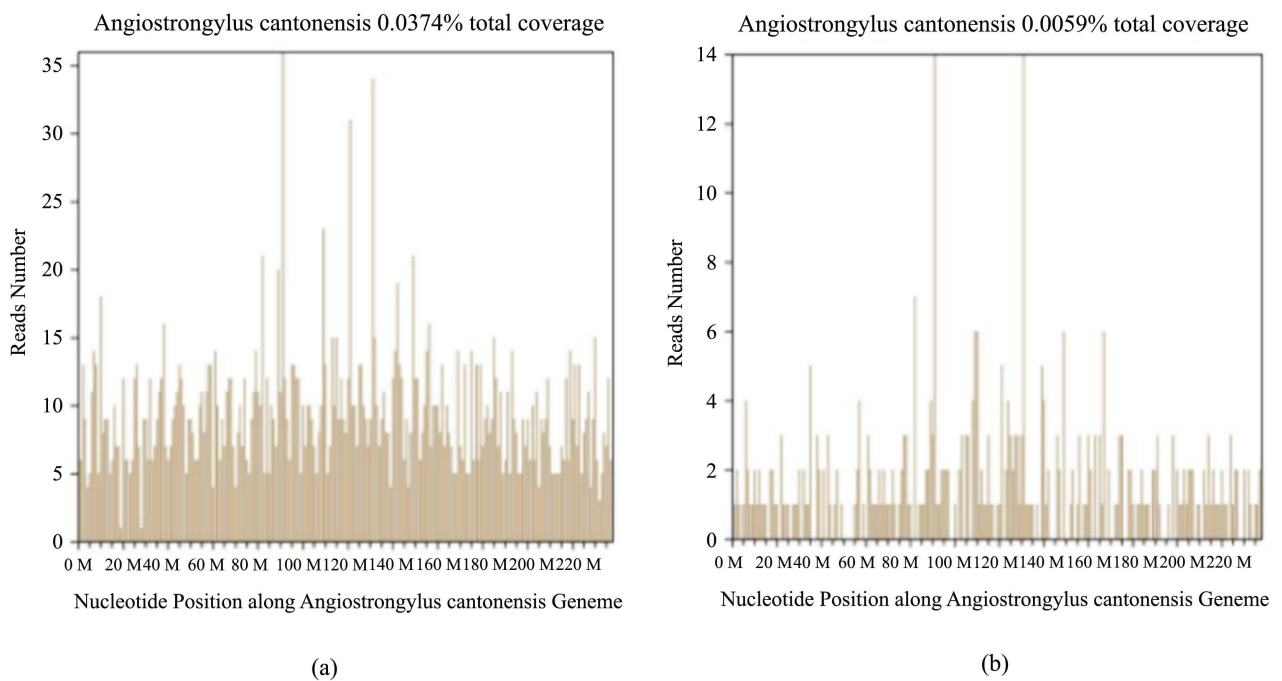


Figure 3. Next-generation sequencing (NGS) of *Angiostrongylus cantonensis* in Case 5's cerebrospinal fluid. (a) NGS showed 934 reads corresponding to the *Angiostrongylus cantonensis*, with coverage of 0.0374%; (b) The re-examination of NGS 5 d later showed 147 reads corresponding to the *Angiostrongylus cantonensis*, with coverage of 0.0059%.

Table 3. Imaging and neurophysiology results.

Case	Chest X-ray	Brain MRI	EEG
1	lung infection	-	increased slow background activity
2	-	abnormal reinforcement of the frontal lobe and occipital lobe	increased slow background activity
3	lung infection	-	-
4	-	leptomeninges enhancement	-
5	-	leptomeninges enhancement	increased slow background activity
6	lung infection	focal nodular enhancement of bilateral cerebellar and cerebral meninges	-
7	-	punctate abnormal enhancement of vermis	-
8	lung infection	-	a large amount of 3.5 - 5 Hz slow wave bursts in each lead
9	lung infection	leptomeninges enhancement	-
10	lung infection	multiple abnormal signals in left cerebellar, bilateral occipital lobe, frontal lobe and left temporal lobe	-
11	lung infection and consolidation	multiple small nodular lesions in right frontal lobe, occipital lobe, temporal lobe and left parietal lobe	-

Note: MRI, magnetic resonance imaging; EEG, electroencephalogram; -, normal.

Table 4. Comparison of positive rate of diagnostic test methods.

Testing method	Positive rate (%)	<i>P</i>
PB <i>Angiostrongylus</i> -induced antibodies	54.5%	0.030a*
CSF <i>Angiostrongylus</i> -induced antibodies	27.2%	0.035b*
CSF mNGS	81.8%	

Note: PB, peripheral blood; CSF, cerebrospinal fluid; mNGS, metagenomic next-generation sequencing; a, compared with PB *Angiostrongylus*-induced antibodies-positive rate and CSF mNGS; b, compared with CSF *Angiostrongylus*-induced antibodies positive rate and CSF mNGS; **p* < 0.05.

case lost to follow-up, the remaining 10 cases were followed up for 3 months to half a year after discharge, and no sequelae were left.

4. Discussion

A. cantonensis is a zoonotic pathogen. In the past 20 years, there have been local outbreaks or occasional cases [8] [9] [10]. The basis for the diagnosis of finding the larvae from the cerebrospinal fluid is difficult. Simultaneously, neither clinical manifestations nor cerebrospinal fluid with increased eosinophils are specific for diagnosis. Although advances in immunological technology have improved

the diagnostic rate of parasitic infections, this technology is still insufficient for diagnosis *A. cantonensis* encephalitis [11]. It usually takes a long time to identify *A. cantonensis* infection, with a median of 26 d in our study. This not only aggravates illness, but also increases the family economic burden. Therefore, it is necessary to find a simple sampling detection method with high diagnostic specificity, and our research found that CSF mNGS is a good alternative.

Since children often like to play with water and soil, once contaminated by *A. cantonensis*, they can accidentally be infected. Among the study cases in this group, four cases had a history of eating snails, shrimp, or oysters, and two cases had water exposure in the wild, and the remaining five cases failed to trace a suspicious epidemiological contact history and could not provide help in diagnosis. *A. cantonensis* infection with neurological involvement is more common [2]. In this study, except for one case with fever of unknown origin, ten patients had different neurological symptoms or signs, the most common was headache (45.5%), complained by older children mainly, followed by muscle weakness (21%) and convulsions (9%). Although vomiting occurred in nine cases (81.8%), it might be a nonspecific neurological symptom. Because children cannot clearly describe personal feelings, such as headaches, and activity trajectories, the feasibility of assisting diagnosis through epidemiological history and neurological symptoms is reduced.

A. cantonensis is one of the important pathogen causing eosinophilic meningitis [12], and the increase in eosinophils in CSF is also an important clue for *A. cantonensis* encephalitis/meningitis. Previous studies have shown that 71% of patients have elevated eosinophils in the cerebrospinal fluid [13], while eight cases (72.7%) increased eosinophils in CSF in our study. However, it has also been reported that only 4% of cases had elevated eosinophils in CSF in the early course of the disease [13], which is not a unique indicator of *A. cantonensis* encephalitis/meningitis needing ruled out other causes such as other pathogens infections and brain tumors.

Head magnetic resonance imaging (MRI) can find abnormal signals, including multiple nodular enhancement lesions and linear enhancement of the pia mater, which are common in the brain [14] [15]. In our study, five cases (45.5%) showed multinodular enhancement of brain lesions, and three cases (27.3%) showed leptomeningeal enhancement. Although neuroangiostrongyliasis cannot be diagnosed by brain MRI, but may have suggestive, and contribute to other causes of eosinophilic meningitis excluded.

Finding pathogens in human tissues, secretions, and excrement is the basis for diagnosis parasitic infection. However, it is more challenging to detect *A. cantonensis* directly from the central nervous system (CNS) to confirm the CNS *A. cantonensis* infection. In contrast, immunological diagnosis methods are relatively feasible, which were used in our study and found that the positive rates of *A. cantonensis* antibodies in serum and CSF were 54.5% and 27.2%, respectively. In another aspect of the diagnostic technique, the CSF mNGS-positive rate exceeds 80% in our study, which is significantly higher than immunization me-

thods. The patients have a good prognosis by targeted treatment. Metagenomic next-generation sequencing (mNGS) has greatly increased the pathogen detection rate of central nervous system infections [16-18]. Additionally, pathogens of mixed infections in CNS can be found more comprehensively by mNGS, especially in patients with a long course of the disease and low immunity, simultaneously, the therapeutic effect can be evaluated by monitoring the reads [18]. Miao *et al.* suggest that mNGS could yield higher sensitivity for early identification of fastidious and time-consuming microbes (*e.g.*, *Mycobacterium tuberculosis*, virus, anaerobe, and fungus) [19]. Our study confirmed that mNGS also has a high sensitivity in the diagnosis of parasitic infection. Presently, the mNGS technology is not widely used in clinical practice due to its high cost of testing, however, a clear early diagnosis, followed by targeted treatment in exchange for lower hospital stay, costs and sequelae rate, and comprehensive cost performance might be more beneficial to patients.

5. Conclusion

Compared with epidemiological history, elevated eosinophils, antibody immune detection, and brain MRI examination, CSF mNGS technology can obtain a higher positive diagnosis rate in children with *A. cantonensis* encephalitis/meningitis, which not only helps find the CNS pathogens earlier and comprehensively, but also evaluate the efficacy of treatment, and its clinical value is worthy of promotion.

6. Limitations

This study still has some limitations. First of all, this is a retrospective single-center study with a limited number of children. Additionally, due to the limitation of testing costs, it was impossible to conduct a re-examination of CSF mNGS in all patients. Its clinical promotion requires further technical improvement and reduction in testing costs.

Conflicts of Interest

All authors declare no conflict of interest.

Funding Information

This study was supported by the Innovative Project of Children's Research Institute, Guangzhou Women and Children's Medical Center, China (No. NKE-PRE-2019-015).

References

- [1] Barratt, J., Chan, D., Sandaradura, I., Malik, R., Spielman, D., Lee, R., Marriott, D., Harkness, J., Ellis, J. and Stark, D. (2016) *Angiostrongylus cantonensis*: A Review of Its Distribution, Molecular Biology and Clinical Significance as a Human Pathogen. *Parasitology*, **143**, 1087-1118. <https://doi.org/10.1017/S0031182016000652>
- [2] Martins, Y.C., Tanowitz, H.B. and Kazacos, K.R. (2015) Central Nervous System

- Manifestations of *Angiostrongylus cantonensis* Infection. *Acta Tropica*, **141**, 46-53. <https://doi.org/10.1016/j.actatropica.2014.10.002>
- [3] Logan, E., Chetty, A. and Horsnell, W.G. (2014) The Role of Antibody in Parasitic Helminth Infections. *Advances in Experimental Medicine and Biology*, **828**, 1-26. https://doi.org/10.1007/978-1-4939-1489-0_1
- [4] Chiu, C.Y. and Miller, S.A. (2019) Clinical Metagenomics. *Nature Reviews Genetics*, **20**, 341-355. <https://doi.org/10.1038/s41576-019-0113-7>
- [5] Finsterer, J. and Auer, H. (2013) Parasitoses of the Human Central Nervous System. *Journal of Helminthology*, **87**, 257-270. <https://doi.org/10.1017/S0022149X12000600>
- [6] Sawanyawisuth, K. and Sawanyawisuth, K. (2008) Treatment of Angiostrongyliasis. *Transactions of the Royal Society of Tropical Medicine and Hygiene*, **102**, 990-996. <https://doi.org/10.1016/j.trstmh.2008.04.021>
- [7] Kuberski, T. (1981) Eosinophils in Cerebrospinal Fluid: Criteria for Eosinophilic Meningitis. *Hawaii Medical Journal*, **40**, 97-98.
- [8] Nalini, A., Ramakrishna, A., Dekumoy, P., Kumar, R.R., Pakdee, W., Saini, J. and Hegde, V.S. (2013) Severe Form of Radiculo-Myelo-Neuropathy with Meningo-Encephalitis Secondary to *Angiostrongylus cantonensis* Infection: Unusual Corpus Callosal Lesions and Serial Magnetic Resonance Imaging Findings. *Neurology India*, **61**, 414-418. <https://doi.org/10.4103/0028-3886.117613>
- [9] Cattaneo, C., Hoarau, M., Valois, S., Chamouine, A., Dembele, Y., Collet, L. and Sartton, R. (2021) Tetraventricular Hydrocephalus Following Eosinophilic Meningitis Due to *Angiostrongylus cantonensis* in a 14-Month-Old Boy from Mayotte: A Case Report. *Open Forum Infectious Diseases*, **8**, ofab031. <https://doi.org/10.1093/ofid/ofab031>
- [10] Wang, Q.P., Wu, Z.D., Wei, J., Owen, R.L. and Lun, Z.R. (2012) Human *Angiostrongylus cantonensis*: An Update. *European Journal of Clinical Microbiology & Infectious Diseases*, **31**, 389-395. <https://doi.org/10.1007/s10096-011-1328-5>
- [11] Eamsobhana, P. and Yong, H.S. (2009) Immunological Diagnosis of Human Angiostrongyliasis Due to *Angiostrongylus cantonensis* (Nematoda: Angiostrongylidae). *International Journal of Infectious Diseases*, **13**, 425-431. <https://doi.org/10.1016/j.ijid.2008.09.021>
- [12] Graeff-Teixeir, C., da Silva, A.C. and Yoshimura, K. (2009) Update on Eosinophilic Meningoencephalitis and Its Clinical Relevance. *Clinical Microbiology Reviews*, **22**, 322-348. <https://doi.org/10.1128/CMR.00044-08>
- [13] Punyagupta, S., Juttijudata, P. and Bunnag, T. (1975) Eosinophilic Meningitis in Thailand. Clinical Studies of 484 Typical Cases Probably Caused by *Angiostrongylus cantonensis*. *American Journal of Tropical Medicine and Hygiene*, **24**, 921-931. <https://doi.org/10.4269/ajtmh.1975.24.921>
- [14] Jin, E., Ma, D., Liang, Y., Ji, A. and Gan, S. (2005) MRI Findings of Eosinophilic Myelomeningoencephalitis Due to *Angiostrongylus cantonensis*. *Clinical Radiology*, **60**, 242-250. <https://doi.org/10.1016/j.crad.2004.05.012>
- [15] Yang, B., Yang, L., Chen, Y. and Lu, G. (2019) Magnetic Resonance Imaging Findings and Clinical Manifestations in Cerebral Angiostrongyliasis from Dali, China. *Brain and Behavior*, **9**, e01361. <https://doi.org/10.1002/brb3.1361>
- [16] Lloyd-Price, J., Abu-Ali, G. and Huttenhower, C. (2016) The Healthy Human Microbiome. *Genome Medicine*, **8**, 51. <https://doi.org/10.1186/s13073-016-0307-y>
- [17] Schlaberg, R., Chiu, C.Y., Miller, S., Procop, G.W., Weinstock, G., Professional Prac-

tice C, Committee on Laboratory Practices of the American Society for M, Microbiology Resource Committee of the College of American P (2017) Validation of Metagenomic Next-Generation Sequencing Tests for Universal Pathogen Detection. *Archives of Pathology & Laboratory Medicine*, **141**, 776-786.

<https://doi.org/10.5858/arpa.2016-0539-RA>

- [18] Guo, L.Y., Li, Y.J., Liu, L.L., Wu, H.L., Zhou, J.L., Zhang, Y., Feng, W.Y., Zhu, L., Hu, B., Hu, H.L., *et al.* (2019) Detection of Pediatric Bacterial Meningitis Pathogens from Cerebrospinal Fluid by Next-Generation Sequencing Technology. *Journal of Infection*, **78**, 323-337. <https://doi.org/10.1016/j.jinf.2018.12.001>
- [19] Miao, Q., Ma, Y., Wang, Q., Pan, J., Zhang, Y., Jin, W., Yao, Y., Su, Y., Huang, Y., Wang, M., *et al.* (2018) Microbiological Diagnostic Performance of Metagenomic Next-Generation Sequencing When Applied to Clinical Practice. *Clinical Infectious Diseases*, **67**, S231-S240. <https://doi.org/10.1093/cid/ciy693>