

# Angiomatous Meningioma Presenting with Depression: A Case Report and Literature Review

Masharib Bashar<sup>1</sup>, Wafa Sohail<sup>1</sup>, Marium Khan<sup>1</sup>, Uzair Yaqoob<sup>2\*</sup>

<sup>1</sup>Civil Hospital, Karachi, Pakistan

<sup>2</sup>Dow University of Health Sciences, Karachi, Pakistan

Email: \*ozair\_91393@hotmail.com

**How to cite this paper:** Bashar, M., Sohail, W., Khan, M. and Yaqoob, U. (2020) Angiomatous Meningioma Presenting with Depression: A Case Report and Literature Review. *Case Reports in Clinical Medicine*, 9, 22-28.

<https://doi.org/10.4236/crcm.2020.91004>

**Received:** December 5, 2019

**Accepted:** December 30, 2019

**Published:** January 2, 2020

Copyright © 2020 by author(s) and Scientific Research Publishing Inc. This work is licensed under the Creative Commons Attribution International License (CC BY 4.0).

<http://creativecommons.org/licenses/by/4.0/>



Open Access

## Abstract

Meningiomas are classified into three types according to the World Health Organization classification system which is based on morphologic criteria. Type 1 is the benign variant, in which meningothelial is the most common subtype. Angiomatous also belongs to the same subtype but comprises only 2.1% of all meningiomas. Although most meningiomas are asymptomatic, some may present with varying symptoms ranging from seizures to focal deficits. Often, large meningiomas can also manifest as neuropsychiatric symptoms ranging from depression to overt psychosis. Here, in this case, we have further elaborated the importance of the organic cause of psychiatric symptoms as our patient initially presented with symptoms of depression. Regarding the diagnosis of meningiomas, nowadays excellent neuro-imaging methods are available, however, histological examination and immunohistochemistry remain the gold standard tools for a definite diagnosis. In our patient, the histological examination showed well-formed sinusoids and vascular channels which were consistent with the diagnosis of an angiomatous variant. Gross total resection of the lesion remains the treatment of choice with radiation therapy being used for residual tumors postoperatively. Being a type 1 variant, these meningiomas have a very small risk of recurrence. Here, we have presented a rare variant of meningioma initially presenting with prominent psychiatric symptoms of depression advancing to focal deficits.

## Keywords

Meningioma, Angiomatous Meningioma, Depression, Psychiatric Presentation, Oncology, Neurosurgical Tumors

## 1. Introduction

Meningiomas are the common primary tumors of the central nervous system (CNS). There are many variants of meningiomas classified on the basis of morphology according to the World Health Organization (WHO) Classification System. Among the benign types (Type 1 variant), meningothelial is the most common variant. Here we report a case of a very rare variant of benign meningiomas termed as “angiomatous meningioma”, which comprises only 2.1% of all meningiomas [1]. Clinically, meningiomas most commonly present as seizures and neurological deficits, however, our patient presented with neuropsychiatric symptoms [2]. The angiomatous variant, as the name implies, shows extreme vascularity and special preoperative and perioperative measures with regards to the anticipation of major bleeding during surgical resection. Our patient, fortunately, displayed no complications of any sort during the resection of the tumor and showed exceptional postoperative recovery. Gross total resection remains the treatment of choice [1], however, postoperative radiotherapy can be used for residual tumors.

In the following case report, we have aimed to do an extensive literature review with regards to this rare variant and summarize the important points in the discussion that should be kept in mind when dealing with such tumors.

## 2. Case Presentation

A 30-year old married female, resident of Balochistan, housewife by profession, known case of cerebral malaria at the age of 10 years, was admitted via outpatient department to the psychiatry ward of Civil Hospital, Karachi on 11/05/2018 for the complaints of decreased appetite, increased somnolence, fatigability, and anhedonia since six months, weakness (more on right side of her body) accompanied with headache since five months.

According to the patient’s brother, the patient was in her usual state of health seven months back, while she was pregnant for the 5th time. After 10 weeks postpartum, she started complaining of increased tiredness and decreased energy. Her family also noticed that her mood remained persistently low and depressed. 3 - 4 weeks later, she suffered from a single episode of loss of consciousness, after which she was taken to some local spiritual healer, but 1 day later she developed weakness on the right side of her body, for which she took spiritual treatment for 40 days. Since the symptoms of weakness persisted despite the spiritual treatment she was taken to a local hospital, where some undocumented injections were administered and she felt much better, however, the pain persisted. Along with that, the patient started to show problems while walking, with the tendency of continuously falling on the right side of her body, and tremors on her right hand. Upon further inquiring from the patient, she further complained of cold intolerance, weight gain and constipation for the last 3 - 4 months.

The patient also had a positive past history of diagnosed and treated cerebral

malaria at the age of 10 years. Furthermore, she had a positive transfusion history of 3 packed cell volumes (PCV) during her last pregnancy due to severe anemia. There is no addiction history. She has 5 children, all healthy and alive. Her family history is positive for type 2 diabetes mellitus and essential hypertension. There is no family history of any psychiatric illness. Her psychosexual, marital history and past psychiatric history were all insignificant.

Upon admission, her Central nervous system examination had some positive findings. The patient's Glasgow Coma Score was 13/15 and her Mini-Mental State Examination score was 19/30. She looked like a middle-aged patient, of average height and obese built, lying on the bed, with increased drowsiness, dressed appropriately, and well-kempt. Due to her drowsiness, she was not able to sit upright for more than a few minutes and answered most of our questions after putting huge effort, making but not maintaining eye contact. The speech was coherent and relevant, however, tone and volume were low. The mood was also low and affect restricted. No findings of any thought or perceptual disturbances. The patient was oriented to place and person only. Immediate memory was impaired however, recent and remote memory was intact. Attention, concentration, abstract thinking and judgment all were impaired.

Her admission vitals were as follows: blood pressure, 110/80 mmHg (reference, 120/80 mmHg); pulse, 90 bpm (reference, 70 to 100 bpm); respiratory rate, 18 breaths/minute (reference range, 18 to 22); and temperature, 98.6°F (reference, 98.6°F). Her respiratory, cardiovascular and gastrointestinal examinations were all normal.

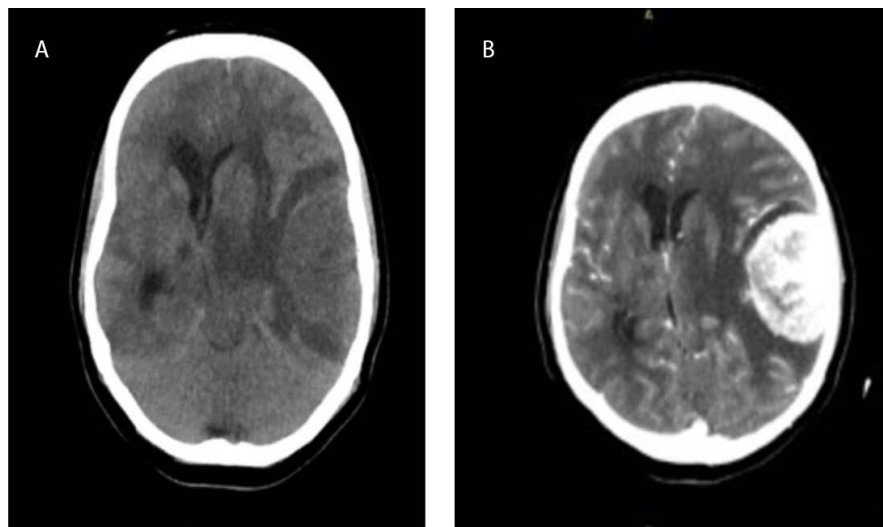
Upper and lower limb motor examination showed bilaterally normal bulk and tone. However, her powers on the right upper and lower limb were 3/5. Deep tendon reflexes were +3 on the right upper and lower limb and +2 on the left upper and lower limbs, respectively. Plantars were up going on a right lower limb while downgoing on the left side. The patient had decreased arm swing on the right side and was moving her right leg in a semicircle fashion. The cerebellar examination was normal, however, finger nose test and dysdiadochokinesia could not be assessed on the right side due to motor deficit. Sensory examination, cranial nerves and signs of meningeal irritation all were negative for any findings.

Based on her history and examination, we made a differential diagnosis of post-natal depression, postpartum psychosis, and organic mental disorder.

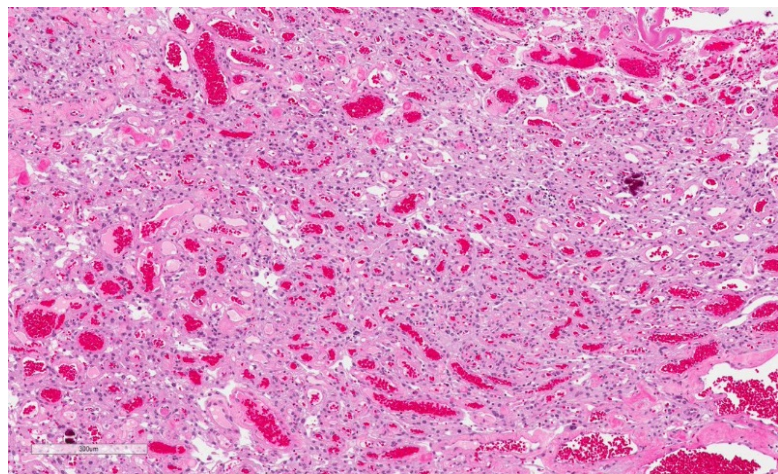
To further evaluate her symptoms, neurology opinion was advised. In addition, an urgent Computed tomography (CT) scan was recommended, along with all the baseline tests as per our hospital protocol for any admission.

Her baseline laboratory parameters which included complete blood profile, blood sugar profile, viral markers, serum electrolytes, renal function tests, PT/INR and liver function tests were all within normal limits. However, her contrast-CT scan of the brain showed a left temporoparietal mass, measuring 8 x 6 cm suggesting a benign meningioma. The lesion was well-circumscribed and

attached to dura without any osseous abnormalities. Peripheral edema around the lesion and midline shift was seen on the CT scan (**Figure 1**). The patient was then shifted to the neurosurgery department, where she underwent left temporo-parietal craniectomy with complete excision of the lesion. Thereafter, duraplasty was done using a periosteal flap. A specimen for biopsy was sent for histopathological diagnosis. The operation went uneventful and the patient did not develop any perioperative or postoperative complications. After about a week of surgery, she was reassessed for previously mentioned psychiatric symptoms, which had resolved completely. The patient was stable and discharged two days later. Her follow-up visit was scheduled after two weeks, where she did not complain of any previous symptoms. Currently, she is on a 6-monthly follow-up. The biopsy report we received showed a definitive diagnosis of angiomatous meningioma with WHO classification of Grade 1 (**Figure 2**).



**Figure 1.** Computed tomography scan presentations of the patient with a plain (A) and contrast sequence (B).



**Figure 2.** Histological presentation showing angiomatous meningioma with the World health organization classification of Grade 1.

### 3. Discussion

Angiomatous meningiomas display some distinct features compared to other benign meningiomas. Epidemiologically, angiomatous meningioma display slightly higher preponderance in males compared to other types of meningioma [3]. In two case series published by Hasselblatt *et al.* and Liu *et al.* both displayed male to female preponderance as 0.73 and 1.08 [1] [3] respectively, while that for all other types of meningioma remains 0.5 [3]. Clinically, these tumors most commonly present as seizures and neurological deficits, as shown in an extensive study by Martin *et al.* [2]. Our patient though presented with prominent psychiatric symptoms of depression and anhedonia, which later on advanced to neurological symptoms limited to the right side of her body. It is not uncommon for these tumors to manifest themselves in the form of psychiatric symptoms initially. 35.1% of meningiomas cause psychiatric symptoms, with frontal and temporal groups displaying the highest frequency [4]. Moreover, any patient with treatment-refractory depression must be worked up for underlying space-occupying lesions in the brain via appropriate imaging modalities.

Histologically, these tumors display a lesser degree of calcification and greater degree peritumoral brain edema compared to other benign meningiomas [1] [5] [6]. On histopathology, these tumors display well-formed sinusoids, capillaries or vascular channels. Martin *et al.* in his study showed two subtypes of this tumor, namely microvascular (in which greater than 50% of vessels had a diameter below 30  $\mu\text{m}$ ) and macrovascular [2]. These tumors may also display microcystic change along with foamy cells (which are related to leakage of plasma lipids across thin vessel walls), in addition to solid areas of meningothelial cells wrapping themselves around small vessels [7]. Radiographically, there are no characteristic features that can distinguish angiomatous from other subtypes of meningioma, however, these types of meningiomas do display significant perilesional edema [8]. It is hypothesized that this is probably due to increased capillary permeability secondary to hypervascularity and increased Vascular endothelial growth factor (VEGF) secretion [1]. This is consistent with magnetic resonance images (MRI) displaying prominent signal voids in angiomatous meningiomas [1] [8]. Other important findings are the homogenous enhancement of the lesion [1] and dural tail sign on MRI [8]. Regarding the dural tail sign, it is probably due to reactive changes in the dura secondary to vascular congestion and edema, which then leads to thickening and enhancement of dura on radiographic imaging.

As with conventional meningiomas, gross total resection is the treatment of choice for angiomatous subtype [1], which was done in our patient as well. Before surgery, it is recommended that cerebral angiography should be performed to identify the feeding artery as the tumor is highly vascular, and if the tumor location is skull base, preoperative embolization should be performed to reduce the blood supply to the tumor [1] [9]. Logically, multiple intravenous lines must be established for rehydration and possible blood transfusion during the opera-

tion. Clear exposure of the tumor is key to a successful operation. In our patient, the surgery went uneventful. Despite the hypervascularity of the tumor, the total blood loss during the operation amounted to 800 mL. There were no perioperative or postoperative complications as discussed in the case above, and the patient's condition remained stable after the operation. Postoperatively, radiation therapy can be used for residual tumors. It has been shown that gamma-knife stereotactic surgery does not increase the probability of malignant transformation of meningiomas [10]. Radiotherapy has an important role in causing tumor shrinkage since it inhibits the expression of VEGF and somatostatin receptors, which causes blood vessel contraction [11]. Multiple studies have proved that radiotherapy reduces the recurrence rates of these tumors [1]. It is prudent to mention that although surgical resection will resolve the psychotic symptoms due to mass effect of tumor, however, one study showed that continued regular screening of these patients must be done for persistent psychiatric or emotional symptoms post-surgically [12]. Depression or burn-out symptoms in the patient's medical history were the most significant risk factors linked to increased cognitive complaints even after tumor resection [12]. More studies should be done, hence, to determine optimum screening intervals in these patients. In our case, we initially followed up the patient two weeks post-surgery and planned to regularly follow the patient every 6-monthly symptomatically, until at least a year after which, modifications will be made, depending on the clinical status of the patient.

Being a WHO Grade 1 tumor, these types of meningiomas usually have a favorable prognosis. The recurrence rates of Grade 1 WHO convexity meningiomas is quite small (0.4%) after complete resection, while one study showed that overall tumor recurrence rates of WHO Grade 1 tumors for Simpson resection Grades I, II, III, and IV were 5%, 22%, 31%, and 35%, respectively [13]. However, it has been seen that preoperative severe depressive symptoms are associated with shorter survival of meningioma patients independently from clinical prognostic indicators [14].

#### 4. Conclusion

In conclusion, we have presented a rare variant of meningioma initially presenting with prominent psychiatric symptoms of depression advancing to focal deficits. It has been seen that the depressive symptoms have been a bad prognostic indicator according to the current literature but our patient is currently doing fine on follow-ups in spite of the fact that no postoperative radiotherapy was required.

#### Conflicts of Interest

The authors declare no conflicts of interest regarding the publication of this paper.

#### References

- [1] Liu, Z., Wang, C., Wang, H., Wang, Y., Li, J.Y. and Liu, Y. (2013) Clinical Character-



- ristics and Treatment of Angiomatous Meningiomas: A Report of 27 Cases. *International Journal of Clinical and Experimental Pathology*, **6**, 695.
- [2] Roser, F., Nakamura, M., Ritz, R., Bellinzona, M., Dietz, K., Samii, M. and Tatagiba, M.S. (2005) Proliferation and Progesterone Receptor Status in Benign Meningiomas Are Not Age Dependent. *Cancer: Interdisciplinary International Journal of the American Cancer Society*, **104**, 598-601. <https://doi.org/10.1136/jcp.2004.018333>
- [3] Hasselblatt, M., Nolte, K.W. and Paulus, W. (2004) Angiomatous Meningioma: A Clinicopathologic Study of 38 Cases. *The American Journal of Surgical Pathology*, **28**, 390-393. <https://doi.org/10.1097/00000478-200403000-00013>
- [4] Bommakanti, K., Gaddamanugu, P., Alladi, S., Purohit, A.K., Chadalawadi, S.K., Mekala, S. and Somayajula, S. (2016) Pre-Operative and Post-Operative Psychiatric Manifestations in Patients with Supratentorial Meningiomas. *Clinical Neurology and Neurosurgery*, **147**, 24-29. <https://doi.org/10.1016/j.clineuro.2016.05.018>
- [5] Kim, B.W., Kim, M.S., Kim, S.W., Chang, C.H. and Kim, O.L. (2011) Peritumoral Brain Edema in Meningiomas: Correlation of Radiologic and Pathologic Features. *Journal of Korean Neurosurgical Society*, **49**, 26. <https://doi.org/10.3340/jkns.2011.49.1.26>
- [6] Whittle, I.R., Smith, C., Navoo, P. and Collie, D. (2004) Meningiomas. *The Lancet*, **363**, 1535-1543. [https://doi.org/10.1016/S0140-6736\(04\)16153-9](https://doi.org/10.1016/S0140-6736(04)16153-9)
- [7] Rathod, G.B., Vyas, K., Shinde, P., Goswami, S.S. and Tandan, R.K. (2014) Angiomatous Meningioma in 49 Years Old Male—A Rare Case Report. *International Journal of Current Microbiology and Applied Sciences*, **3**, 256-260.
- [8] Hwang, J., Kong, D.S., Seol, H.J., Nam, D.H., Lee, J.I. and Choi, J.W. (2016) Clinical and Radiological Characteristics of Angiomatous Meningiomas. *Brain Tumor Research and Treatment*, **4**, 94-99. <https://doi.org/10.14791/btrt.2016.4.2.94>
- [9] Wu, L., Yang, T., Yang, C., Deng, X., Fang, J. and Xu, Y. (2015) Surgical Treatment of Intraspinal Angiomatous Meningiomas from a Single Center. *Neurologia Medico-Chirurgica*, **55**, 328-335. <https://doi.org/10.2176/nmc.oa.2014-0274>
- [10] Rowe, J., Grainger, A., Walton, L., Silcocks, P., Radatz, M. and Kemeny, A. (2007) Risk of Malignancy after Gamma Knife Stereotactic Radiosurgery. *Neurosurgery*, **60**, 60-66. <https://doi.org/10.1227/01.NEU.0000255492.34063.32>
- [11] Nicolato, A., Giorgetti, P., Foroni, R., Grigolato, D., Pasquin, I.P., Zuffante, M., Soda, C., Tomassini, A. and Gerosa, M. (2005) Gamma Knife Radiosurgery in Skull Base Meningiomas: A Possible Relationship between Somatostatin Receptor Decrease and Early Neurological Improvement without Tumour Shrinkage at Short-Term Imaging Follow-Up. *Actaneurochirurgica*, **147**, 367-375. <https://doi.org/10.1007/s00701-005-0483-9>
- [12] van der Vossen, S., Schepers, V.P., van der Sprenkel, J.W.B., Visser-Meily, J. and Post, M.W. (2014) Cognitive and Emotional Problems in Patients after Cerebral Meningioma Surgery. *Journal of Rehabilitation Medicine*, **46**, 430-437. <https://doi.org/10.2340/16501977-1795>
- [13] Nanda, A., Bir, S.C., Maiti, T.K., Konar, S.K., Missios, S. and Guthikonda, B. (2017) Relevance of Simpson Grading System and Recurrence-Free Survival after Surgery for World Health Organization Grade I Meningioma. *Journal of Neurosurgery*, **126**, 201-211. <https://doi.org/10.3171/2016.1.JNS151842>
- [14] Bunevicius, A., Deltuva, V.P. and Tamasauskas, A. (2017) Association of Pre-Operative Depressive and Anxiety Symptoms with Five-Year Survival of Glioma and Meningioma Patients: A Prospective Cohort Study. *Oncotarget*, **8**, 57543-57551. <https://doi.org/10.18632/oncotarget.15743>