

# Long-Term Survival after Resection for Primary Undifferentiated Pleomorphic Sarcoma of the Jejunum with Lymph Node Metastases: Case Report

Shigeru Fujisaki<sup>1,2\*</sup>, Motoi Takashina<sup>1</sup>, Kenichi Sakurai<sup>3</sup>,  
Ryouichi Tomita<sup>4</sup>, Tadatoshi Takayama<sup>2</sup>

<sup>1</sup>Department of Surgery, Fujisaki Hospital, Tokyo, Japan

<sup>2</sup>Division of Digestive Surgery, Nihon University School of Medicine, Tokyo, Japan

<sup>3</sup>Division of Breast and Endocrine surgery, Nihon University School of Medicine, Tokyo, Japan

<sup>4</sup>Department of Surgery, Nippon Dental School at Tokyo, Tokyo, Japan

Email: \*sfujisak@blue.ocn.ne.jp

**How to cite this paper:** Fujisaki, S., Takashina, M., Sakurai, K., Tomita, R. and Takayama, T. (2017) Long-Term Survival after Resection for Primary Undifferentiated Pleomorphic Sarcoma of the Jejunum with Lymph Node Metastases: Case Report. *Journal of Cancer Therapy*, 8, 1079-1085. <https://doi.org/10.4236/jct.2017.812092>

**Received:** September 7, 2017

**Accepted:** December 1, 2017

**Published:** December 4, 2017

Copyright © 2017 by authors and Scientific Research Publishing Inc. This work is licensed under the Creative Commons Attribution International License (CC BY 4.0).

<http://creativecommons.org/licenses/by/4.0/>



Open Access

---

## Abstract

Primary undifferentiated pleomorphic sarcoma (UPS) of the small intestine is extremely rare. The prognosis of UPS is basically poor, and particular, when accompanied with metastatic lesions. This paper reports the case of a long-term survivor of primary UPS of the jejunum with lymph node metastases and a skip lesion in the jejunum. The patient was a 50-year-old Japanese man who presented with a chief complaint of breathlessness. Small bowel X-ray series revealed an approximately 4-cm size with protruded lesion (image shows a filling defect) in the proximal jejunum. Based on a presumptive diagnosis of the hemorrhagic small bowel tumor, he underwent a laparotomy. A tumor was observed in the jejunum at approximately 90-cm from the Treitz ligament; some swollen mesenteric lymph nodules were also observed. Segmental resection of the jejunum was performed 20-140 cm from the Treitz ligament. A complete surgical excision with en-bloc regional lymph node dissection was performed. The final histopathological diagnosis was UPS of the jejunum with metastatic lymph nodes and a skip lesion in the jejunum. The postoperative course was uneventful. The patient was not given adjuvant chemotherapy and was discharged on postoperative day 16. He is currently well without any evidence of recurrence for >10 years after the operation.

## Keywords

Undifferentiated Pleomorphic Sarcoma, Jejunum, Metastatic Lymph Nodes

---

## 1. Introduction

High-grade pleomorphic malignant soft tissue tumors that do not differentiate into specific histological features are classified as undifferentiated pleomorphic sarcoma (UPS), previously known as malignant fibrous histiocytoma (MFH). UPS usually occurs in the soft tissues of the extremities. Visceral and particularly gastrointestinal involvement is rare.

Most frequently, metastasis occurs via the haematogenous route, with the lung being the most common site of metastatic disease. The prognosis of UPS is basically poor, particularly when accompanied with metastatic lesions is further poorer.

This paper reports the case of a long-term survivor of UPS in the jejunum with lymph node metastases and presents a review of the literature on primary intestinal UPS or MFH.

## 2. Case Report

The patient was a 50-year-old Japanese man who presented with a chief complaint of breathlessness at 1 month previously. He was previously healthy. He consulted a local clinic where anemia was detected and tests for occult blood in the stool were positive. Upper endoscopy was performed, but no abnormal findings were observed. The patient was referred to our hospital in early June 2007 for further examination.

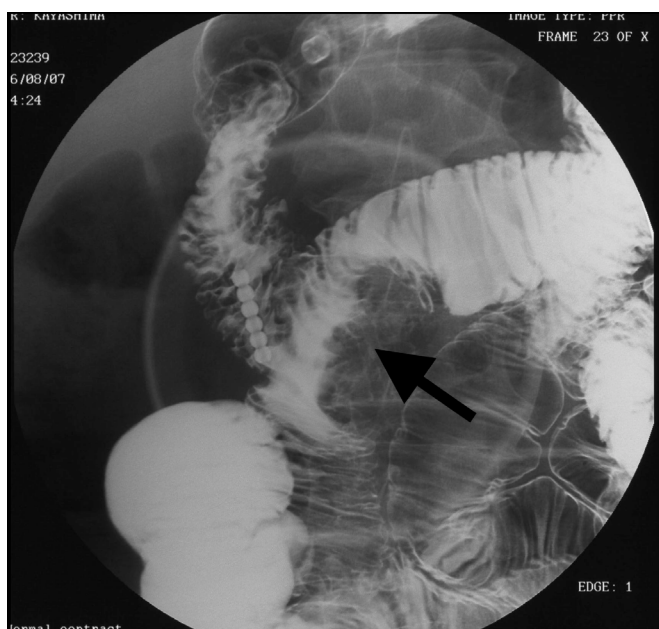
Laboratory examination revealed a hemoglobin level of 6.1 g/dL, iron deficiency anemia was noted; hence, he was hospitalized, and further examinations were performed. He had no history of any previous surgery.

A colonoscopy disclosed a 2-cm-diameter pedunculated polyp in the sigmoid colon and an inflow of fresh blood at the ileal end. It was presumed that small intestine was the source of bleeding.

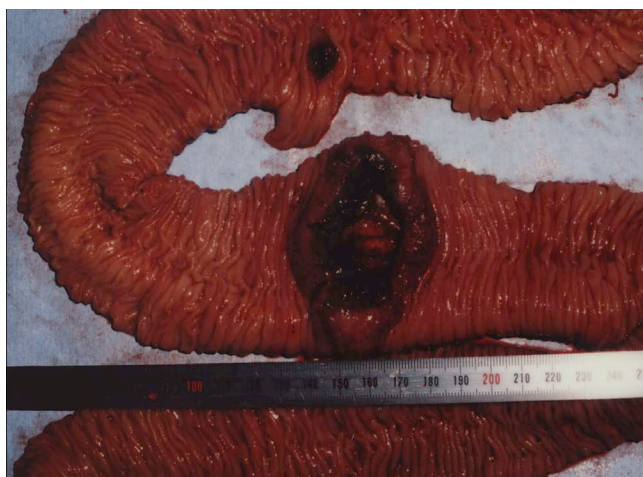
Endoscopic mucosal resection of the colonic polyp was performed with no complications. A histopathological examination revealed adenocarcinoma in the adenoma. The invasion depth of the carcinoma was limited to the mucosal layer. There was no lymphovascular invasion of carcinoma cells. Lateral and vertical margins of the specimen were negative.

We considered that the cause of anemia was not the colonic polyp. Abdominal computed tomography did not reveal any tumors. A small bowel X-ray series revealed an approximately 4-cm size with protruded lesion (image shows a filling defect image) in the proximal jejunum (**Figure 1**). Based on a presumptive diagnosis of the hemorrhagic small bowel tumor, the patient underwent a laparotomy after his clinical condition improved through blood transfusion.

Intraoperative findings revealed there were no fluid collections in the abdominal cavity. There was no sign of intraabdominal spread. A tumor accompanied with adhesions in the major omentum was observed in the jejunum at approximately 90-cm from the Treitz ligament. Some swollen lymph nodules were also noted in the mesentery near the jejunal tumor. The extent of the jejunal



**Figure 1.** Small bowel X-ray series showing an approximately 4-cm size with protruded lesion (image shows a filling defect; arrow) in proximal jejunum.



**Figure 2.** Gross morphological examination of the surgical specimen demonstrated a primary tumor and a small nodule, which was incidentally identified on opening the lumen of the resected jejunum. The primary tumor, measuring 46 × 72 mm, was a type-2 circumferential lesion. A small node at the luminal side of the jejunum was incidentally detected. It was a type-1 tumor, which measured 15 × 10 mm and was located on 220 mm to the oral side of the primary tumor.

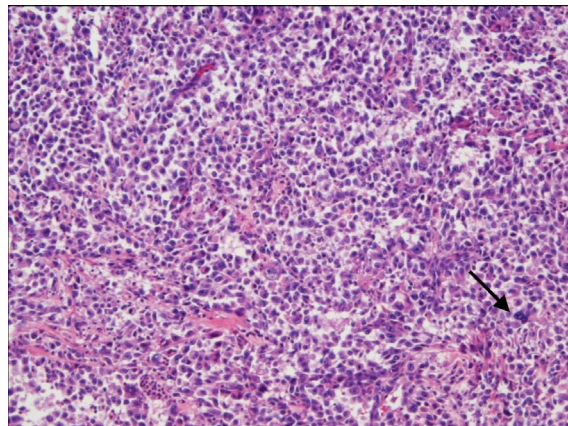
resection was determined based on the location of the tumor and the mesentery with the enlarged lymph nodes. Segmental resection of the jejunum was performed at 20-140 cm from the Treitz ligament. Complete surgical excision with en-bloc regional lymph node dissection was performed.

Gross morphology of the surgical specimen demonstrated a primary tumor and a small nodule, which was incidentally found on opening the lumen of the resected jejunum (**Figure 2**).

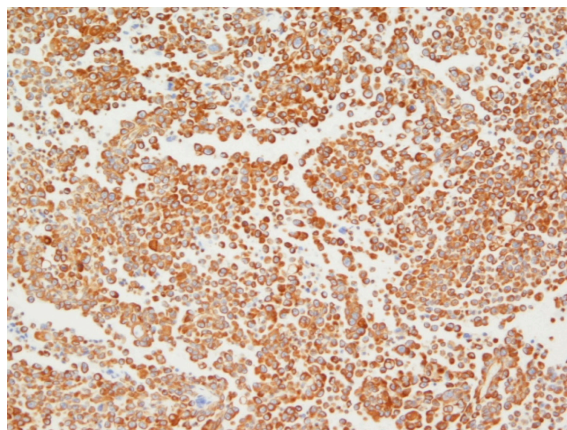
Microscopically, the primary tumor, in which highly atypical cells had infiltrated and diffusely proliferated (**Figure 3**), involved mucosal to the serosal layers. Multinucleated cells, cells with a kidney- or horseshoe-shaped nucleus, and also cells with large bizarre nuclei were intermingled in the lesion. An uneven distribution of nuclei and numerous abnormal mitotic figures were observed. Although the characteristic sequence of the tumor cells could not be seen, cell proliferation, which was accompanied by cell fusion, was observed. The other small lesion in the jejunum was suggested to be a metastatic lesion because similar tumor cells showing nodular proliferation were observed from the mucosa to the submucosal layers. Three metastatic mesenteric lymph nodes were also detected among the dissected nodes.

Immunohistochemical stains were positive for vimentin (**Figure 4(a)**),  $\alpha$ 1-antichymotrypsin (**Figure 4(b)**), and MIB-1 (**Figure 4(c)**), and negative for S-100, CD34, cytokeratin, non-squamous cytokeratin, squamous cytokeratin, LCA, L-26, CD79a, epithelial membrane antigen, keratin, and HMB-45.

The final histopathological diagnosis was UPS of the jejunum with metastatic lymph nodes and a skip lesion in the jejunum.

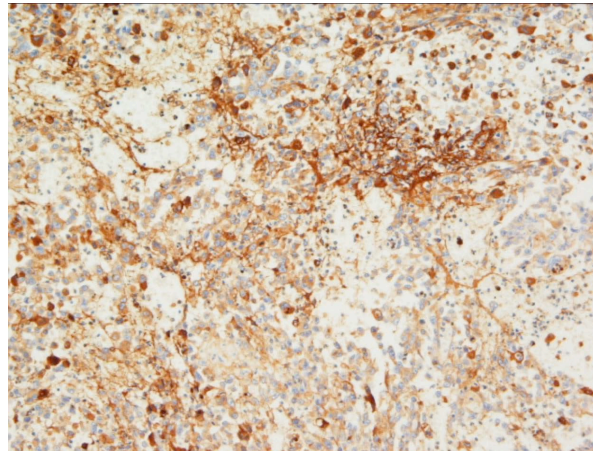


**Figure 3.** Highly atypical cells infiltrated the tumor and diffusely proliferated. Cells exhibiting the cell fusion were observed (arrow). (Hematoxylin and Eosin stain; magnification, 100 x).

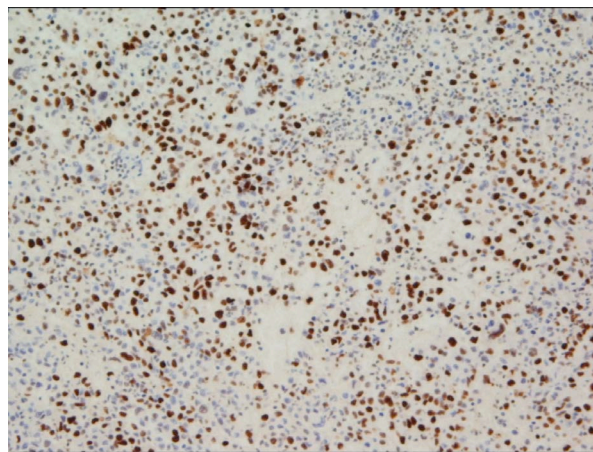


(a)





(b)



(c)

**Figure 4.** Immunohistochemical stains were positive for vimentin (a),  $\alpha$ 1-antichymotrypsin (b), and MIB-1 (c) (magnification, 100 x).

The postoperative course was uneventful. The patient was not given adjuvant chemotherapy, and was discharged on postoperative day 16. He is currently well without any evidence of recurrence for >10 years after his operation.

### 3. Discussion

MFH was previously well known as a common soft tissue tumor, usually occurring in the extremities [1]. It has been classified into five subtypes; storiform/pleomorphic, myxoid, giant cell, inflammatory, and angiomatoid [2]. According to the World Health Organization classification of bone and soft-tissue tumors of 2002, pleomorphic-type MFH was termed UPS [3]. Namely, UPS forms a large, rapidly growing solid mass and is histologically characterized by pleomorphic tumor cells in storiform patterns.

Primary UPS/MFH of the small intestine is extremely rare. We reviewed the total 18 cases of small intestinal UPS/MFH, including our case [4] [5] [6] [7]. The mean age of the patients was 52.9 (range 16 - 77) years, and the ratio of men to women was 12:6. The tumor arose from the duodenum in four patients, from

the jejunum in seven patients, from the ileum in six, and from the jejunum and the ileum in one. The tumor was solitary in the 16 patients, whereas multiple tumors were observed in two. Initially, two patients, including ours, exhibited metastases to regional mesenteric lymph nodes. One patient had local invasion (*i.e.*, inferior vena cava), one case had peritoneal carcinomatosa, and one case had a distant metastasis (lung) accompanied with local lymph node metastases.

Seventeen patients underwent resection, whereas one underwent bypass surgery. Three patients died early after surgery, possibly because of surgical complications. Only one patient exhibited recurrence in the abdominal cavity, whereas distant metastases or lymph node metastases developed in four patients. Six patients died of advanced disease. Eight of eighteen patients survived for >1 year, however, only four patients survived >1 year without recurrence. There were four patients with metastasis and invasion during detection. Among them, excluding our patient who survived >10 years, the prognosis was poor.

Essentially, early and complete surgical excision may be the only form of management, which may provide the patient with good results. Generally, patients with metastases have particularly poor prognosis. It is important that mesenteric lymph nodes are also carefully observed during the surgery. The first step to improving of prognosis is that the mesentery including the metastatic lymph nodes should be properly resected, in addition to the primary lesion. In our case, despite mesenteric lymph node metastases and the metastatic lesion in the jejunum, the patient achieved long-term survival without recurrence possibly because of complete surgical resection. Although distant metastatic lesions such as those in the lung and the liver did not happen to occur in our patient, future research is necessary to prevent the occurrence of distant metastases.

#### 4. Conclusion

Primary UPS of the small intestine generally has a poor prognosis, particularly when accompanied with metastatic lesions. Our patient had primary jejunal UPS with regional lymph node metastases and a skip metastatic lesion in the jejunum. Despite the high rate of recurrence, the patient achieved long-term survival without recurrence because complete surgical resection supposedly prevents local recurrence. Future research is necessary to prevent the occurrence of distant metastases.

#### Acknowledgements

The authors declare that they have no competing interests.

#### References

- [1] Weiss, S.W. and Enzinger, F.M. (1978) Malignant Fibrous Histiocytoma: An Analysis of 200 Cases. *Cancer*, **41**, 2250-2266.  
[https://doi.org/10.1002/1097-0142\(197806\)41:6<2250::AID-CNCR2820410626>3.0.CO;2-W](https://doi.org/10.1002/1097-0142(197806)41:6<2250::AID-CNCR2820410626>3.0.CO;2-W)

- [2] Enzinger, F.M. and Weiss, S.W. (1983) *Soft Tissue Tumors*. The C. V. Mosby Company, St. Louis, Toronto, London, 166-198.
- [3] Fletcher, C.D.M., Unni, K.K. and Mertens, F. (2002) *World Health Organization Classification of Tumors Pathology and Genetics of Tumors of Soft Tissue and Bone*. IAPC Press, Lyon.
- [4] Fu, D.L., Yang, F., Maskay, A., *et al.* (2007) Primary Intestinal Malignant Fibrous Histiocytoma: Two Case Reports. *World Journal of Gastroenterology*, **13**, 1299-1302.
- [5] Katsourkis, A., Noussios, G., Hadjis, I., Evangelou N. and Chatzitheoklitos, E. (2011) Primary Malignant Fibrous Histiocytoma: A Rare Case. *Case Reports in Medicine*, **2011**, 1-3. <https://doi.org/10.1155/2011/134801>
- [6] Makni, A., Chebbi, F., Azzouz, H., Magherbi, H., Jouini, M., Kacem M. and Safta Z.B. (2011) A Case of Primary Malignant Fibrous Histiocytoma of the Duodenum. *International Journal of Surgery Case Reports*, **2**, 103-105. <https://doi.org/10.1016/j.ijscr.2011.01.011>
- [7] Wang, Z.S., Xiong, C.L., Zhan, N., Xiong, G.S., Li, H. and Hu, H. (2005) Primary Malignant Fibrous Histiocytoma of the Small Bowel: A Report of an Additional Case in Duodenum. *International Journal of Gastrointestinal Cancer*, **32**, 105-12. <https://doi.org/10.1385/IJGC:36:2:105>