

Cervical and Lumbosacral Radiculoplexus Neuropathy Following Influenza Vaccination

David S. Younger^{1,2}

¹Department of Clinical Medicine, CUNY School of Medicine, City College, New York, NY, USA

²Graduate School of Public Health and Health Policy, City University of New York, New York, NY, USA

Email: youngd01@nyu.edu

How to cite this paper: Younger, D.S. (2019) Cervical and Lumbosacral Radiculoplexus Neuropathy Following Influenza Vaccination. *World Journal of Neuroscience*, 9, 255-261.

<https://doi.org/10.4236/wjns.2019.94019>

Received: October 6, 2019

Accepted: October 18, 2019

Published: October 21, 2019

Copyright © 2019 by author(s) and Scientific Research Publishing Inc.

This work is licensed under the Creative Commons Attribution International License (CC BY 4.0).

License (CC BY 4.0).

<http://creativecommons.org/licenses/by/4.0/>



Open Access

Abstract

Acute cervical radiculoplexus neuropathy contralateral to influenza vaccination preceded proximal and distal leg weakness, sensory loss and corresponding deficits of lumbosacral radiculoplexus neuropathy. Treatment with pulse corticosteroids followed by tapering oral corticosteroids and monthly low dose intravenous immune globulin was associated with eventual improvement.

Keywords

Influenza, Vaccination, Microscopic Vasculitis, Epidermal Nerve Fibers, Electrodiagnostic Studies, Intravenous Immune Globulin

1. Introduction

The induction of host protective immunity is an important factor in immunization strategies to prevent epidemics in the United States (US). Protection against influenza also known as the “flu”, is a national priority. The US 2017-18 influenza season (October 1, 2017-May 19, 2018) was a high severity season with high levels of outpatient clinic and emergency department visits for influenza-like illnesses (ILI). Vaccine recommendations each year rely upon given global influenza virologic and epidemiologic surveillance, genetic characterization, antigenic characterization, and candidate vaccine viruses available for production. In 2018, the Food and Drug Administration’s Vaccines and Related Biologic Products Advisory Committee recommended the trivalent vaccine containing an A/Michigan/45/2015 A(H1N1)pdm09-like virus, an A/Singapore/INFIMH-16-0019/2016 A(H3N2)-like virus, and a B/Colorado/06/2017-like (B/Victoria lineage) [1].

There is concern in vaccinating untreated autoimmune patients such as those

with preclinical involvement and well-defined autoantibodies. A study of the immune response to exogenous stimulation associated with H1N1 vaccination in untreated Sjögren's syndrome (SS) patients [2] showed enhanced promotion of pathogenic SS antibodies due to polyclonal B-cell activation. These findings offer one explanation for immunization-related adverse events associated with routine flu vaccination. Such events may include acute and subacute neuropathic neuromuscular disorders that conform to strict case definition [3], effective treatment of which depends upon reaching the correct diagnosis and initiating prompt immunotherapy.

2. Patient Report

A middle-age man received a standard-dose of inactivated influenza vaccine (split virion) unadjuvanted (Fluvax®) in the upper left arm in the fall 2018. This was followed by arm pain and heaviness in the contralateral arm from the shoulder to the hand. He presented to a local emergency room where he underwent non-contrast magnetic resonance imaging (MRI) of the brain that showed scattered white matter changes. Non-contrast MRI of the brachial plexus was normal. Non-contrast MRI of the cervical and lumbar spine showed age-appropriate degenerative changes. Lumbar cerebrospinal fluid showed normal protein content without pleocytosis or evidence of infection. He received pulse intravenous corticosteroids (CS) for one week followed by a slow taper of prednisone that led to improved arm pain.

He presented one month later with insidious pain and heaviness of the proximal left thigh. Neurological examination showed right scapular winging and wasting of proximal shoulder muscles with grade 3+/5 Medical Research Council (MRC) [4] strength in the supraspinatus, infraspinatus, deltoid, biceps brachii, and serratus anterior muscles. There were light touch and temperature perception deficits along the right upper lateral arm and forearm, with grade 4/5 MRC strength in the left iliopsoas, vastus lateralis, and gluteus maximus. There was patchy anterolateral discriminative light touch and temperature sensory loss along the left thigh and calf. Tendon reflexes were hypoactive in the right arm and in both legs.

Nerve conduction studies (NCS) and electromyography (EMG) studies of the legs and right arm were consistent with cervical and lumbar radiculoplexus neuropathies. Laboratory evaluation showed a positive nuclear antibody (ANA), C1q binding assay was 4.7 ugE/ml (normal 0 to 3.9 ugE/ml), C4 was 13 mg/dL (normal 15 - 57 mg/dL), SSA was >8 AI (normal < 1 AI), and the absolute CD3+ T-cell count was 503 cells/uL (normal 656 to 1903 cell/uL), and the CD8+ T-cell subset comprised 35% (normal 11% - 33%). There were normal chemistries, complete blood count (CBC), Lyme serology, thyroid function and autoantibodies, including levels for C3, myeloperoxidase, proteinase-3, ribonucleoprotein, scleroderma-70, Smith, SSB, double-stranded deoxyribonucleic acid, total immunoglobulin (Ig) G, A and M antibodies, and anti-neutrophil cytoplasmic antibody. Intraepidermal nerve fiber (IENF) analysis of the left calf and thigh (**Figure**

1) showed significantly reduced mean densities. The left calf IENF density was 1.9/mm skin (range 1.2 - 2.4) and left thigh was 5.4/mm skin (range 3.4 - 7) (normal calf > 5/mm, and thigh > 8/mm) without evidence of Congo red immunofluorescence for amyloid.

He was treated with intravenous immune globulin (IVIg), 35 grams monthly for 9 months with improvement.

3. Comment

Dyck and coworkers [5] described lumbosacral radiculoplexus neuropathy (LRPN) as monophasic severe lower leg pain and weakness that commenced unilaterally, with delayed involvement of the other leg in middle-age patients with type 2 diabetics (T2D) and relatively good glycemic control; non-diabetic and diabetic (DLRPN) forms have an identical presentation [6] [7]. Electrodiagnostic studies reveal acute spontaneous activity, subacute to chronic axonal features consistent with a radiculoplexopathy (involving root, plexus and peripheral nerve), as the term LRPN implies. An etiopathogenesis that relates to ischemic microvasculitis (MV) (**Figure 2**) that affects arteriae nervorum measuring < 100 um in diameter, was postulated in 33 prospectively studied patients with DLRPN [5] in whom biopsy of a distal cutaneous nerve revealed neovascularization, injury neuroma, perineurial thickening, multifocal fiber loss and lymphocytic inflammation in up to one-half of biopsied nerves.

Two decades later Massie and colleagues [8] described 85 patients with T2D and cervical radiculoplexus neuropathy (CRPN), and pain and numbness overshadowed by profound weakness. In contrast to LRPN, the presentation was more acute and clinical deficits peaked in the first week. Unlike brachial plexus neuritis, which typically manifests upper trunk involvement, there was frequent involvement of the upper, middle and lower plexuses, as in our case. Electrodiagnostic studies show axonal neuropathy with evidence of paraspinous denervation. More than half of affected patients have one or more additional affected body regions including contralateral cervical, lumbosacral, and thoracic regions. Evidence of ischemic nerve injury is the predominant feature in cutaneous nerve biopsy tissues accompanied by epineurial perivasculitis (PV), defined as inflammation surrounding but not invading the vessel walls in 100% of cases, with MV so noted in two-thirds. Given the clinicopathologic similarity to the two disorders, CRPN and LRPN are in a spectrum of MV-related autoimmune disorders.

The Peripheral Nerve Society and Brighton Collaboration of Vasculitic Neuropathy [9] established respective guidelines for the classification, diagnosis, investigation, and treatment of so-called non-systemic vasculitic neuropathy (NSVN). The support of MV in the spectrum of NSVN was the finding of MV with vascular necrosis in a cutaneous sensory nerve biopsy of a patient with clinically apparent DLRPN [10] in whom postmortem examination showed PV along the sciatic and femoral nerves (**Figure 3(a)** and **Figure 3(b)**), lumbar plexus and dorsal roots.

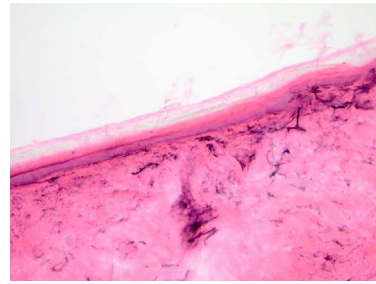


Figure 1. Intraepidermal nerve fibers. There are reduced densities of epidermal nerve fibers in the calf and thigh (shown) (PGP 9.5, H&E) in a 3 mm punch skin biopsy specimen (200×).

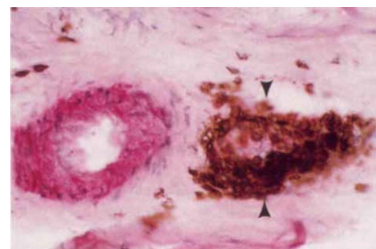


Figure 2. Microvasculitis. A focal intense collection of CD3+ T-cells (immunoperoxidase) efface the wall of a small epineurial blood vessel (arrowheads). In deeper sections (not shown) the same structure stains red in double-labeling with antiactin smooth muscle antigen, a marker for the blood vessel wall (400×). Reproduced from, Younger DS, Rosoklija G, Hays AP, *et al.* Diabetic peripheral neuropathy: a clinicopathologic and immunohistochemical analysis of sural nerve biopsies. *Muscle Nerve* 1996; 19: 722-727, with permission of the publisher.

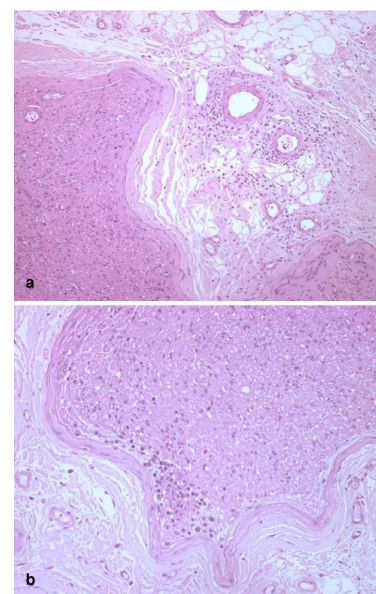


Figure 3. Postmortem histopathology. (a) Transverse section of the left sciatic nerve shows perivascular chronic inflammation surrounding small blood vessels of the epineurium. (b) Transverse section of the left femoral nerve in addition shows perivascular chronic inflammation in the subperineurial area. Inflammatory cells infiltrate the adjacent endoneurium (Paraffin, H&E, 200×), From reference [11], with permission of the publisher.

Despite its rarity, vaccination-related vasculopathy is a reportable adverse event following immunization. The condition can be permanently disabling and thus important to recognize. Hadden and colleagues [3] described guidelines for collection, analysis, and presentation of immunization safety data for reporting cases. Six such patients diagnosed with presumed NSVN, without nerve biopsy had presented clinical and electrodiagnostic findings of focal, multifocal neuropathy, and distal axonal polyneuropathy. Five had evidence of predisposing systemic conditions such as lupus, Hepatitis B virus infection, focal vasculitis of the skin or polyarteritis nodosa, only 3 of whom [11] [12] [13] received a preceding influenza immunization before onset of the neurological disorder. Treatment with IVIg therapy was associated with an improved outcome of NSVN in all those studied. The present patient was similar to other reported cases in the presence of seropositive ANA, and increased C1q binding and SSA antibody levels in association with radiculoplexus neuropathies, which have an immune etiopathogenesis causally related to MV and NSVN.

Elevated titers of SSA antibody in the serum in the present patient suggested contemporaneous SS. The full-blown disorder is characterized by xerophthalmia, xerostomia, arthralgia, myalgia and severe fatigue [14]. Lymphocytic infiltration of lacrimal salivary glands is the hallmark of the disease, which results in partial destruction of glandular parenchyma. Disease classification based on new preliminary American College of Rheumatology (ACR) criteria required a positive salivary gland biopsy or the presence of an elevated serum SSA antibody [15]. Extraglandular peripheral nervous system (PNS) involvement occurs in up to two-thirds of SS patients [16], typically manifesting peripheral and autonomic neuropathies with a clinical presentation that depends upon the sensory neuron involved the caliber of the axon, its location and whether sensory ganglia, distal large myelinated or small unmyelinated fibers are primarily involved. Mono-neuropathy multiplex, radiculoneuropathy, and sensory axonal polyneuropathies are frequent findings associated with MV [17].

Considering that CRPN and LRPN are subtypes of NSVN, a similar treatment regimen for patients commences with CS and IVIg therapy. The benefit of CS derives from its inhibitory properties on inflammatory and immune responses. Corticosteroids are administered intravenously as methylprednisolone at a dose of 1000 mg for 3 to 5 days, followed by oral prednisone [18] followed by 1 mg/kg of oral prednisone that is slowly tapered by 5 to 10 mg every few weeks after one to two months depending on the patient's response and severity of the disease [19] [20]. Patients with progressive symptoms early in the course of radiculoplexus neuropathy are candidates for immunotherapy with IVIg [21]. An open, uncontrolled study employing intravenous methylprednisolone in patients with clinically deteriorating LRPN, showed improvement in the Neuropathy Impairment Score commensurate with clinical improvement [22] [23].

Disclosure

The author has nothing to disclose.

Conflicts of Interest

The author declares no conflicts of interest regarding the publication of this paper.

References

- [1] Garten, R., Blanton, L., Abd Elal, A.I., *et al.* (2018) Update: Influenza Activity in the United States during the 2017-18 Season and Composition of the 2018-2019 Influenza Vaccine. *Morbidity and Mortality Weekly Report*, **67**, 634-642. <https://doi.org/10.15585/mmwr.mm6722a4>
- [2] Brauner, S., Folkersen, L., Kvarnström, M., *et al.* (2017) H1N1 Vaccination in Sjögren's Syndrome Triggers Polyclonal B Cell Activation and Promotes Autoantibody Production. *Annals of the Rheumatic Diseases*, **76**, 1755-1763.
- [3] Hadden, R.D.M., Collins, M.P., Zivkovic, S.A., *et al.* (2017) Vasculitic Peripheral Neuropathy: Case Definition for Collection Analysis, and Presentation of Immunization Safety Data. *Vaccine*, **35**, 1567-1578. <https://doi.org/10.1016/j.vaccine.2015.11.047>
- [4] Medical Research Council (1976) Aids to Examination of the Peripheral Nervous System. Memorandum No. 45. Her Majesty's Stationary Office, London.
- [5] Dyck, P.J. and Norell, J.E. (1999) Microvasculitis and Ischemia in Diabetic Lumbosacral Radiculoplexus Neuropathy. *Neurology*, **53**, 2113-2121. <https://doi.org/10.1212/WNL.53.9.2113>
- [6] Dyck, P.J.B. and Windebank, A.J. (2002) Diabetic and Nondiabetic Lumbosacral Radiculoplexus Neuropathies: New Insights into Pathophysiology and Treatment. *Muscle & Nerve*, **25**, 477-491. <https://doi.org/10.1002/mus.10080>
- [7] Dyck, P.J., Norell, J.E. and Dyck, P.J. (2001) Non-Diabetic Lumbosacral Radiculoplexus Neuropathy: Natural History, Outcome and Comparison with the Diabetic Variety. *Brain*, **124**, 1197-207. <https://doi.org/10.1093/brain/124.6.1197>
- [8] Massie, R., Mauermann, M.L., Staff, N.P., Amrami, K.K., *et al.* (2012) Diabetic Cervical Radiculoplexus Neuropathy: A Distinct Syndrome Expanding the Spectrum of Diabetic Radiculoplexus Neuropathies. *Brain*, **135**, 3074-3088. <https://doi.org/10.1093/brain/aws244>
- [9] Collins, M.P., Dyck, P.J., Gronseth, G.S., *et al.* (2010) Peripheral Nerve Society Guideline on the Classification, Diagnosis, Investigation, and Immunosuppressive Therapy of Non-Systemic Vasculitis Neuropathy: Executive Summary. *Journal of the Peripheral Nervous System*, **15**, 176-184. <https://doi.org/10.1111/j.1529-8027.2010.00281.x>
- [10] Younger, D.S. (2011) Diabetic Lumbosacral Radiculoplexus Neuropathy: A Post-mortem Studied Patient and Review of the Literature. *Journal of Neurology*, **258**, 1364-1367. <https://doi.org/10.1007/s00415-011-5938-8>
- [11] Levy, Y., Uziel, Y., Zandman, G.G., *et al.* (2003) Intravenous Immunoglobulins in Peripheral Neuropathy Associated with Vasculitis. *Annals of the Rheumatic Diseases*, **62**, 1221-1223. <https://doi.org/10.1136/ard.2002.003996>
- [12] Morihara, K., Arakawa, Y., Takenaka, H., Morihara, T. and Katoh, N. (2011) Systemic Lupus Erythematosus Following Vaccination against 2009 Influenza A (H1N1). *Lupus*, **20**, 775-776. <https://doi.org/10.1177/0961203310389485>
- [13] Fu, M.H., Tsai, W.C., Lan, J., *et al.* (2014) Churg-Strauss Syndrome Following Vaccination against 2010 Influenza A (H1N1): A Case Report. *Acta Neurologica Taiwanica*, **23**, 95-101.

- [14] Tincani, A., Andreoli, L., Cavazzana, I., *et al.* (2013) Novel Aspects of Sjögren's Syndrome in 2012. *BMC Medicine*, **11**, 93. <https://doi.org/10.1186/1741-7015-11-93>
- [15] Shiboski, S.C., Shiboski, C.H., Criswell, L.A., *et al.* (2012) American College of Rheumatology Classification Criteria for Sjögren's Syndrome: A Data-Driven, Expert Consensus Approach in the Sjögren's International Collaborative Clinical Alliance Cohort. *Arthritis Care & Research*, **64**, 475-487. <https://doi.org/10.1002/acr.21591>
- [16] Jamilloux, Y., Magy, L., Hurtevent, J.F., *et al.* (2014) Immunological Profiles Determine Neurological Involvement in Sjögren's Syndrome. *European Journal of Internal Medicine*, **25**, 177-181. <https://doi.org/10.1016/j.ejim.2013.10.005>
- [17] Mori, K., Iijima, M., Koike, H., *et al.* (2005) The Wide Spectrum of Clinical Manifestations in Sjögren's Syndrome-Associated Neuropathy. *Brain*, **128**, 2518-2534. <https://doi.org/10.1093/brain/awh605>
- [18] Naddaf, E. and Dyck, P.J.B. (2015) Vasculitic Neuropathies. *Current Treatment Options in Neurology*, **17**, 374. <https://doi.org/10.1007/s11940-015-0374-1>
- [19] Burns, T.M., Schaublin, G. and Dyck, P.J.B. (2007) Vasculitic Neuropathies. *Neurologic Clinics*, **25**, 89-113. <https://doi.org/10.1016/j.ncl.2006.11.002>
- [20] Gorson, K.C. (2006) Therapy for Vasculitic Neuropathies. *Current Treatment Options in Neurology*, **8**, 105-117. <https://doi.org/10.1007/s11940-006-0002-1>
- [21] Thaisetthawatkul, P. and Dyck, P.J.B. (2010) Treatment of Diabetic and Nondiabetic Lumbosacral Radiculoplexus Neuropathy. *Current Treatment Options in Neurology*, **12**, 95-99. <https://doi.org/10.1007/s11940-010-0059-8>
- [22] Dyck, P.J. and Norell, J.E. (2001) Methylprednisolone May Improve Lumbosacral Radiculoplexus Neuropathy. *Canadian Journal of Neurological Sciences*, **28**, 224-227. <https://doi.org/10.1017/S0317167100001360>
- [23] Tamburin, S. and Zanette, G. (2009) Intravenous Immunoglobulin for the Treatment of Diabetic Lumbosacral Radiculoplexus Neuropathy. *Pain Medicine*, **10**, 1476-1480. <https://doi.org/10.1111/j.1526-4637.2009.00704.x>