

# Combined Procedure for Coronary Artery Bypass Grafting and Pulmonary Hydatid Disease

A. Al Khaddour, S. Al Hashimi, N. Abbas

Damascus University Hospital, Damascus, Syria  
Email: ahmedal@doctors.org.uk, samer@gmail.com, abbas@gmail.com

Received 10 December 2015; accepted 10 January 2016; published 13 January 2016

Copyright © 2016 by authors and Scientific Research Publishing Inc.  
This work is licensed under the Creative Commons Attribution International License (CC BY).  
<http://creativecommons.org/licenses/by/4.0/>



Open Access

---

## Abstract

**In this study we reported one case of combined procedure for coronary artery bypass grafting and excision of right pulmonary hydatid cyst. Concerns of possible hydatid systemic dissemination as a result of direct vascular breaches are raised. We suggest that avoidance of cardiopulmonary bypass (CPB) if that possible is beneficial for the treatment. If not possible then the excision and clearance of the hydatid cyst should be done in the first place before going on bypass.**

## Keywords

**Echinococcosis, CT Scan, Coronary Artery Bypass Grafting, Hydatid Cyst, NYHA-CCS-DM II, LIMA-LAD-SV-OM-RLL-EF**

---

## 1. Background

Hydatid disease caused by echinococcosis is an endemic parasitic disease in Mediterranean Countries [1]. The most frequent anatomic locations are liver and lung. 75% of these lesions are single. It is relatively a common disease in Syria [1]. Pulmonary hydatid disease occupies the third place among surgical thoracic diseases after lung cancer and mediastinal tumours [1]. The diagnosis of pulmonary hydatid cyst is an indication for surgery [2].

In this study we reported one case of combined procedure for coronary artery bypass grafting and excision of right pulmonary hydatid cyst.

## 2. Case Presentation

Fifty-six-year-old female referred for consideration of coronary artery bypass grafting. She was complaining of

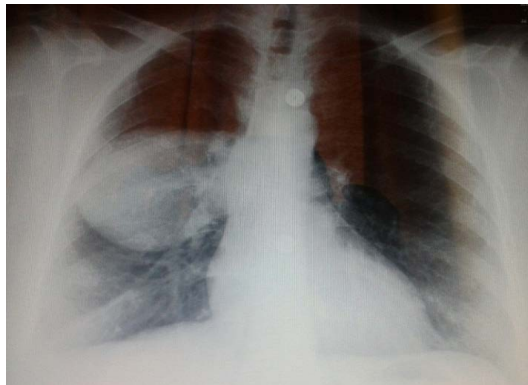
increasing angina and breathlessness. She was in class three CCS (Canadian Cardiovascular Society classification) and Class three NYHA (New York heart association Classification). Her coronary risk factors include: smoking for the last thirty years and uncontrolled DM (diabetes mellitus) type II.

Her chest X ray revealed smooth rounded lesion in the right lung (**Figure 1**).

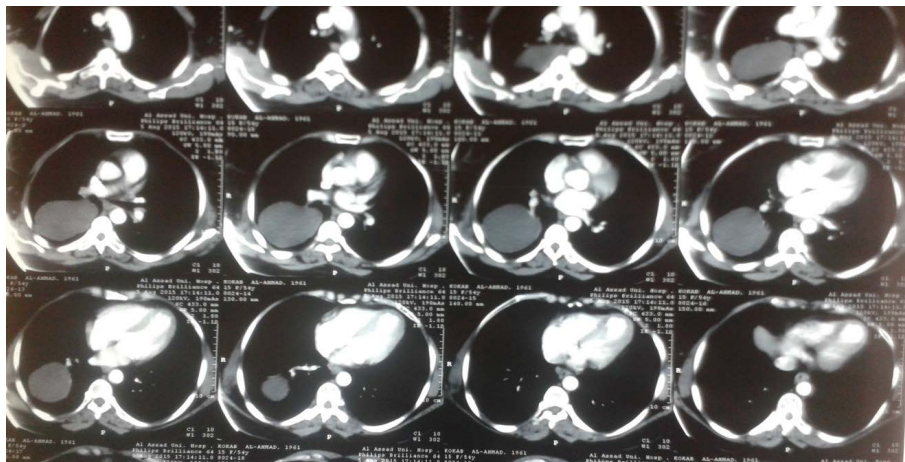
Thoracic and abdomen CT scan (**Figure 2**) revealed a homogenous cystic lesion  $11 \times 6.7$  cm in the upper section of the right lower lobe (RLL). Preoperative biochemical parameters were normal with negative cystic antibodies.

Her coronary angiography revealed two vessel disease: 99% stenosis in the left anterior Descending artery (LAD) and 80% in the obtuse marginal artery with moderate left ventricular function with Ejection fraction EF 45%. Patient was consented for the combined procedure. She was quoted a 5% risk of Mortality and 3% risk of Stroke.

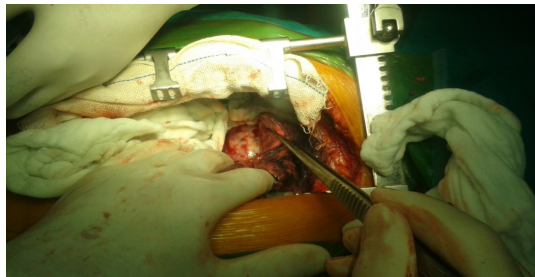
She underwent combined procedure coronary artery bypass grafting (CABG x2) and pulmonary hydatid cyst excision (**Figure 3** and **Figure 4**). Under general anaesthesia with double lumen endotracheal intubation median sternotomy was performed. The pericardium remained closed in order to protect from any possible contamination of the cyst content. The right side of the sternum was lifted with the mammary retractor. Right lung was dropped. The Cyst was easily identified in the upper section of the right lower lobe. The surgical field was protected with gauze soaked with hypertonic saline solution. Patient received 200 mg hydrocortisone IV to protect against any systemic immunoreactions. Clear fluid was aspirated from the cyst. The cyst was injected with hypertonic solution before it was excised completely and safely. Small bronchial fistula in the bed of the cyst was closed using 30 vicryle stitches. The lung was inflated and checked for any air leak. Chest drain was inserted in the right side then the cardiac procedure was resumed. Left internal mammary artery harvested simultaneously with long saphenous vein from the right leg which was harvested endoscopically. Systemic heparin was admini-



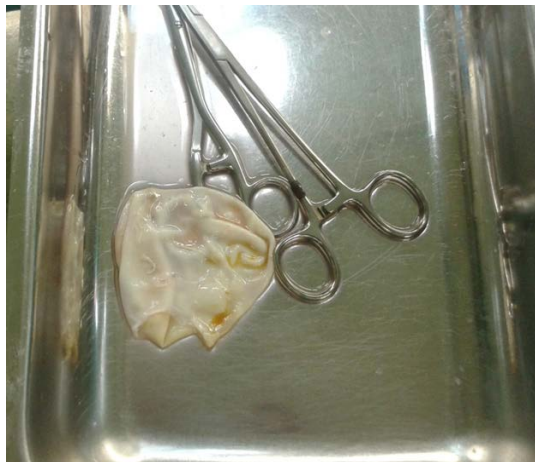**Figure 1.** Simple posterior anterior chest X ray showing the cyst in the Right lower lobe.



**Figure 2.** CT scan chest showing the cyst in the right lower lobe.



**Figure 3.** Surgical view after lifting the right chest with mammary retractor showing the cyst.



**Figure 4.** The excised cyst.

stered and cardiopulmonary bypass instituted using a right atrial single-stage cannula for venous drainage and ascending aortic cannulation for arterial return. Conduits were of satisfactory quality. The patient was cooled to 33 degrees centigrade, aortic cross-clamp applied and antegrade cold blood cardioplegia infused to achieve prompt cardiac arrest. The following grafts were then constructed:

- 1) SV to OM1
- 2) LIMA to LAD

The cross-clamp was then released and the heart resumed in sinus rhythm. The Proximal anastomoses were now constructed to the aorta using the side clamp.

Cardiopulmonary bypass was discontinued without complications. Two chest drains were inserted, haemostasis secured and the chest closed using 7 single sternal wires. The soft tissues were approximated in two layers.

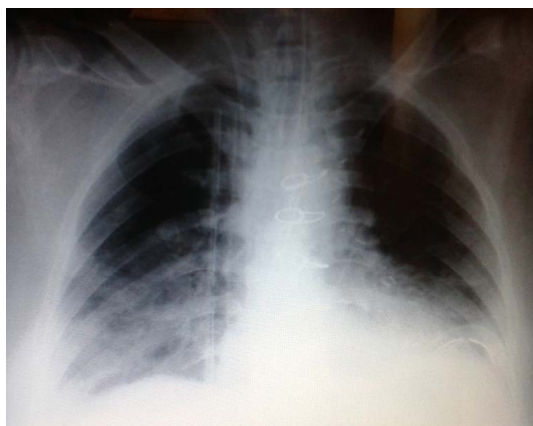
The skin was closed using monocryl (absorbable) suture. No systemic immunoreaction had been observed.

The patient was extubated six hours postoperatively. Patient had minimal pleural and mediastinal drainage postoperatively 350 mls/24h. Patient received one unit of red cell straight away postoperatively. Patient was transferred from the intensive care unite to the ward on the second postoperative day. She was discharged home on the fifth postoperative day without any complication. Her X ray on discharge was clear (**Figure 5**). The patient was discharged on oral Albendazol for 6 weeks.

### 3. Discussion

The Clinical presentation of the hydatid disease depends upon the site of the cysts and their size [2]. Small cysts may remain asymptomatic indefinitely. However, symptoms due to mass effect within organ, obstruction of blood or lymphatic flow, or complications such as rupture or secondary bacterial infections could be the result. Diagnosis is made by a combination of clinical, imaging and serological tests. Surgery remains the mainstay of treatment [2].

Coronary artery bypass grafting (CABG) is still the type of surgery that improves blood flow to the heart. And



**Figure 5.** Simple chest X ray following the procedure.

it is one of the treatments for coronary heart disease. The grafted artery or vein bypasses the blocked portion of the coronary artery. This creates a new path for oxygen rich blood to flow to the heart muscle.

Patients who require coronary artery bypass grafting and who also have concomitant surgical pathology like pulmonary hydatid disease constitute a high risk group. There are always concerns of possible hydatid systemic dissemination as a result of direct vascular breach [2]. Rupture of pulmonary hydatid cyst is a serious complication. It can lead to pleural effusion, pleural empyema, pneumonitis and pulmonary abscess [2]. In the persistent of right pleural effusion that occurs after open heart surgery, hydatid cyst should be remembered especially in the endemic region [3].

Surgical strategy for these patients remains controversial.

There is always a risk of cyst rupture with any positive ventilation also it is high risk to perform any procedure under general anaesthesia with a sick heart therefore we have chosen to perform a combined procedure starting with the excision of the pulmonary hydatid cyst then performing the grafting, although with this approach there is small Risk of bleeding in the lung after administering the heparin therefore we obliged to check the pulmonary surgical site by the end of the procedure.

The avoidance of cardiopulmonary bypass CPB is beneficial for the treatment if that possible [4] if not like in our case it is advisable to place an additional filter on the venous side of the circuit to prevent the passage of the particle to the pump [5].

There was no problem with our access with median sternotomy to reach the pulmonary cyst, Although it is feasible to do lateral extension (half clamshell) of the midline incision if we need to.

#### 4. Conclusions

Combined procedure of Coronary artery bypass grafting and excision of pulmonary hydatid disease is feasible starting with the excision of the hydatid cyst. It is advisable to avoid the cardiopulmonary bypass if that possible to prevent the passage of hydatid particle to the pump [5]. Median sternotomy provides a good access for both coronary artery bypass grafting and excision of the pulmonary hydatid cysts.

This study was approved by our ethical committee and it was presented at our hospital weekly scientific meeting.

#### References

- [1] Alkhaddour, A. and Abbas, N. (1999) Pulmonary Hydatid Cysts with Encouraging Early VATS Experience. Paper Presented at the 13th EACTS Meeting in Glasgow in September.
- [2] Kavukcu, S., Kilic, D., Tokat, A.O., Kutlay, H., Cangir, A.K., Enon, S., Okten, I., Ozdemir, N., Gungor, A., Akal, M. and Akay, H. (2006) Parenchyma Preserving Surgery in the Management of Pulmonary Hydatid Cysts. *Journal of Investigative Surgery*, **19**, 61-68. <http://dx.doi.org/10.1080/08941930500444586>
- [3] Kanko, M., Akbas, H., Liman, T. and Berki, K.T. (2005) Persistent Pleural Effusion after Open Heart Surgery; Giant Hydatid Cyst of the Liver and Its Demonstrative Images. A Case Report. *The Heart Surgery Forum*, **8**, E378-E379. <http://dx.doi.org/10.1532/HSF98.20051021>

- [4] Yilik, L., Yetkin, U., Ozpak, B. and Gurbuz, A. (2007) Beating Heart Coronary Bypass Procedure in a Hepatic Hydatid Cyst Patient. *The Internet Journal of Parasitic Diseases*, **3**.
- [5] Yalinize, H., Tokcan, A., Salih, O.K. and Ulus, T. (2006) Surgical Treatment of Cardiac Hydatid Disease. *Texas Heart Institute Journal*, **33**, 333-339.