

Lumbar Hernia, a Rare Cause of Intestinal Occlusion: About a Case

Lassina Traore*, N'Djetche Alexandre Anoh, Auguste Alexandre Adon, Laurent Kouadio, Julien Kouame, Sabine Kanin Aka-Bouede, Germain Koffi Kouadio

General and Proctological Surgery Service, Teaching Hospital of Treichville, Departement of Digestive Diseases, College of Medecine, Felix Houphouet Boigny University, Abidjan, Côte D'Ivoire

Email: *traolas126@gmail.com

How to cite this paper: Traore, L., Anoh, N.A., Adon, A.A., Kouadio, L., Kouame, J., Aka-Bouede, S.K. and Kouadio, G.K. (2018) Lumbar Hernia, a Rare Cause of Intestinal Occlusion: About a Case. *Surgical Science*, 9, 351-357.

<https://doi.org/10.4236/ss.2018.910042>

Received: August 13, 2018

Accepted: September 27, 2018

Published: September 30, 2018

Copyright © 2018 by authors and Scientific Research Publishing Inc. This work is licensed under the Creative Commons Attribution International License (CC BY 4.0).

<http://creativecommons.org/licenses/by/4.0/>



Open Access

Abstract

Defects of the posterolateral abdominal wall of the abdomen, lumbar hernias are rare. They represent 2% to 3% of hernias of the abdominal wall. This rarity explains the large number of short series and the absence of a well-defined therapeutic modality in the publications. Grynfeltt's hernia at the top and Jean Louis Petit's at the bottom are the two entities. The old lumbar hernias are bulky with a rich history and easy diagnosis. Though young, they are discreet and reveal most often by their strangulation. We report the case of a Grynfeltt hernia revealed by colonic occlusion in a 77-year-old woman who had a superior right posteriolateral tumefaction for 15 years. The hernia cure was prosthetic made by the sandwich technique. No recurrence was observed after 25 months of follow-up. Through a review of the literature, we reveal the diagnostic and therapeutic difficulties.

Keywords

Lumbar Hernia, Colonic Occlusion, Treatment

1. Introduction

Lumbar hernias (LH) are defects of the posterolateral abdominal wall [1]. They occur between the 12th rib and the iliac crest [2]. This is an entity suggested since 1672 by Bardett and only 250 to 300 cases have been described in the English literature until 1995 [2] [3] [4] [5]. Elsewhere, 62 cases and 11 cases have been described in Japanese and Korean literature [2]. The scarcity of these LH with very serious complications has the following consequences: the lack of publication devoted to them, the large number of short series and the absence of a well-defined therapeutic modality in the publications [3] [6] [7]. We report a

case of superior HL (Grynfeltt's hernia) in a 77-year-old woman. Through a review of the literature, we reveal the diagnostic and therapeutic difficulties, and also the therapeutic modalities.

2. Observation

A 77-year-old housewife and widow living in Abidjan at her daughter's house was being led by her in the digestive and proctological surgery emergency department of Treichville University Hospital for abdominal pain that had been evolving for three days. The interrogation on April 16th 2016 revealed nausea for two days and a complete stop of intestinal transit for twenty-four hours. It was found the antecedents of blood pressure on medical treatment and a posterolateral superior lumbar mass. This mass evolved for 15 years. The patient had 6 gestities and 5 parities. No antecedent of lumbar or abdominal trauma was found. In addition she did not present any deformity or infirmity of congenital or acquired origin.

The temperature was 38°C, the blood pressure 110/06 mm Hg and the pulse at 128 beats/min and a body mass index of 33 kg/m².

The physical examination revealed in this patient with a good general condition a diffuse, immobile and tympanic abdominal meteorism. The rectal examination did not find any tumours in the anal canal and rectal ampulla. The rectum was empty. The fingertip was not covered with blood. An oval longitudinal mass of 6 cm by 10 cm was perceived at the right upper lumbar part. This mass was not expansible to cough, not reducible, but a little sensitive. Moreover, auscultatory silence was noted at this mass (**Figure 1**). There was no umbilical hernia nor a white line hernia. The hernia orifices in the groin were free. An abdominal x-ray found multiple peripheral hydroaeric images of colonic type (**Figure 2**).

The biological assessment showed a hemoglobin level of 12 g/dl, a discrete hyperleukocytosis of $11.5 \times 10^3/\text{ml}$ predominantly polynuclear neutrophilic (79%). The ionogram and renal status were normal.

An echography of the lumbar mass was performed which has not been contributory to the diagnosis. An abdominopelvic scan (CT) was prescribed after the start of resuscitation measures. It diagnosed a LH of Grynfeltt (**Figure 3** and **Figure 4**).

In left lateral decubitus after general anesthesia a transverse incision was made on the hernia. After dissection of the subcutaneous tissue, there was an incarcerated colonic loop with a very tight hernial neck (**Figure 5**). The viable intestinal loop was reintegrated into the abdomen after incision of the neck (**Figure 6**). The parietal repair was made by 2 cuts of Mersuture mesh of 5 cm by 10 cm fixed one in pre-peritoneal and the other between the musculo-aponeurotic elements of the parietal defect. A drainage of the subcutaneous hernial cavity with a Delbet blade, a cutaneous closure then a compressive bandage put an end to the intervention.

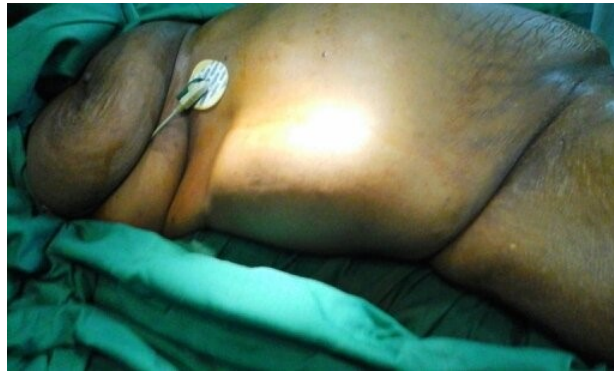

Figure 1. Superior righth posterolateral mass.

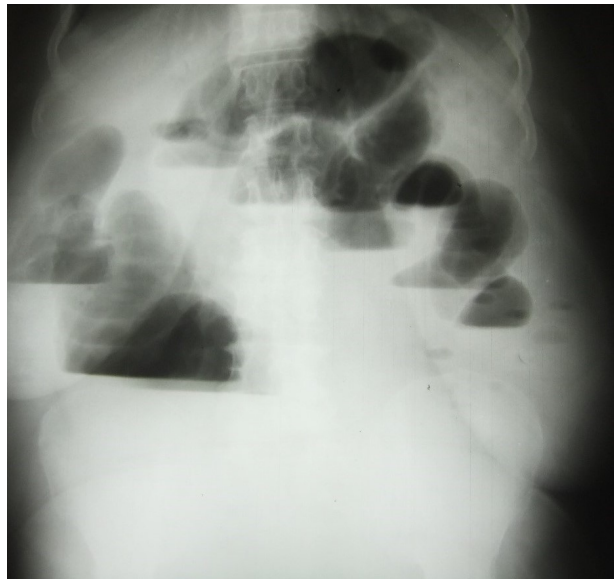


Figure 2. Hydroaeric levels of colonic type on abdominal x-ray.

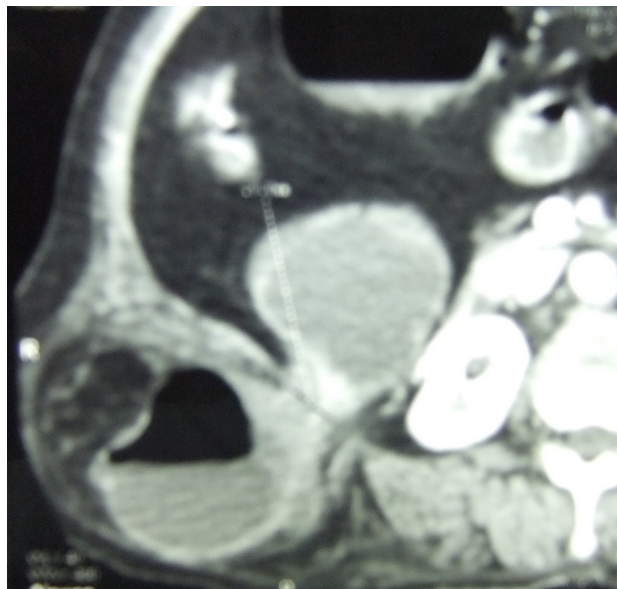


Figure 3. Transversal section CT of right Grynfeltt hernia.

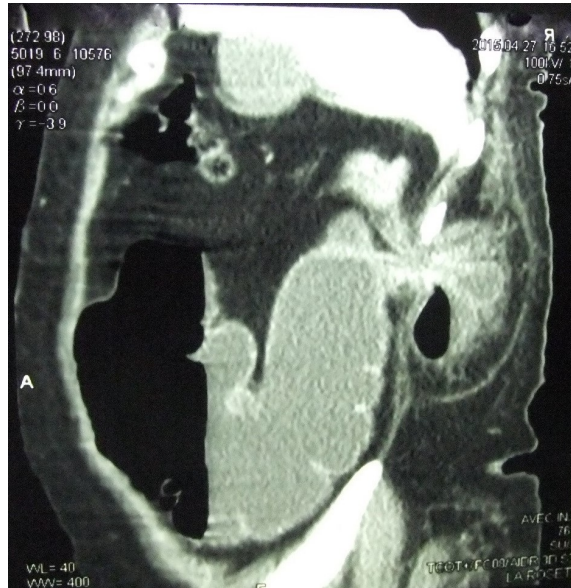


Figure 4. Longitudinal section CT of Grynfeldt hernia.

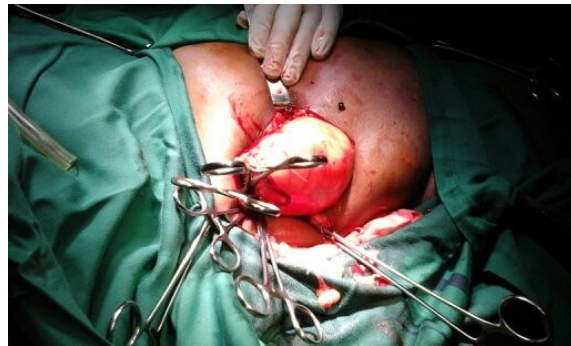

Figure 5. Colonic content of Grynfeldt hernia.

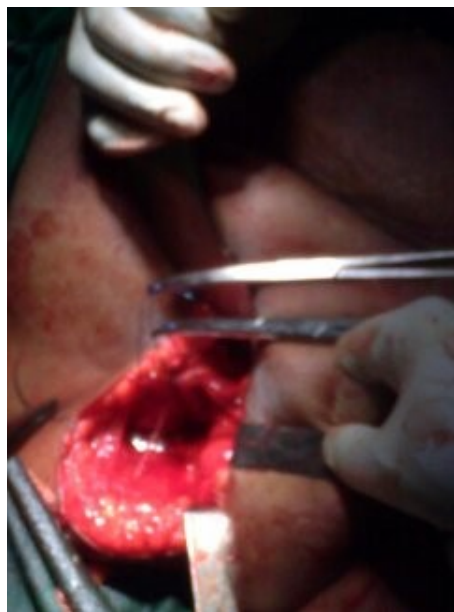

Figure 6. Grynfeldt hernia's orifice after reduction of colonic content.

The postoperative course was simple. The patient was discharged at postoperative D3 and followed for 25 months without recurrence.

3. Discussion

LH represent 2% to 3% of hernias of the abdominal wall [6]. They most often affect the elderly subject. Baraket [4], Mbalor [3] and Alves [1] find mean ages of 78, 67 and 58 years with extremes of 70 - 86 years, 54 - 84 years and 54 - 63 years. They concern younger subjects (around 40 years old) when they are traumatic or postoperative [8] [9] [10]. men are a little more affected [3] [5] [8] [11].

LH are mainly in two locations: at the top of the 12th rib (Grynfeltt hernia); our observation and below the iliac crest (Hernia of Jean Louis Petit) [3] [6]. Grynfeltt hernia represents 95% of HL [4] [6] [10]. The location on the left would be preponderant [8].

LH are congenital or acquired [2] [3]. Congenital HL are often associated with malformations or a lumbar vertebral deficit syndrome, a meningocele and a neurofibromatosis [3] [5]. They represent 20% of cases of LH [3] [5].

The acquired LH are subdivided into primary (or spontaneous) LH and secondary LH (or eventrations) [2] [7]. Primary LH, which is probably the case for our patient, is the most common, accounting for 50% to 55% of cases [3] [5]. The causes include older age, obesity, excessive weight loss, intense physical activity, abdominal hyperpressure, multiple pregnancies, and debilitating disabilities [2] [3] [5]. Secondary LH (25% to 30% of cases) are due to: lumbar trauma, surgery (lumbotomy for: nephrectomy, aneurysm, iliac bone graft and musculocutaneous flap of the latissimus dorsi) and infections (lumbar tuberculosis, poliomyelitis) [3] [5] [10] [11].

Clinically, it is a lumbar tumefaction high (Grynfeltt) or low (Jean Louis Petit), gradually increasing volume, sometimes seat of small ulcers when the tumefaction has been treated by pharmacopoeia (poultices and decoctions) [4]. It is impulsive, expansive to cough and effort, incompletely reducible in lateral decubitus and seat of filtration noise and hydro-aeric tinnitus on auscultation [2] [4] [11]. Only 25% of LH have an organ incarceration (intestine, kidney, omentum) suggesting that less than 25% of LH are likely to have the above auscultatory signs.

Ultrasonography, a dependent manipulative examination that has not been contributory in the case of our patient, may show parietal defect and possibly Brownian motions [3] [5] [11]. CT at best MRI is used to visualize the defect, the content, the report and the state of the wall of the hernia [2] [8] [11]. The old LH are bulky and the diagnosis is most often easy and clinical [2] [4]. Young HL is most often asymptomatic [4] [5]. It then mimics a cold abscess, a lipoma or even a renal tumor [3] [5]. The diagnosis of these asymptomatic cases without history is based on a strong index of clinical suspicion [7]. Otherwise the LH will be revealed by its strangulation [4]. In all cases, CT or MRI are indispensable [2] [6]

[11]. In addition to making the diagnosis, they give an orientation on the operative technique to be used [4] [6] [8].

The surgical indication is formal in front of any LH because of the risk of strangulation, even of necrosis [1] [3] [6]. Treatment of LH is often difficult because of the lack of a standard of care, difficulties in defining the musculo-aponeurotic defect, poor quality tissue and inexperience of teams [2]. In the adult the intervention will be as soon as possible and in the newborn after 6 to 12 months of life [5]. The surgical approach can be lumbar by a transverse incision on the hernia [3]. The laparoscopic approach is either transperitoneal or retro-peritoneal [2]. This technique seduces by its simplicity and minimally invasive character [8].

The repair of the parietal defect is done by musculo-aponeurotic suture especially when the parietal defect is small [1] [3] [4]. The risk of recurrence remains high [1] [4]. It can be done by a muscular plasty that requires extensive and tedious dissection [8]. The current treatment trend is prosthetic [4]. It uses propylene mesh in the shape of a quadrilateral or triangle (dart) [11] [12]. The prosthesis may be unique and fixed preperitoneal or double fixed preperitoneal on the one hand and secondly interposed between parietal musculo-aponeurotic structures (sandwich technique) [2].

The complications are dominated by the appearance of hematoma and parietal suppurations, hence the need for good drainage and compressive bandage as in our patient [11]. At best the closure of the wall will be under negative pressure [11]. The hospital stay is generally short, 4.2 days on average as in our patient [3] [4]. In addition, early recurrences would be frequent in case of repair by suture [1] [4].

4. Conclusion

Rare hernias of the abdominal wall, the LH in general and the Grynfeltt hernia in particular are most often acquired and primitive. The diagnosis of the young hernia is based on a strong index of suspicion. It will be necessary to think about it before any occlusion associated with a lumbar tumefaction for the evolution is enamelled of strangulation.

Conflicts of Interest

The authors declare no conflicts of interest regarding the publication of this paper.

References

- [1] Alves, A.Jr., Maximiano, L., Fujimura, J.E., Pires, P.W. and Borolini, D. (1995) Grynfeltt Hernia. Case Report and Review of the Literature. *Revista Hospitalar-Clinica da Faculdade de Medicina de São Paulo*, **50**, 111-114.
- [2] Lim, M.S., Lee, H.W., Yu, Ch. and Yang, D.H. (2011) Extra-Peritoneal Laparoscopic Treatment of Lombar Hernias. *Coreenne Society Journal of Surgery*, **81**, 287-290. <https://doi.org/10.4174/jkss.2011.81.4.287>

- [3] Mgbakor, A.C., Bami, G., Barthe, L., Bledé, A., Diakité, L., Gnaba, S., Kata, J.K., Rouelle, P.H. and Seidou, A. (1999) Diagnostic Difficulties of Lumbar Hernias: About 07 Cases. *Médecine d'Afrique Noire*, **46**, 334-336.
- [4] Baraket, O., Berriche, A., Zribi, R. and Chokki, A. (2011) Lumbar Hernias. Analysis of 3 Cases. *Tunisie Médicale*, **89**, 644-646.
- [5] Renk, D.V., De Moraes, G.L. and Lopes, Jr.J.I. (2009) Grynfeldt-Type Secondary Acquired Lumbar Hernia: Case Report. *Radiologia Do Brasil*, **42**, 546-547.
- [6] Okiemy, G., Ele, N. and Mackoumbou-N'Kounka, A. (2006) Bilateral Lumbar Hernia of the Petit Triangle. About a Case. *Médecine d'Afrique Noire*, **5303**, 142-144.
- [7] Skrekas, G., Stafyla, V.K. and Papalois, V.E. (2005) Grynfeldt Hernia. Report of a Case. *Hernia*, **9**, 188-191. <https://doi.org/10.1007/s10029-004-0278-6>
- [8] Bianche, N., Hardwigsen, J., Moura, P., Peyene, T. and Le Treut, Y.P. (2006) Hernia of the Triangle of Jean Louis Petit: Interest of Laparoscopic Repair. *Journal de Chirurgie*, **3**, 143.
- [9] Delabrousse, E., Sarliève, P., Rodière, E., Michalakis, D., Boulahdour, Z. and Kastler, B. (2005) Colonic Occlusion on Lumbar Hernia Secondary to a Flap Sampling of the Great Right Dorsal Muscle. About a Case. *Journal de Radiologie*, **86**, 167-169. [https://doi.org/10.1016/S0221-0363\(05\)81338-1](https://doi.org/10.1016/S0221-0363(05)81338-1)
- [10] Luna, B.M.E., Bello, F.J.F. and Diaz, R.A. (2003) Bilateral Grynfeldt's Hernia. About a Case. *Revista Médica del IMSS*, **41**, 339-344.
- [11] Sahoo, M.R. and Anil, K.T. (2013) Treatment of Lumbar Hernia by the Sandwich Method: A New Technique. *International Journal of Case and Image Reports*, **4**, 243-247. <https://doi.org/10.5348/ijcri-2013-05-304-CS-1>
- [12] Solaini, L., Francesco, F. and Gourgiotis, S. (2010) A Very Simple Technique for the Treatment of Grynfeldt-Lesshaft Hernia. *Hernia*, **14**, 439-441. <https://doi.org/10.1007/s10029-009-0566-2>