

Comparative Study of Bovine Pericardium and Gore-Tex in Tissual Interaction with Wistar Rats Diaphragm

Artur Fracassi Guerra¹, Mauro Razuk Filho¹, Neil Ferreira Novo², Willy Marcus França^{3*}

¹Medical Science and Health Faculty, Catholic University of São Paulo, São Paulo, Brazil

²Department of Medicine—Service of Statistical Studies, São Paulo, Brazil

³Department of Medicine, Catholic University of São Paulo, São Paulo, Brazil

Email: *willy@drwilly.com.br

How to cite this paper: Guerra, A.F., Filho, M.R., Novo, N.F. and França, W.M. (2016) Comparative Study of Bovine Pericardium and Gore-Tex in Tissual Interaction with Wistar Rats Diaphragm. *Surgical Science*, 7, 381-389.

<http://dx.doi.org/10.4236/ss.2016.79055>

Received: July 15, 2016

Accepted: September 9, 2016

Published: September 13, 2016

Copyright © 2016 by authors and Scientific Research Publishing Inc. This work is licensed under the Creative Commons Attribution International License (CC BY 4.0).

<http://creativecommons.org/licenses/by/4.0/>



Open Access

Abstract

Introduction: Simple suture isn't always possible in large congenital diaphragmatic hernia (cdh) defects. Synthetic materials are used for correction such as Silastic®, Gore-Tex® (GT), Teflon® or biological, such as autologous muscle patches. It was shown that bovine pericardium (bp) was effective to correct those large defects with many positive outcomes when compared with syntactic materials. **Aim:** This study aims to establish an experimental model of correction for large diaphragmatic defect with PB and GT patches to compare histologically the tissue interaction between them and diaphragm in young Wistar rats. **Materials & Methods:** 15 wistar rats were divided in 3 groups: Rats that used BP was named **G1**; Rats that used GT was named **G2**; and rats with only scraping in the diaphragm, named **G3** (control). Animals were submitted to a laparotomy and fixed patches to diaphragms and harvested 3 weeks later. Area between normal diaphragm and patches were isolated and separated for histological analysis, such as lymphocytic infiltration (inflammation), neovascularization and fibrosis. **Results:** G1 presented inflammation between BP and Diaphragm In 5 Samples. G2 Presented Neovascularization In 5 Samples, But No inflammation. Fibrotic tissue overlapping GT patches occurred in 3 samples in G2. Comparing G1 with G2 there was a significant statistical difference concerning inflammation ($P = 0.0079$), in G1. Comparing neovascularization there is no significant statistical difference ($P = 0.4444$), despite a slight higher incidence in G2. Fibrosis in both groups presented no significant statistical difference ($P = 0.4444$), despite a slight higher incidence in G2. There were no alterations in G3. **Discussion:** Despite the statistical difference in the inflammatory process was more frequent in G1 ($P = 0.0079$), neovascularization and fibrosis were more frequent in G2. **Conclusion:** The proposed experimental model was satisfactory to reproduce

suture of patches in the diaphragm. These results suggest that inflammation, neovascularization and fibrosis indeed contribute to a benign healing process that reacts differently in each group but can drive to more lasting and permanent results when biological patch is considered. Statistical report suggests that this study should be continued with a larger sample of animals and a wider period of time before harvest.

Keywords

Diaphragm Hernia, Bovine Pericardium, Gore-Tex, Tissue Interaction and Wistar Rat

1. Introduction

Since Neville *et al.* (1954) published the correction of large diaphragmatic defects by suturing an hepatic lobe on the endothoracic fascia, other attempts have been suggested to correct these defects by using synthetic materials, as Silastic®, polytetrafluoroethylene, Gore-Tex® (GT) and Teflon® [1]-[3]. However, use of these materials has not always led to the expected outcomes given the recurrent herniation, no-growth of synthetic material and the need for another future definitive surgery [2] [3].

Autologous tissues, such as muscles including tissues of the abdominal wall and the large dorsal muscle, were used with good results. Bedini *et al.* (1997) and Samarakkody *et al.* (2001) described in two different papers a few cases in which the large dorsal muscle was used. Biological materials, such as lyophilized duramater, were described as methods to correct diaphragmatic defects, but 20% of hernia recurrence occurred. Thus, it was concluded that this is not the ideal material to close these defects [4].

Other biological materials were tested in experimental studies aiming the investigation their effectiveness in the correction in large diaphragmatic defects, such as: Small intestine submucosa, acellular dermis both in *Sprague-Dowley* rats [5], and also in dog fascia lata [6].

Gallo *et al.* (1982) published an experimental study using bovine pericardium (BP) preserved in 4% glutaraldehyde solution to correct diaphragmatic defects in 15 dogs. According to these authors, there were no adhesion formation between BP and adjacent structures in all dogs but one in which the omentum adhered to BP [7] [8].

Another experimental study in rabbits concluded that BP is resorbed and substituted by the host's resistant fibrous tissue. Moreover, BP is considered a more appropriate biological material to repair hernia with improved tissual incorporation, lower adherence degree and absence of wrinkles as the result of the transplant material when compared to Marlex® [9].

Another advantage is BP longevity. Basseto *et al.* (2011) and Kim *et al.* (2012) published studies with patients treated with this material more than 20 years and 10 years ago, respectively [10] [11]. A case report published by the authors in 2007 (Pinheiro DFC, 2007; Basseto S. *et al.*, 2011) describes a patient treated with BP to correct a 14 yo

gigantic congenital diaphragmatic hernia [10] [12].

BP is currently largely used in cardiovascular surgeries due to its moderate elasticity, high resistance to traction, easy manipulation and doesn't require the use of immune-suppressors [12].

Gore-Tex® is among the synthetic fabrics that are frequently utilized to repair defects in human beings by providing greater accumulation of neutrophils [13]. Given its easy handling, flexibility, readily obtainable, good adherence; it is used as support for the growth of fibrous tissue and doesn't set off infection signs [14]. Notwithstanding, in developing organisms, it might not grow with the children and, consequently, it might result in abnormalities, especially thoracic deformities together with respiratory diseases [15] [16].

The present study aims to establish an experimental model of correction for large diaphragm defect and comparing histologically the tissue interaction between BP and GT in the Wistar rat's diaphragms.

2. Material and Methods

This study was approved by the Ethics in Research in Animal Experimentation Committee of the Catholic University of São Paulo, Medical and Health Science Faculty.

After 24-hour acclimation in the vivarium, Wistar rats, 30 days up to two months old, average weight 200 g each were submitted to general anesthesia with Ketamine base—50mg/ml (Ketalar®-Cristália of Brazil), associated to Xylazine 10 mg/ml (Coopazine®-Coopers Brazil *Ltda.*). A volume of 0.4 ml of anesthetic per animal was injected intramuscularly in the thigh lateral muscles with insulin syringe and a 20 G needle. This anesthetic composition (175 mg/kg Ketamine and 2.5 mg/kg Xylazine) maintains the animal under profound anesthesia during a period of three hours and painless post-operative period of 6 to 12 hours.

The rats in all groups were submitted to left subcostal laparotomy to expose the diaphragm. Bowel loops were moved down to lower regions of the abdomen to allow proper visualization of the animal left diaphragm simulating manipulation of the bowel loops to the abdomen as in a real diaphragmatic hernia surgery.

Small BP or GT patches with approximately 1 cm in diameter were sutured with polypropylene 6 - 0 with simple and separated stiches under the rat's left diaphragm according to the group. Care was taken to avoid diaphragm lesion in order to prevent pneumothorax (Figure 1).

The animals were divided in three groups:

- **Group 1 (BP)** composed of 05 animals that had BP patch sutured on the diaphragm with a 6-0 polypropylene cord with simple separated stiches;
- **Group 2 (GT)** composed of 05 animals that had GT patch sutured on the diaphragm with a 6-0 polypropylene cord with simple and separated stiches;
- **Group 3 (S):** or **Sham** group, composed of 05 animals whose diaphragms were wounded by scraping with anatomical tweezers to their full extent, similar to the length of BP and GT patches sutured in rats of G1 and G2.

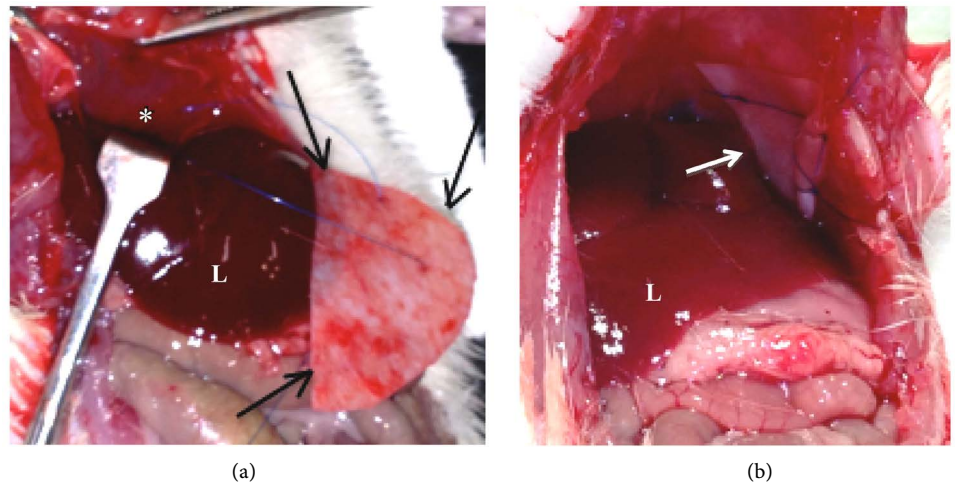


Figure 1. (a) shows BP patch® (black arrows) as it is sutured on the diaphragm (*) and (b) shows Gore-Tex® (white arrow) already sutured on the diaphragm. Liver (L).

Three weeks later all the animals were sacrificed and the diaphragms with their respective patches were removed and preserved in formalin 10% for histological analysis in Hematoxylin and Eosin.

Statistical analysis used was the Fischer's Exact Test (Siegel, 2006), for small sample, once it is an under-graduation research that can explain why sample is limited, despite the important results. Significance was noticed with $p < 0.05$.

3. Results

Histologic analysis showed in the rats of G1 the presence of lymphocytic infiltration (inflammation) in the very limit between BP and the diaphragm (Figure 2), no edema, preserved blood vessels and specifically abundance of small caliber veins, indicating a possible neovascularization, as shown in Figure 3.

All data can be seen in Table 1, where comparison between G1 and G2 are clearer concerning lymphocytic infiltration (inflammation), neovascularization and fibrosis, (Table 1).

In G1 animals can be seen the presence of inflammation right in the edge between BP patch and diaphragm in all 5 samples, but neovascularization was found in only in 3 samples, where one of them had associated fibrosis. G2 presented neovascularization in 5 samples, but no samples with inflammation. Fibrotic tissue overlapping GT patches occurred in 3 samples in G2, such as well-delimited fibrotic capsules.

When comparing G1 × G2 there was a significant statistical difference concerning inflammation ($p = 0.0079$), in G1. When comparing neovascularization in G1 × G2 were obtained no significant statistical difference ($p = 0.4444$), between both groups, despite a slightly higher incidence in G2. When comparing G1 × G2 concerning fibrosis, there no significant statistical difference ($p = 0.5238$), despite a slightly higher incidence in G2. There were no alterations in G3 (Table 1).

It was possible to visualize the formation of fibrotic tissue in the sections on the G2

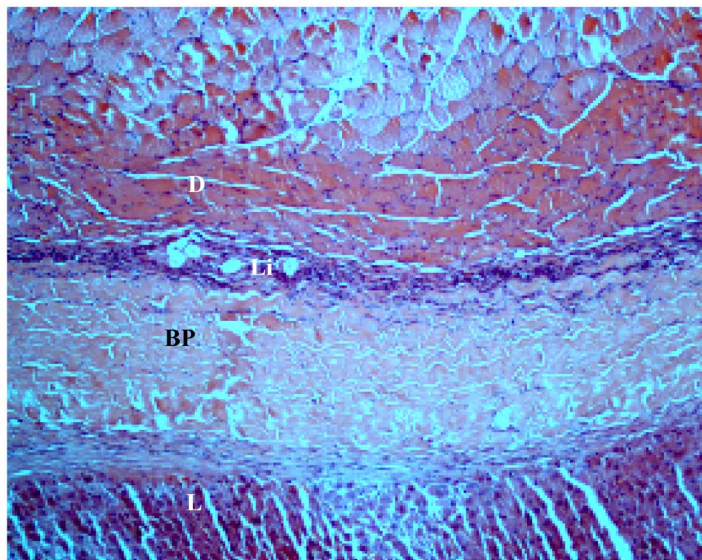


Figure 2. Shows BP patch between the diaphragm and the liver (L) of the Wistar rat with lymphocytic infiltrate (Li) between the D and BP, 100 \times .

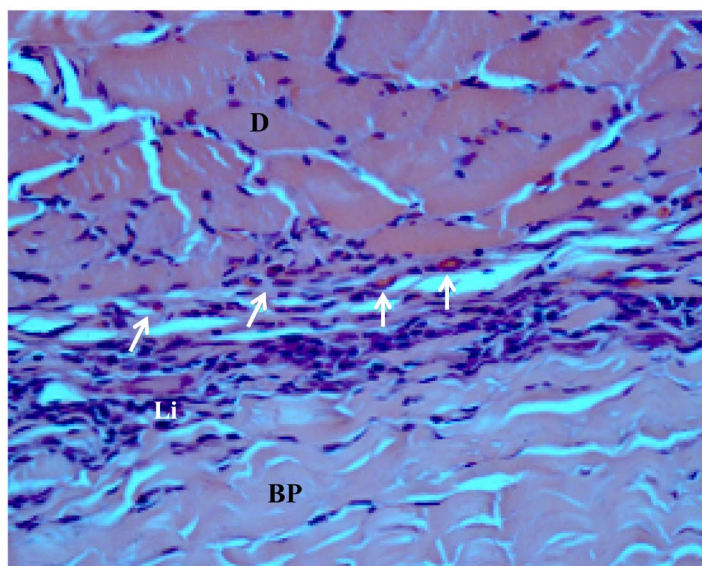


Figure 3. Lymphocytic infiltration (Li) between the diaphragm (D) and bovine pericardium patch (BP), in G1. White arrows show small caliber veins (*neovascularization*), 400 \times .

Table 1. Presents the distribution of histological changings concerning inflammatory infiltration, neovascularization and fibrosis in all groups.

HISTOLOGY	G1 (PB)		G2 (GT)		G3 (Control)		<i>p</i>
	N	%	N	%	N	%	
Inflammation	5	100	0	-	0	-	0.0079
Neovascul.	3	60	5	100	0	-	0.4444
Fibrosis	1	-	3	-	0	-	0.5238

patches (Figure 4). There are (well delimited) fibrotic capsules and formation of vases showed in Figure 5.

In the histological analysis of the rats in G3 (Control), it is possible to visualize a complete diaphragm recovery with no Lymphocytic infiltration (inflammation), neo-vascularization or fibrotic scars (Figure 6).

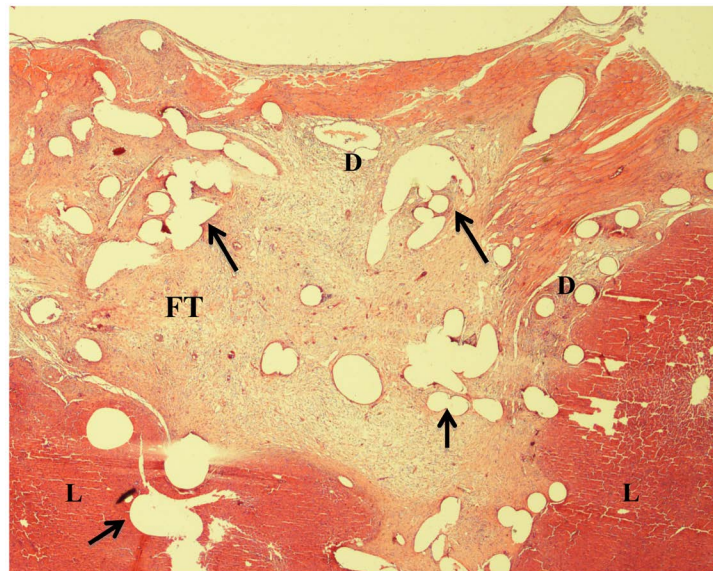


Figure 4. Fibrotic tissue (FT) overlapping GT between the diaphragm (D) and the liver (L), and the presence of new blood vessels (arrows), 200×.

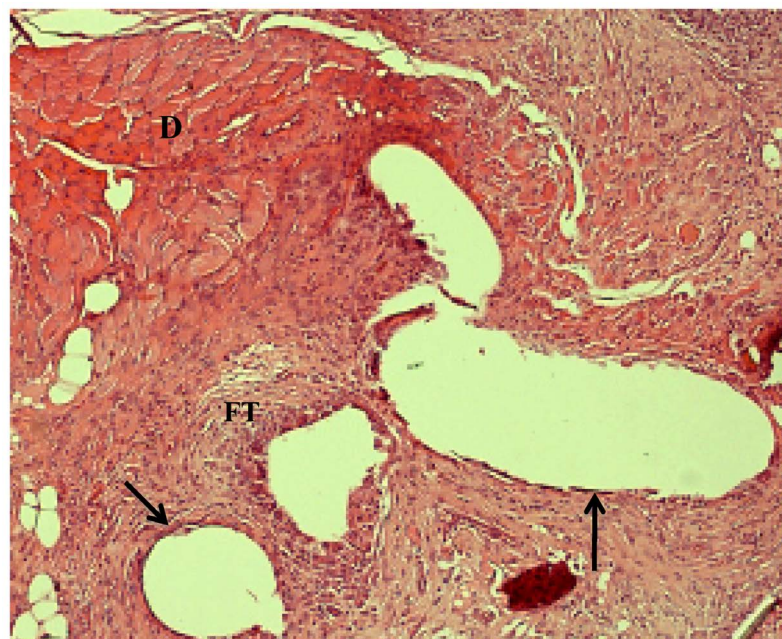


Figure 5. Transition between diaphragm (D) and the fibrotic tissue (FT) overlapping GT patch. Well-delimited fibrotic capsules (FC), small caliber blood vessels (arrows) do exist, and lymphocytic infiltration is absent. 100×.

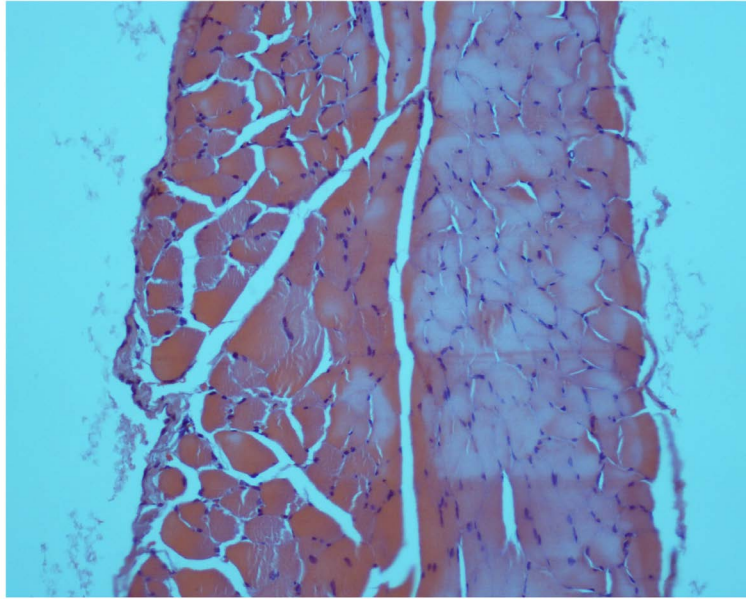


Figure 6. Intact diaphragm after scraping on G3-200x.

4. Discussion

Synthetic materials are relatively easy to suture, have good resistance and can be placed as a dome shape and apparently guarantee an improved diaphragmatic function when compared to what the flat material would guarantee [1] [2]. Despite all these advantages, several complications are described in the literature, such as: material displacement, hernia resurgence and thoracoabdominal deformities [3].

Several authors described the advantages of muscle autologous correction in for large CDH defects [4]. Muscles, such as distal *latissimo dorsi*, were used with good results. However, several newborns with CDH need extra-corporeal membrane oxygenation (ECMO) support which involves systemic anticoagulants and the need for extensive dissection would put these children at a high bleeding risk [3].

Bovine pericardium seems to concentrate all the features of muscles and all the features of synthetic materials (resistance, easy manipulation and can be placed as dome shape) [9]-[11]. Furthermore, BP is a biological material that is capable of growing with the child without induce deformities or mutilation such as the autologus muscle patches and without the need for other surgeries for substitution [12] [13].

In the present study the inflammatory process in the G1 animals showed significant statistical difference concerning inflammation ($p = 0.0079$), when compared to G2 that had no inflammation. Inflammation is known as the first step for a normal wound healing and this is presented in 100% of G1 animal and can suggest a better cicatrization process. Despite we had only one animal in G1 that presented fibrosis, suggesting adhesion, Gallo *et al.* (1982) published that there were no adhesion formation between BP and adjacent structures in all dogs but one in which the omentum adhered to BP [7] [8].

Neovascularization has not been published yet in the literature about this kind of tissue interaction, but in the present study we had 3 animals in G1 and 5 animals in G2 that presented neovascularization in the edge between patches and diaphragm, but with no significant statistical difference ($p = 0.4444$). Neovascularization (*angiogenesis*) is the second phase of a normal healing and would suggest that incorporation of the patch is going well.

Once fibrosis is the last step for a normal healing the patches of both groups were expected to have a good or even more frequent fibrosis around the patches. This study presented only 1 animal in G1 and 3 animals in G2 that presented fibrosis, but with no significant statistical difference ($p = 0.5238$). This could be result of a short time for the harvest day (3 weeks), specially in G1 that inflammatory process is more frequent. Maybe G1 would need a little more time to establish a proper fibrosis.

5. Conclusion

In conclusion, the proposed experimental model was satisfactory to reproduce suture of patches in the diaphragm. These results suggests that inflammation, neovascularization and fibrosis indeed contribute to a benign healing process that respond differently in each group but can drive to a more lasting and permanent results when consider a biological patch. Statistical report suggests that this study should be continued with a larger sample of animals and a wider period of time before harvest.

Acknowledgements

In appreciation for the Scientific Initiation fellowship granted to the Biologist Luciana Canabarro for her invaluable help with laboratory practices; to Mrs. Elizabeth de Almeida for preparation of tissue slides for microscopy examination and to all the team of the Biomaterial Laboratory at FCMS/PUC-SP.

References

- [1] Neville, W.E. and Clowes Jr., G.H.A. (1954) Congenital Absence of Hemidiaphragm and Use of Lobe of Liver in Its Surgical Correction. *AMA Arch Surg*, **69**, 282-290. <http://dx.doi.org/10.1001/archsurg.1954.01270030010002>
- [2] Stolar, C.J.H. and Dillon, P.W. (1998) Congenital Diaphragmatic Hernia and Eventration. In: O'Neill Jr., J.A., Rowe, M.I., Grosfeld, J.L., Fonkalsrud, E.W. and Coran, A.G., Eds., *Pediatric Surgery*, 5th Edition, Mosby-Year Book, St. Louis, 819-837.
- [3] Sripathi, V. and Beasley, S.W. (1992) Familial Occurrence of Complete Agenesis of the Diaphragm. *Journal of Paediatrics and Child Health*, **28**, 190-191. <http://dx.doi.org/10.1111/j.1440-1754.1992.tb02640.x>
- [4] Faivre, L., Morichon-Delvallez, N., Viot, G., *et al.* (1998) Prenatal Diagnosis of a Fetus with a Diaphragmatic Hernia and Review of the Literature. *Prenatal Diagnosis*, **18**, 1055-1060. [http://dx.doi.org/10.1002/\(SICI\)1097-0223\(199810\)18:10<1055::AID-PD405>3.0.CO;2-I](http://dx.doi.org/10.1002/(SICI)1097-0223(199810)18:10<1055::AID-PD405>3.0.CO;2-I)
- [5] Gibbs, D.L., Rice, H.E., Farrell, J.A., *et al.* (1997) Familial Diaphragmatic Agenesis: An Autosomal-Recessive Syndrome with a Poor Prognosis. *Journal of Pediatric Surgery*, **36**, 366-368. [http://dx.doi.org/10.1016/S0022-3468\(97\)90212-8](http://dx.doi.org/10.1016/S0022-3468(97)90212-8)

- [6] Sadler, T.W. (1995) Cavidades do Corpo. In: Sadler, T.W., Ed., *Langman. Embriologia Médica*, 13th Edition, Guanabara Koogan, São Paulo, 108-114.
- [7] Gallo, J.I., Artinano, E., Val, F. and Duran, C.G. (1982) Glutaraldehyde-Preserved Heterologous Pericardium for the Repair of Diaphragmatic Defects: Experimental Study. *The Journal of Thoracic and Cardiovascular Surgery*, **83**, 905-908.
- [8] Adzick, N.S., Harrison, M.R., Glick, P.L., Nakayama, D.K., Manning, F.A. and de Lorimier, A.A. (1985) Diaphragmatic Hernia in the Fetus: Prenatal Diagnosis and Outcome in 94 Cases. *Journal of Pediatric Surgery*, **36**, 357-361.
[http://dx.doi.org/10.1016/S0022-3468\(85\)80219-0](http://dx.doi.org/10.1016/S0022-3468(85)80219-0)
- [9] Bedini, A.V., Valente, M., Andreani, S., et al. (1997) Reverse Flap of Distal Latissimus Dorsi for Diaphragm Reconstruction in the Adult: Specification of the Technical Procedure and Report on Six Cases. *The Journal of Thoracic and Cardiovascular Surgery*, **114**, 846-848.
[http://dx.doi.org/10.1016/S0022-5223\(97\)70091-6](http://dx.doi.org/10.1016/S0022-5223(97)70091-6)
- [10] Bassetto, S., Menardi, A.C., Alves Junior, L., Rodrigues, A.J. and Évora, P.R.B. (2011) Reflexões sobre a durabilidade de 24 anos de uma bioprótese IMC/Braile de pericárdio bovino em posição tricúspide isolada. *Rev Bras Cir Cardiovasc*, **26**.
<http://dx.doi.org/10.5935/1678-9741.20110058>
- [11] Kim, J.H., Cho, Y.P., Kwon, T.W., Kim, H. and Kim, G.E. (2012) Ten-Year Comparative Analysis of Bovine Pericardium and Autogenous Vein for Patch Angioplasty in Patients Undergoing Carotid Endarterectomy. *Annals of Vascular Surgery*, **26**, 353-358.
<http://dx.doi.org/10.1016/j.avsg.2011.10.014>
- [12] Pinheiro, D.F.C., Franca, W.M., et al. (2007) Bovine Pericardium as a Lasting Option to Correct Agenesis of the Left Hemidiaphragm: A Five Year Follow-Up. *Brasília Med*, **44**, 142-145.
- [13] Quitzan, J.G., Rahal, S.C., Rocha, N.S. and Crocci, A.J. (2003) Comparação entre pericárdio bovino preservado em glicerina e malha de poliéster no reparo de falhas da parede abdominal em ratos. *Acta Cir. Bras.*, **18**.
<http://dx.doi.org/10.1590/S0102-86502003000400007>
- [14] Pezzutti, S., Holzchuh, N., Alves, M.R., Holzchuh, M.P. and Holzchuh, R. (2001) Polite-trafluoroetileno e esclera humana no tratamento cirúrgico de perfuração escleral em coelhos. *Arq. Bras. Oftalmol*, **64**, 563-567.
- [15] Lally, K.P., Cheu, H.W. and Vazquez, W.D. (1993) Prosthetic Diaphragm Reconstruction in the Growing Animal. *Journal of Pediatric Surgery*, **28**, 45-47.
[http://dx.doi.org/10.1016/S0022-3468\(05\)80352-5](http://dx.doi.org/10.1016/S0022-3468(05)80352-5)
- [16] Iocono, J.A., Cilley, R.E., Mauger, D.T., et al. (1999) Postnatal Pulmonary Hypertension After Repair of Congenital Diaphragmatic Hernia: Predicting Risk and Outcome. *Journal of Pediatric Surgery*, **36**, 349-353. [http://dx.doi.org/10.1016/S0022-3468\(99\)90207-5](http://dx.doi.org/10.1016/S0022-3468(99)90207-5)



Submit or recommend next manuscript to SCIRP and we will provide best service for you:

Accepting pre-submission inquiries through Email, Facebook, LinkedIn, Twitter, etc.

A wide selection of journals (inclusive of 9 subjects, more than 200 journals)

Providing 24-hour high-quality service

User-friendly online submission system

Fair and swift peer-review system

Efficient typesetting and proofreading procedure

Display of the result of downloads and visits, as well as the number of cited articles

Maximum dissemination of your research work

Submit your manuscript at: <http://papersubmission.scirp.org/>