

Asymptomatic Intrahepatic Portosystemic Venous Shunt: Case Report and Review of Literature

Huylmer Lucena Chaves^{1*}, Mayanna Pinho Batista¹, Germana Bastos Pontes¹, Lia Pontes de Melo¹, José Carlos Godeiro Junior^{1,2}

¹Instituto São Carlos de Ensino e Pesquisa, Fortaleza, Brazil

²Hospital São Carlos, Fortaleza, Brazil

Email: *huylmer@gmail.com

How to cite this paper: Chaves, H.L., Batista, M.P., Pontes, G.B., Melo, L.P. and Godeiro Junior, J.C. (2019) Asymptomatic Intrahepatic Portosystemic Venous Shunt: Case Report and Review of Literature. *Open Journal of Radiology*, 9, 1-9. <https://doi.org/10.4236/ojrad.2019.91001>

Received: December 3, 2018

Accepted: January 4, 2019

Published: January 7, 2019

Copyright © 2019 by author(s) and Scientific Research Publishing Inc. This work is licensed under the Creative Commons Attribution International License (CC BY 4.0).

<http://creativecommons.org/licenses/by/4.0/>



Open Access

Abstract

A spontaneous portosystemic shunt is a rare malformation of the liver vessels. The etiology of these shunts is controversial. They can be divided into acquired (most commonly associated with liver cirrhosis) and congenital. Vascular shunts are asymptomatic in the majority of the patients, and when symptomatic were presented by severe complications. The specific way of management can be selected depended on whether the patient was symptomatic or not, and also on the size of the shunt, shunt ratio and whether it was associated with cancer. We will present a clinical case and discuss the importance of the radiological imaging in the screening, diagnosis and follow up of these anomalies.

Keywords

Intrahepatic Portosystemic Venous Shunt, Venous Shunt, Portal Vein, Ultrasound

1. Introduction

A spontaneous portosystemic shunt is a rare malformation of the hepatic vascularization involving the arterial, portal or hepatic venous systems [1] [2].

The etiology of these shunts is controversial. They can be divided into acquired: associated with cirrhosis and/or hepatocellular carcinoma, related to traumatic injuries to the liver or interventional transhepatic procedures (including liver biopsy, transhepatic cholangiography, or biliary surgery), congenital and idiopathic vascular malformations, as in hereditary hemorrhagic telangiectic-

tasia (Rendu-Osler-Weber syndrome) [1] [3] [4].

Congenital intrahepatic portosystemic venous shunt probably results from abnormal embryonic development by the fourth week of fetal life, by the persistence of communications between the portal and vitelline venous systems [5] [6].

Radiological imaging plays a very important role in the screening, diagnosis and follow-up of these anomalies. Thus, through this clinical case, we will discuss the various radiological aspects of the intrahepatic shunts.

2. Case Report

Patient, male, 69 years old, accompanied in tertiary referral service in hepatology in the liver transplant row due to alcoholic liver cirrhosis. Asymptomatic, with laboratory tests only demonstrating a small elevation of alanine aminotransferase (was 69 U/L, reference ranges: 10 - 50 U/L) and aspartate aminotransferase (was 87, reference ranges: 15 - 45 U/L), he presents for the accomplishment of a total abdomen Doppler ultrasonography as a pre-transplantation routine.

At the examination, the liver presented normal dimensions, with marked contours, heterogeneous parenchymal echogenicity and blunt edges, suggesting chronic diffuse liver disease (Figure 1 and Figure 2).

There were signs of portal hypertension given by superior mesenteric veins, splenic veins and increased caliber portals. Hepatopetal flow of the splenic vein and portal is still observed. The portal vein maintained normal velocity and fasciculation, it was noticed a discreet periportal hyperechogenicity that could represent foci of fibrosis (Figures 3-6).

Spleen with increased dimensions, preserved parenchymal echogenicity, presenting collateral vessels in the splenic cord (Figure 7).

In the hepatic vascularization, dilated right portal branches with increased flow and with shunt to the middle suprahepatic vein were observed, which presented dilation and flow pattern similar to that of the portal vein. The left portal branch showed normal caliber (Figure 8 and Figure 9).

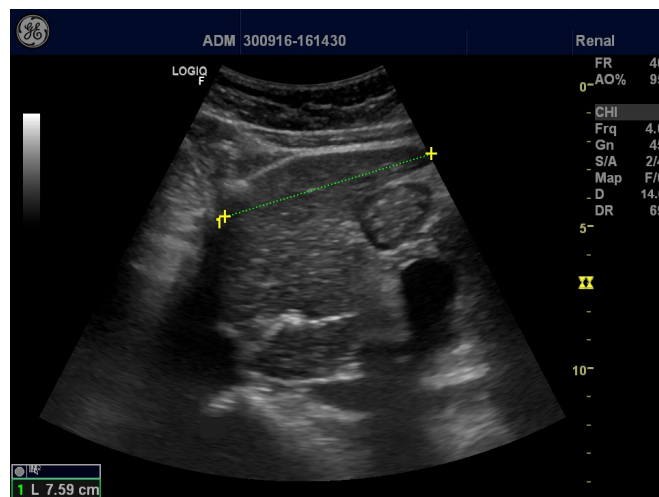


Figure 1. Left hepatic lobe measuring 7.5 cm.

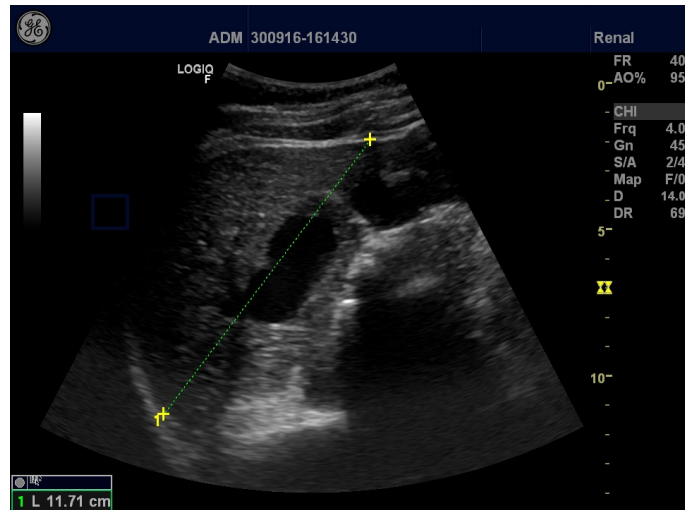


Figure 2. Right hepatic lobe measuring 11.7 cm.

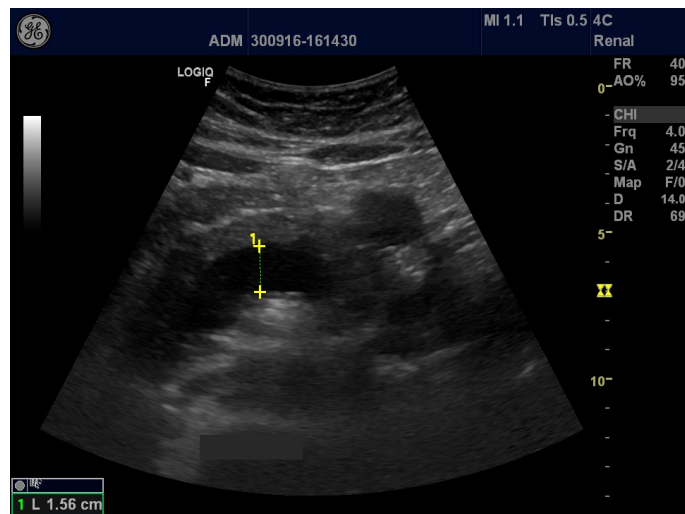


Figure 3. Splenic vein measuring 1.5 cm.

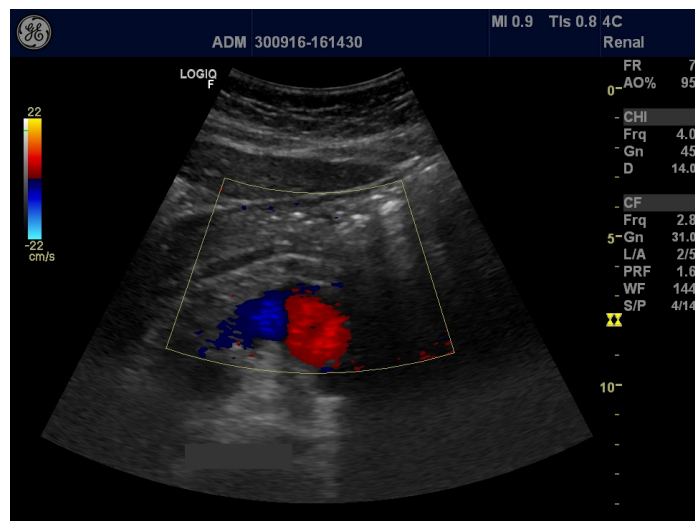


Figure 4. Splenic vein-hepatopetal flow.

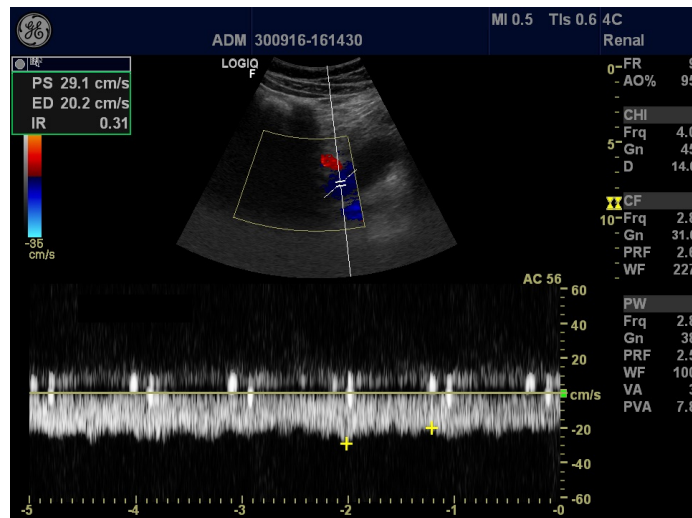


Figure 5. Portal vein-velocity 29.1 cm/2 and fasciculation.

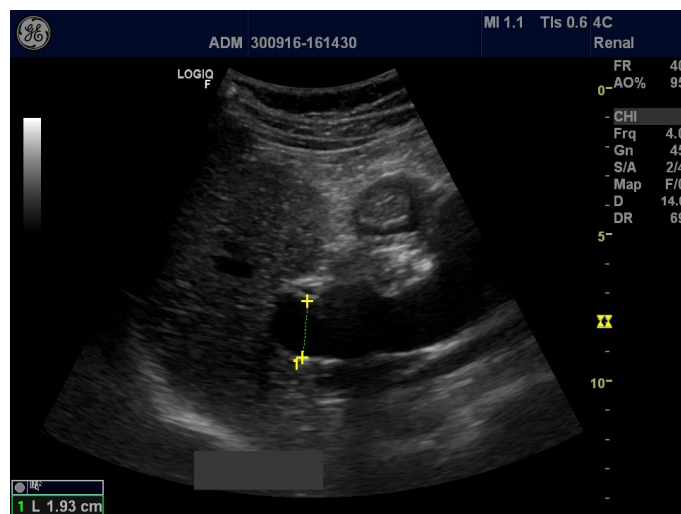


Figure 6. Portal vein-measuring 1.9 cm.

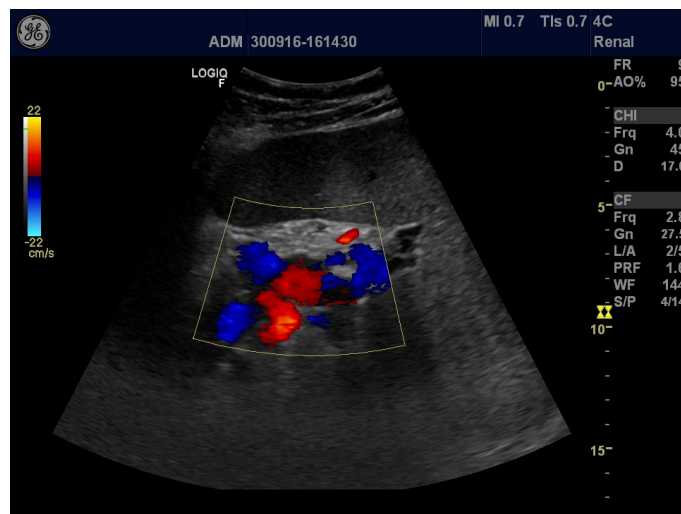


Figure 7. Perisplenic collateral vessels.

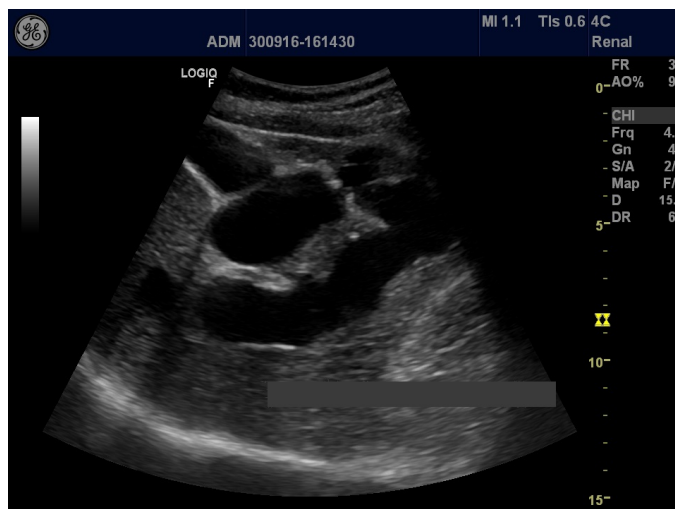

Figure 8. Dilated right portal branches.

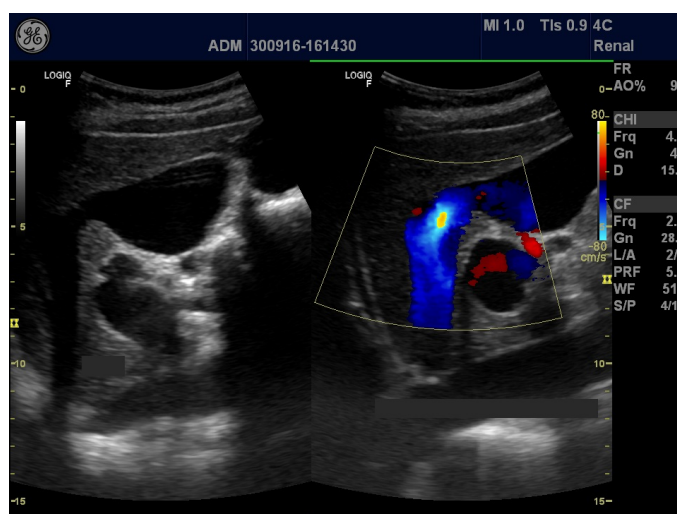


Figure 9. Intrahepatic portosystemic venous shunt-right portal branches to middle suprahepatic vein shunt.

The left and right suprahepatic veins presented normal caliber, spectral pattern and path and no signs of thrombosis.

As the patient was asymptomatic, it was decided to keep an ambulatory follow-up.

The patient accepted a consent form to report his case.

3. Discussion

Portal to systemic venous communications are classified as intrahepatic or extrahepatic [1] [4].

Extrahepatic shunts are more common, may be present in patients with portal hypertension due to cirrhosis and other causes, with the communications through collateral vessels. Intrahepatic shunts are less common and occur between intrahepatic portal veins and systemic veins [7] [8].

The most common cause of intrahepatic shunts is cirrhosis and hepatic tumors (like focal nodular hyperplasia and hepatocellular carcinoma). Its prevalence is unknown, varying in screening studies of patients with risk factors between 0.1% to 4.3% [1] [4]. Other tumor diseases such as Neurofibromatosis type 1 (NF1) has a well-known association with vascular anomalies such as stenoses and aneurysms. The pathogenesis of intrahepatic non-tumorous portosystemic shunts is controversial. Some authors believe them to be result of portal hypertension with varices caused by liver disease or infections [3] [8], theoretically, the shunting of blood from the portal vein to the inferior vena cava may help to decrease portal pressure [2]. Other causes are post-traumatic and iatrogenic [3] [8].

The authors who theorize the congenital cause, owing to persistent vitelline veins and the sinus venosus [4] [5] [6]. During embryologic development, the right umbilical vein involutes and the left umbilical vein forms a direct communication with the ductus venosus (right hepatocardiac channel), bypassing the sinusoidal plexus of the liver, the blood therefore flows from the placenta through the umbilical vein, ductus venosus, into the right hepatocardiac channel (later part of the inferior vena cava) [5] [6]. After birth, the left umbilical vein forms the ligamentum teres and the sinus venosus forms the ligamentum venosum. Both the ligamentum teres and the ligamentum venosum are contiguous to the left hepatic lobe. Possibly these shunts represent persistent developmental communications [5] [6].

There are five types of intrahepatic shunts between the major vessels of the liver were possible including: portal vein to hepatic vein or vena cava (portosystemic venous shunts), hepatic artery to hepatic vein (arteriosystemic shunts), hepatic artery to portal vein (arteriportal shunts), between portal veins (portoportal shunts) and between hepatic veins (hepatic venovenous shunts) [1]. The most common subtype is the portosystemic venous shunts which was the same as the case presented.

We can also classify according to the morphology in: single large shunt that connects the right portal vein to the inferior vena cava (most common); localized peripheral shunt in which one or more communications are found in a single hepatic segment; portosystemic shunt through a portal vein "aneurysm"; diffuse and multiple communications between peripheral portal and hepatic veins in several segments [1] [7] [8].

Some studies shows that intrahepatic vascular shunts are asymptomatic in the majority of the patients, and when symptomatic were presented by severe complications including portal hypertension, portosystemic encephalopathy, and congestive cardiac failure [1] [7]. The encephalopathy is the most common complication.

In an experimental study with rats, was found that portal pressure and extent of portosystemic shunting were correlated a day after the portal vein was partially ligated, but the correlation was absent in cirrhotic portal hypertension [2]. However, the intrahepatic shunts reduce the liver's ability to detoxify blood,

thereby increasing the entry of toxic substances into the brain. In an early experimental study, Vogels *et al.* found that only rats with a portacaval shunt, rather than rats with a sham portacaval shunt, developed encephalopathy after hyperammonemia was induced with infusion of ammonium acetate [6]. Also, reduction in blood flow to the liver may result in fatty degeneration, hepatic dysfunction, and atrophy of the liver [5].

Trying to predict which patients will develop symptoms, it was suggested to calculate the shunt ratio (total blood flow volume in the shunt divided by the blood flow in the portal vein) [5]. When the shunt ratio is less than 30% symptoms associated with IHVS may not develop throughout the life time of the individual. When the shunt ratio exceeds 30%, clinical manifestations may develop at any time. When the shunt ratio exceeds 60% even without manifestations the risk of complications is increased this is an indication for immediate intervention [1].

Ultrasonography with color Doppler is useful in the detection of intrahepatic vascular shunts and it enables recognition of flow direction, flow velocity, and type of blood flow noninvasively. Angiography is an invasive and expensive procedure that previously was the most useful imaging method for the assessment of vascular abnormalities. Considering the fact that liver involvement is asymptomatic in most cases, it was indicated only in selected cases for interventional management [1] [3].

MRI would provide a similar appearance to CT, with the added advantage of MR venography. Nuclear medicine can also be used to calculate the shunt ratio by portal scintigraphy following submucosal rectal injection of iodine-123 iodo-amphetamine [8].

The specific way of management can be selected depended on whether the patient was symptomatic or not, and also on the size of the shunt, shunt ratio and whether it was associated with hepatocellular carcinoma [1].

Angiographic embolization of a spontaneous portosystemic shunt can improve the survival and liver function of cirrhotic patients with recurrent encephalopathy [1] [2].

Transcatheter embolization can be performed using particular embolic agentes (coils, gel foam, histoacryl, Amplatzer vascular plug, and others) and one of three routes to access the intrahepatic portosystemic venous shunts: transileocolic obliteration, percutaneous transhepatic obliteration, retrograde transcaval obliteration [7].

In cases with a preprocedure portal pressure measurement above 32 mm Hg, due to the risk of developing significant acute portal hypertension, some case series recommended gradual closure in two stages and surgical banding of the shunt followed by endovascular embolization [7].

The basics of the procedure, its potential risks and benefits, and an honest discussion that includes the strong possibility that the patient could remain asymptomatic for life needs to take place, before any therapeutic or conservative decision [2].

Children are more resistant to hepatic encephalopathy than adults. In these patients, meticulous clinical and ultrasound follow-up must be performed. Mild metabolic abnormalities associated with a portosystemic shunt can be managed with medical therapy and dietary modifications such as a reduced protein diet [5] [6].

Some studies have suggested screening for patients with risk factor (in the study they were included with cirrhosis, hepatocellular carcinoma, hepatic trauma, transhepatic biliary drainage, patients with family history of Osler-Weber-Rendu's Syndrome and with budd-chiari) followed of three-phase abdominal tomography in case of positivity [1].

The case presented exemplifies the most common subtype of intrahepatic portosystemic venous shunt and brings to light the reminder that not all patients with this condition will be symptomatic, thus suggesting that screening should not be performed only in patients with symptoms.

4. Conclusion

The knowledge of hepatic vascular abnormalities is important for radiologists, since these can be cause of recurrent encephalopathy and treatment resistant, as well as can be found in asymptomatic patients. Other studies should be developed to determine how to follow up these patients and which signs indicate the need for an early procedure.

Conflicts of Interest

The authors declare no conflicts of interest regarding the publication of this paper.

References

- [1] Dessouky, B.A.M., Abd, O.L.E. and Abdel, E.S.M. (2011) Intrahepatic Vascular Shunts: Strategy for Early Diagnosis, Evaluation and Management. *The Egyptian Journal of Radiology and Nuclear Medicine*, **42**, 19-34. <https://doi.org/10.1016/j.ejrm.2011.02.005>
- [2] Qi, X., Ye, C., Hou, Y. and Guo, X. (2016) A Large Spontaneous Intrahepatic Portosystemic Shunt in a Cirrhotic Patient. *Intractable & Rare Diseases Research*, **5**, 58-60. <https://doi.org/10.5582/irdr.2016.01000>
- [3] Mon, H., Hayashi, K., Fukuda, T., Matsunaga, N., Futagawa, S., Nagasaki, M. and Mutsukura, M. (1987) Intrahepatic Portosystemic Venous Shunt: Occurrence in Patients with and without Liver Cirrhosis. *American Journal of Roentgenology*, **149**, 711-714. <https://doi.org/10.2214/ajr.149.4.711>
- [4] Remer, E.M., Motta-Ramirez, G.A. and Henderson, G.A. (2007) Imaging Findings in Incidental Intrahepatic Portal Venous Shunts. *American Journal of Roentgenology*, **188**, 162-167. <https://doi.org/10.2214/AJR.05.1115>
- [5] Chandrasekharan, R., Pullara, S.K., Thomas, T., Kader, N.P. and Moorthy, S. (2016) Congenital Intrahepatic Portosystemic Shunts: Imaging Findings and Endovascular Management. *Indian Journal of Radiology & Imaging*, **26**, 92-94. <https://doi.org/10.4103/0971-3026.178349>

- [6] Papamichail, M., Pizanias, M. and Heaton, N. (2018) Congenital Portosystemic Venous Shunt. *European Journal Pediatric*, **177**, 285-294. <https://doi.org/10.1007/s00431-017-3058-x>
- [7] Palvanov, A., Marder, R.L. and Siegel, D. (2016) Asymptomatic Intrahepatic Porto-systemic Venous Shunt: To Treat or Not To Treat? *International Journal of Angiology*, **25**, 193-198.
- [8] Naidoo, P., Maharaj, N., Naidu, V. and Maharajh, J. (2013) An Unusual Case of Intrahepatic Portosystemic Venous Shunt. *South African Journal of Radiology*, **17**, 57-58. <https://doi.org/10.4102/sajr.v17i2.244>