

# Interstitial Lung Diseases Associated with Connective Tissue Pathologies: Radiologic Features

Houda Gharsalli<sup>1,2\*</sup>, Monia Attia<sup>2,3</sup>, Sawssen Hantous-Zannad<sup>2,3</sup>, Imen Sahnoun<sup>1,2</sup>, Sonia Maalej<sup>1,2</sup>, Leila Douik El Gharbi<sup>1,2</sup>, Henda Neji<sup>2,3</sup>, Khaoula Ben Miled-Mrad<sup>2,3</sup>

<sup>1</sup>Department of Pulmonology, Abderrahmane Mami Hospital, Ariana, Tunisia

<sup>2</sup>University of Tunis El Manar, Tunis, Tunisia

<sup>3</sup>Department of Radiology, Abderrahmane Mami Hospital, Ariana, Tunisia

Email: \*houdagharsalli@yahoo.fr

**How to cite this paper:** Gharsalli, H., Attia, M., Hantous-Zannad, S., Sahnoun, I., Maalej, S., El Gharbi, L.D., Neji, H. and Miled-Mrad, K.B. (2019) Interstitial Lung Diseases Associated with Connective Tissue Pathologies: Radiologic Features. *Open Journal of Respiratory Diseases*, 9, 112-122. <https://doi.org/10.4236/ojrd.2019.94010>

**Received:** September 1, 2019

**Accepted:** November 11, 2019

**Published:** November 14, 2019

Copyright © 2019 by author(s) and Scientific Research Publishing Inc.

This work is licensed under the Creative Commons Attribution International License (CC BY 4.0).

<http://creativecommons.org/licenses/by/4.0/>

Open Access

## Abstract

**Introduction:** The high resolution computed tomography (HRCT) is an important part in the diagnostic approach of interstitial lung disease (ILD) associated with connective tissue diseases (CTD) by providing detailed information on the elementary lesion and the radiological pattern of ILD. **Aim:** to point out the role of HRCT in the diagnosis of ILD associated with CTD (ILD-CTD). **Methods:** A Retrospective descriptive study was conducted between 2008 and 2017. Data of 24 patients presenting ILD-CTD were collected. A review of HRCT was performed by a radiologist without knowledge of the CTD. **Results:** Predominant elementary lesion of ILD associated with dermatomyositis (9 cases) was ground glass opacity (n = 9) followed by consolidation (n = 6). Non Specific Interstitial Pneumonia (NSIP) was the most reported pattern (5 cases). Ground glass opacity was also the predominant elementary lesion for the 2 cases of scleroderma and in Sjögren's syndrome (4 cases/5). NSIP was the predominant radiological presentation in these two CTD. Lymphoid interstitial pneumonia revealed Sjogren's syndrome in one case. In rheumatoid arthritis (6 cases), the elementary HRCT lesions were irregular interlobular septal thickening (n = 4) and honeycombing (n = 4) consistent with Usual Interstitial Pneumonia (UIP) in 2 cases. Similarly UIP has been described for the 2 patients with lupus and mixed connective tissue disease. **Conclusion:** HRCT plays an important role in the management of ILD-CTD. Description of the HRCT elementary lesions and the radiological pattern of ILD can be helpful for CTD's diagnosis.

## Keywords

Interstitial Lung Diseases, Connective Tissue Diseases, Computed

## 1. Introduction

Connective tissue diseases (CTD) represent a heterogeneous group of dysimmune inflammatory diseases that can affect a large number of organs, particularly lungs. This group refers to: polymyositis-dermatomyositis (PM/DM) with a particular entity that is the anti-synthetase syndrome (ASS), rheumatoid arthritis (RA), systemic sclerosis, Sjögren's syndrome, systemic lupus erythematosus (SLE) and mixed connective tissue [1]. Pulmonary manifestations of CTD are frequent but undiagnosed because they are mostly unknown. Interstitial involvement is one of these manifestations occurring in about 15% of all CTD [2]. Diffuse interstitial lung disease (ILD) may reveal CTD or occur during follow-up marking the course of the disease. In fact, ILD represents an important part of the CTD morbidity with worsening prognosis and high mortality [2]. Early diagnosis of these patients is essential. Radiologist plays a key role in the multidisciplinary approach of ILD associated with CTD (ILD-CTD). His major tool is the high resolution computed tomography (HRCT), which plays an important role in all steps' management. Radiological lesions are rarely specific, but can guide the diagnosis when making characteristic pattern. The CVDs can cause a variety of ILDs, identical histologically to the idiopathic interstitial pneumonias, including non-specific interstitial pneumonia (NSIP), usual interstitial pneumonia (UIP), organizing pneumonia (OP), and lymphoid interstitial pneumonia (LIP) [3]. The aim of this study is to point out the role of HRCT in ILD-CTD's diagnosis by identifying predominant elementary lesions and radiological pattern of ILD-CTD.

## 2. Patients and Methods

We performed a retrospective study conducted in the D. Pulmonology department of A. Mami Hospital (Tunisia) from January 2008 to March 2017. Patients included were aged  $\geq 18$  years and had a diagnosis of CTD established according to international classifications [4] with immunological confirmation.

Diagnosis of CTD in our study was based on rheumatoid factor and anticyclic citrullinated peptide in RA, anti-Jo-1 antibody in ASS, anti-topoisomerase (anti-Scl-70) antibodies in Scleroderma, anti-Ro (SSA), anti-La (SSB) in Sjogren's syndrome, antinuclear antibodies in SLE and U1 RNP antibodies in mixed connective tissue. The muscle enzymes, electromyography data and muscle biopsy were also useful in PM/DM diagnosis.

All patients had a HRCT describing ILD. Patients with other causes of ILD than CTD were excluded. For included patients demographic and clinical data were assessed. Symptoms including: Raynaud phenomenon, constitutional symptoms, arthralgias, dysphagia, proximal muscle weakness, myalgia, dry mouth,

dry eye were taken. We evaluate on physical examination: digital clubbing, crackles mechanic's hands, sclerodactyly, telangiectasia, digital ulcers, joint deformity, and proximal muscle weakness.

All HRCT were performed on a 16-slice helical scanner with a helical acquisition of  $16 \times 1.25$  mm. Deep inspiration blocked was mandatory for all our patients completed with acquisition after forced expiration if airway's obstruction is suspected. Images were analyzed in parenchymal window (level of  $-600$  UH and  $1600$  UH window) and mediastinal window ( $50$  UH level and  $400$  UH window), on native axial sections, supplemented if necessary by reconstructions in "Maximal Intensity Projection" (MIP), "Minimal Intensity Projection" (MinIP) and multiplanar (MPR) modes.

Contrast injection was performed in 4 patients. A retrospective review of HRCT was performed by a radiologist without knowledge of the CTD to avoid being influenced in his radiological description.

For each HRCT, we noted elementary lesions: regular or irregular septal thickening, non septal lines, reticulations, honeycombing, ground glass opacities (GGO), consolidations, micro/nodules, architectural distortion, bronchiectasis, bronchiolectasis. Predominant lesions and their distribution were carried out. Associated signs (mediastinal lymph nodal enlargement, hiatal hernia, esophageal dilatation, pulmonary artery's dilatation, emphysema) were also noted.

Cranio-caudal distribution was made by dividing each lung into 3 regions: the upper third corresponding to the area sitting above the hull, the middle third located between the planes of the hull and lower pulmonary veins and the lower third above them.

Transverse distribution interested cortical and medullar regions: cortical region was defined by the 2 to 3 cm of parenchyma located under the costal, mediastinal, scissural or diaphragmatic pleura. Deep parenchymal region represents the Medulla. ILD related to CTD were classified as: usual interstitial pneumonia (UIP), non specific interstitial pneumonia (NSIP), organized pneumonia (OP) and lymphocyte interstitial pneumonia (LIP). HRCT appearance of each entity is detailed in **Table 1** [5] [6].

Data analyses were conducted using IBM SPSS Statistics Version 11 software. Qualitative variables were described in number and frequency (%). Quantitative variables were expressed as number and extreme values.

### 3. Results

Twenty four ILD-CTD patients (23 women and 1 man) were included which represents 2.47% of all ILD patients followed during the study period. Mean age was 57.7 years (29 - 73). Diagnosed CTD were in descending order: PM-DM (9 cases) including 7 patients with ASS, RA (6 cases), Sjogren's syndrome (5 cases), scleroderma (2 cases), SLE (1 case) and mixed connective tissue disease (1 case). ILD revealed CTD in 14 cases: 7 cases/9 for PM/DM, 1 case/6 for RA, 4 cases/5 for Sjogren's syndrome and for the 2 patients with SLE and mixed connective

**Table 1.** Radiologic-pathologic pattern of ILD [5] [6].

Radiologic-Pathologic Pattern	High resolution chest tomography findings
Usual Interstitial Pneumonia (UIP)	Reticulations Honeycombing Subpleural, basal predominance Absence of features that are diagnostically inconsistent with UIP
Non specific interstitial pneumonia (NSIP)	Ground glass opacities ± intralobular reticulation, Traction bronchiectasis, Absence or minor honeycombing, Bilateral, symmetrical lesions Lower lobes predominance with sparing of the dorsal subpleural band
Organized pneumonia (OP)	Consolidation ± ground glass opacities, “halo sign”, subpleural predominance peribronchovascular distribution Migratory character
Lymphocyte interstitial pneumonia (LIP)	Centrilobular and subpleural nodules, Ground glass opacities Thickening of the septal and bronchovascular bundles Perilymphatic distribution Thin-walled Cysts

tissue. ILD was isolated prior to extra-thoracic manifestations of CTD in one patient with polymyositis.

HRCT elementary lesions of CTD-ILD, their distribution and the radiological pattern suggested are shown in **Table 2**.

Predominant elementary lesion of ILD associated with PM-DM was GGO noted in the 9 cases (**Figure 1(a)**, **Figure 1(b)**). Consolidations were also observed in 6/9 cases (**Figure 1(a)**, **Figure 1(b)**). Both predominated in the lower third of lungs. NSIP was the most frequent HRCT pattern (n = 5).

GGO and irregular septal lines predominating in the lower third sparing the subpleural band were observed in the 2 patients having a scleroderma (**Figure 1(c)**). These radiological lesions were associated with an oesophageal dilation in both cases (**Figure 1(d)**). HRCT pattern was NSIP in both cases.

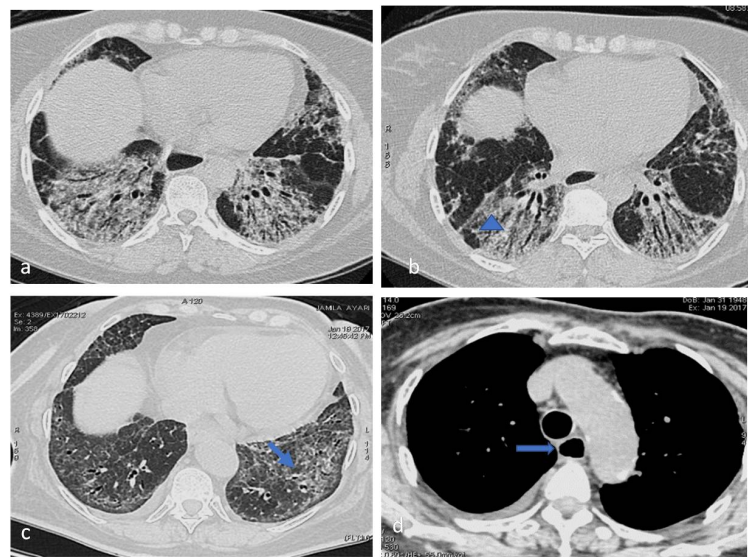
In RA (n = 6), elementary HRCT lesions were irregular septal lines and honeycombing lesions each described in 4 patients (**Figure 2**). These lesions predominated in the lower third (4 cases) and in the subpleural area (4 cases) (**Figure 2**). A definite UIP was diagnosed in 2 cases and a NSIP in 1 case (**Table 2**).

Predominant elementary lesion for patients with Sjogren’s syndrome was GGO in 4 cases. Parenchymal lesions predominated in the lower third (4/5 cases). These lesions were consistent with a NSIP in 3 cases. A LIP was reported in one case and revealed Sjogren’s syndrome (**Figure 3**).

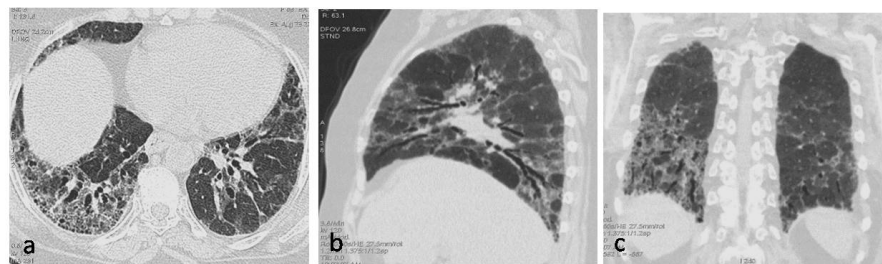
HRCT analysis of ILD associated with SLE (n = 1) and mixed connective tissue disease (n = 1) revealed irregular septal lines, honeycombing lesions and peribronchovascular distortion consistent with an UIP in both cases.

#### 4. Discussion

In our study, more than a half of CTD were revealed by an ILD. Most common



**Figure 1.** Non Specific Interstitial Pneumonia associated with antisynthetase syndrome and scleroderma. (a, b) Axial CT section in parenchymal window; parenchymal consolidations and ground glass opacities seat of a distorted air bronchogram (arrow head). Radiological pattern suggested: NSIP. Connectivity diagnosed: Antisynthetase Syndrome; (c) Ground glass opacities (arrow) and irregular septal thickening of the medulla lung region sparing subpleural band associated with a bronchial distortion. Radiological pattern suggested: NSIP. Connectivity diagnosed: Scleroderma; (d) Axial CT section in the mediastinal window: Esophageal dilation (arrow). Connectivity diagnosed: Scleroderma.



**Figure 2.** Usual Interstitial Pneumonia or type III Non Specific Interstitial Pneumonia associated with rheumatoid arthritis. Axial (a), coronal (b) and sagittal (c) CT section in parenchymal window; honeycombing, bronchovascular distortion, irregular septal thickening and ground glass opacities in fibrosis areas (a) with apico basal gradient (b, c). Radiological pattern suggested: UIP or type III NSIP. Connectivity diagnosed: rheumatoid arthritis.

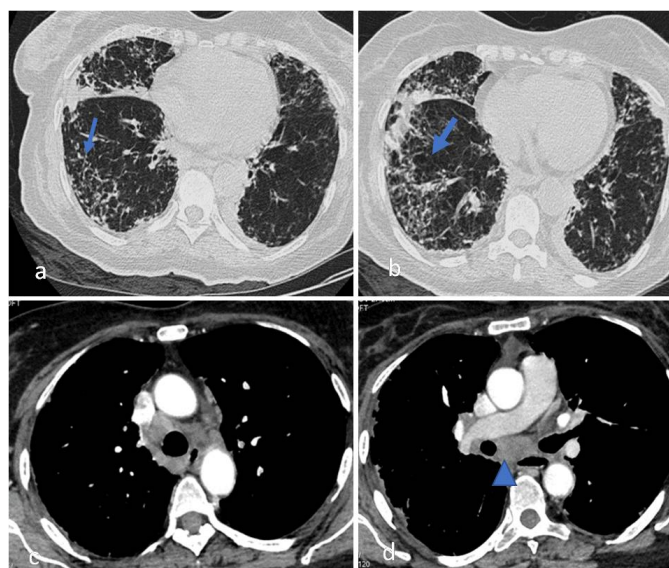
**Table 2.** HRCT Elementary lesions and pattern of ILD-CTD.

	PM-DM* (9 cases)	RA** (6 cases)	Sjogren's syndrome (5 cases)	Scleroderma (2 cases)	SLE*** (1 case)	Mixed connective tissue disease (1 case)
<b>Elementary lesions</b>						
Ground glass opacities	9	3	4	2	-	-
Regular septal thickening	-	-	2	-	-	-
Irregular septal thickening	6	4	3	2	1	1
Non septal lines	-	1	-	-	-	-
Reticulations	1	-	-	-	-	-

## Continued

Honeycombing	1	4	1	-	1	1
Consolidations	6	-	-	-	-	-
Micro/nodules	-	-	3	-	-	-
Architectural distortion	8	3	2	1	1	1
Bronchiectasis	2	2	3	1	1	-
Bronchiolectasis	2	1	1	1	-	-
<b>Associated lesions</b>						
Mediastinal lymph nodal enlargement	-	-	1	-	-	-
Esophageal dilatation	-	-	-	2	-	-
Hiatal hernia	-	1	-	1	-	-
Pulmonary artery dilatation	1	2	-	-	-	-
<b>Basal predominance</b>	9	4	4	2	-	1
<b>Subpleural predominance</b>	3	4	2	2	1	1
<b>Medullary lung region predominance</b>	1	-	-	-	-	-
<b>No transverse gradient</b>	5	2	3	-	-	-
<b>HRCT pattern of ILD-CTD</b>						
NSIP	5	1	3	2	-	-
Likely NSIP	2	1	-	-	-	-
Typical UIP	1	2	-	-	1	1
Possible UIP	-	1	-	-	-	-
UIP of type III NSIP	1	1	-	-	-	-
LIP	-	-	1	-	-	-

Abbreviations: HRCT: High Resolution Chest Tomography, ILD-CTD: interstitial lung disease associated with connective tissue diseases, \*PM-DM: Polymyositis-Dermatomyositis, \*\*RA: Rheumatoid arthritis, \*\*\*SLE: Systemic Lupus Erythematosus, NSIP: Non specific interstitial pneumonia, UIP: Usual Interstitial Pneumonia, LIP: Lymphocyte interstitial pneumonia, -: Absent Sign.



**Figure 3.** Lymphocyte interstitial pneumonia associated with Sjogren's syndrome. Axial CT sections in parenchymal (a, b) and mediastinal windows (c, d). Septal thickening and micronodules of lymphatic distribution (arrow) associated with mediastinal lymph nodes (arrow head). Radiological pattern suggested: LIP. Connectivity diagnosed: Sjogren's syndrome.



elementary lesions were GGO. NSIP was the most frequent HRCT pattern described in 11 cases. The most observed CTD was PM-DM diagnosed in 9 patients. It was revealed by ILD in 7 cases. HRCT predominant lesion was GGO described for all PM-DM patients followed by irregular septal thickening and consolidations observed in 6 cases/9. Common HRCT elementary lesion of PM-DM included: reticulations (30% - 92%), GGO (30% - 92%), consolidations (30% - 55%) and honeycombing (0% - 16%) [7] [8]. In a study of 57 patients with ILD associated with PM-DM, reticular opacities were observed in 95% and consolidations in 25% [9]. Ikezoe *et al.* [10] evaluated HRCT data of 25 patients who had PM-DM. Twenty three patients had abnormal HRCT findings. The Most common described are GGO (92%), reticular opacities (92%), irregular interfaces (88%), airspace consolidation (52%), parenchymal micronodules (28%) and honeycombing (16%). Same findings were observed in our study with GGO as the predominant elementary lesion noted in the 9 patients followed by irregular septal thickening and consolidations observed in 6 cases/9. As in our study, NSIP is the most described HRCT pattern in PM-DM [11] [12] followed by OP, UIP and diffuse alveolar damage. LIP is rare in this context [11]. On lung biopsy, PM-DM patients may have more than one histological pattern. The most common combination is NSIP and OP [12].

GGO and reticulations are the most HRCT elementary lesions reported in RA associated with ILD [13]. However, in our study, the predominant elementary lesions were irregular septal thickening and honeycombing cysts each noted in 4 patients.

UIP and less frequently NSIP or OP are commonly described in RA [14]. In our study a typical UIP was described in 2/6 cases, NSIP in 1/6 cases and indeterminate pattern in 3 cases. Kim *et al.* [15] reviewed HRCT findings in 82 patients with RA associated with ILD. HRCT were interpreted as typical UIP in 20 patients (24%), likely NSIP in 19 (23%), and indeterminate in 43 patients (52%). Of the 19 cases with a likely NSIP radiological pattern, 6 underwent surgical lung biopsy, which showed UIP in 4 and NSIP in 2 patients. Six out of 43 patients with an indeterminate pattern on HRCT underwent surgical lung biopsy, which showed UIP in 5 patients and NSIP in 1 patient [15].

HRCT elementary lesions of ILD associated with Sjogren's syndrome included: GGO, fibrosis signs, centrolobular micronodules and cysts [16]. In our series, the predominant elementary lesion was GGO noted in 4/5 cases. Uffmann *et al.* [17] performed a HRCT in 37 patients with primary Sjogren's syndrome and normal chest X-ray. Abnormal HRCT findings were observed in 24 of the 37 patients (65%) and consisted mainly of septal thickening (n = 9), micronodules (n = 9), pulmonary cysts (n = 5), and GGO (n = 4). Lohrmann *et al.* [18] reviewed HRCT of 24 Sjogren's syndrome patients. Nineteen patients (79%) had abnormal data including bronchiectasis, thin-walled cysts and micronodules (46%), GGO and emphysema (38%), interlobular septal thickening (29%), honeycombing (25%), tree-in-bud pattern (21%) and mosaic perfusion (17%). NSIP was the most frequently HRCT pattern [19] [20] which was similar to our

study. In fact, NSIP was observed in 3 of the 5 Sjogren's syndrome patients. UIP, OP and LIP lesions were also reported [20]. A LIP revealing the Sjogren's syndrome was noted in 1 case in our study.

HRCT findings of ILD associated with scleroderma consist mainly of GGO frequently with superimposed fine reticulations and traction bronchiectasis [21]. In our study, GGO and irregular septal lines predominating in the lower third were observed in the 2 patients with scleroderma. They were associated with oesophageal dilatation. In fact, asymptomatic oesophageal dilatation may be present in 40% to 80% of scleroderma patients with ILD [22] [23]. Other associated HRCT lesions have been described such as mediastinal adenomegaly reported in about 60% of cases [23]. Approximately 80% of patients with ILD associated with scleroderma have a histological type of NSIP [24] [25], but it is not exclusive (UIP, OP) [26]. This was similar to our findings with a NSIP described for the 2 scleroderma cases.

Since ILD in SLE is rare, there is limited data on the radiologic-pathologic pattern. However, as with other CTD, NSIP is the most described followed by UIP [19]. In our study, elementary lesions and their distribution were suggestive of UIP.

The most radiological findings in ILD associated with mixed connective tissue disease were reticulations, GGO, honeycombing and bronchiectasis [27] [28]. NSIP is the most described histological type. However, other less common radiologic-pathologic patterns have been reported like UIP, LIP and OP [29]. In our study, predominant elementary lesions were irregular septal lines, honeycombing and bronchovascular distortion. These HRCT findings suggested UIP.

CT scan can guide the diagnosis by individualizing characteristic aspects even without clinical manifestations. In our study, radiologic patterns suggestive of LIP revealed a Sjogren's syndrome, as well as consolidations led us to look for PM-DM signs.

Our study has several limitations. It was a retrospective study explaining the lack of some data, such as respiratory function tests and bronchoalveolar lavage. Radiological follow-up data are also lacking because an internal medicine department did not exist in our hospital. The study has a small population because it was monocentric. The predominance of women observed in our study is explained in part by the characteristics of our department with exclusive hospitalization of women until 2009.

ILD represents an important part of CTD's morbidity with a worsening of the prognosis. Their early detection by HRCT is essential for a better patient management.

This study confirms the importance of HRCT in the diagnostic approach of CTD. Thus, multidisciplinary collaboration between radiologist and pulmonologist is mandatory.

## 5. Conclusions

This study emphasizes the important role of HRCT in the diagnosis of ILD-CTD.



Description of pattern and distribution of radiographic abnormalities can predict pathologic findings.

NSIP is the most common pattern in all CTD, except for RA with a higher frequency of UIP. Some ILD radiologic features can contribute to the CTD diagnosis even without clinical manifestations. This was the case of the LIP description revealing Sjogren's syndrome and consolidations suggesting PM/DM.

### Conflicts of Interest

None of the authors have any conflicts of interest to disclose.

### References

- [1] Clerc, S. and Cadranel, J. (2015) Les connectivites. *Revue des Maladies Respiratoires Actualités*, **7**, 118-121. [https://doi.org/10.1016/S1877-1203\(15\)30033-1](https://doi.org/10.1016/S1877-1203(15)30033-1)
- [2] Nunes, H., Schubel, K., Piver, D., *et al.* (2015) Nonspecific Interstitial Pneumonia: Survival Is Influenced by the Underlying Cause. *European Respiratory Journal*, **45**, 746-755. <https://doi.org/10.1183/09031936.00148613>
- [3] Hwang, J.H., Misumi, S., Sahin, H., Brown, K.K., Newell, J.D. and Lynch, D.A. (2009) Computed Tomographic Features of Idiopathic Fibrosing Interstitial Pneumonia: Comparison with Pulmonary Fibrosis Related to Collagen Vascular Disease. *Journal of Computer Assisted Tomography*, **33**, 410-415. <https://doi.org/10.1097/RCT.0b013e318181d551>
- [4] Vij, R. and Strek, M.E. (2013) Diagnosis and Treatment of Connective Tissue Disease-Associated Interstitial Lung Disease. *Chest*, **143**, 814-824. <https://doi.org/10.1378/chest.12-0741>
- [5] Neji, H., Attia, M., Affes, M., Baccouche, I., Ben Miled-M'rad, K. and Hantous-Zannad, S. (2018) Interstitial Lung Diseases: Imaging Contribution to Diagnosis and Elementary Radiological Lesions. *Seminars in Diagnostic Pathology*, **35**, 297-303. <https://doi.org/10.1053/j.semmdp.2018.07.001>
- [6] Debray, M.-P., Borie, R., Danel, C., Khalil, A., Majlath, M. and Crestani, B. (2017) Actualités dans les pneumopathies interstitielles idiopathiques en 2016. *Revue de Pneumologie Clinique*, **73**, 13-26. <https://doi.org/10.1016/j.pneumo.2016.09.001>
- [7] Cottin, V., Thivolet-Béjui, F., Reynaud-Gaubert, M., *et al.* (2003) Interstitial Lung Disease in Amyopathic Dermatomyositis, Dermatomyositis and Polymyositis. *European Respiratory Journal*, **22**, 245-250. <https://doi.org/10.1183/09031936.03.00026703>
- [8] Bonnefoy, O., Ferretti, G., Calaque, O., *et al.* (2004) Serial Chest CT Findings in Interstitial Lung Disease Associated with Polymyositis-Dermatomyositis. *European Journal of Radiology*, **49**, 235-244. [https://doi.org/10.1016/S0720-048X\(03\)00094-9](https://doi.org/10.1016/S0720-048X(03)00094-9)
- [9] Douglas, W.W., Tazelaar, H.D., Hartman, T.E., *et al.* (2001) Polymyositis-Dermatomyositis-Associated Interstitial Lung Disease. *American Journal of Respiratory and Critical Care Medicine*, **164**, 1182-1185. <https://doi.org/10.1164/ajrccm.164.7.2103110>
- [10] Ikezoe, J., Johkoh, T., Kohno, N., Takeuchi, N., Ichikado, K. and Nakamura, H. (1996) High-Resolution CT Findings of Lung Disease in Patients with Polymyositis and Dermatomyositis. *Journal of Thoracic Imaging*, **11**, 250-259. <https://doi.org/10.1097/00005382-199623000-00002>
- [11] Connors, G.R., Christopher-Stine, L., Oddis, C.V. and Danoff, S.K. (2010) Intersti-

tial Lung Disease Associated with the Idiopathic Inflammatory Myopathies: What Progress Has Been Made in the Past 35 Years? *Chest*, **138**, 1464-1474.

<https://doi.org/10.1378/chest.10-0180>

- [12] Tansey, D., Wells, A.U., Colby, T.V., et al. (2004) Variations in Histological Patterns of Interstitial Pneumonia between Connective Tissue Disorders and Their Relationship to Prognosis. *Histopathology*, **44**, 585-596.  
<https://doi.org/10.1111/j.1365-2559.2004.01896.x>
- [13] Crestani, B. (2006) Atteintes pulmonaires infiltrantes révélatrices des connectivites. *Revue des Maladies Respiratoires*, **23**, 42-50.  
[https://doi.org/10.1016/S0761-8425\(06\)71548-0](https://doi.org/10.1016/S0761-8425(06)71548-0)
- [14] Balbir-Gurman, A., Guralnik, L., Yigla, M., Braun-Moscovici, Y. and Hardak, E. (2018) Imaging Aspects of Interstitial Lung Disease in Patients with Rheumatoid Arthritis: Literature Review. *Autoimmunity Reviews*, **17**, 87-93.  
<https://doi.org/10.1016/j.autrev.2017.09.013>
- [15] Kim, E.J., Elicker, B.M., Maldonado, F., et al. (2010) Usual Interstitial Pneumonia in Rheumatoid Arthritis-Associated Interstitial Lung Disease. *European Respiratory Journal*, **35**, 1322-1328. <https://doi.org/10.1183/09031936.00092309>
- [16] Egashira, R., Kondo, T., Hirai, T., et al. (2013) CT Findings of Thoracic Manifestations of Primary Sjögren Syndrome: Radiologic-Pathologic Correlation. *RadioGraphics*, **33**, 1933-1949. <https://doi.org/10.1148/rg.337125107>
- [17] Uffmann, M., Kiener, H.P., Bankier, A.A., Baldt, M.M., Zontsich, T. and Herold, C.J. (2001) Lung Manifestation in Asymptomatic Patients with Primary Sjögren Syndrome: Assessment with High Resolution CT and Pulmonary Function Tests. *Journal of Thoracic Imaging*, **16**, 282-289.  
<https://doi.org/10.1097/00005382-200110000-00009>
- [18] Lohrmann, C., Uhl, M., Warnatz, K., et al. (2004) High-Resolution CT Imaging of the Lung for Patients with Primary Sjögren's Syndrome. *European Journal of Radiology*, **52**, 137-143. <https://doi.org/10.1016/j.ejrad.2004.01.006>
- [19] deLauretis, A., Veeraraghavan, S. and Renzoni, E. (2011) Review Series: Aspects of Interstitial Lung Disease: Connective Tissue Disease-Associated Interstitial Lung Disease: How Does It Differ from IPF? How Should the Clinical Approach Differ? *Chronic Respiratory Disease*, **8**, 53-82. <https://doi.org/10.1177/1479972310393758>
- [20] Parambil, J.G., Myers, J.L., Lindell, R.M., Matteson, E.L. and Ryu, J.H. (2006) Interstitial Lung Disease in Primary Sjögren Syndrome. *Chest*, **130**, 1489-1495.  
<https://doi.org/10.1378/chest.130.5.1489>
- [21] Tanaka, N., Newell, J.D., Brown, K.K., Cool, C. and Lynch, D. (2004) Collagen Vasculardisease-Related Lung Disease: High-Resolution Computed Tomography-findings Based on the Pathologic Classification. *Journal of Computer Assisted Tomography*, **28**, 351-360. <https://doi.org/10.1097/00004728-200405000-00009>
- [22] Grenier, P., Chevret, S., Beigelman, C., Brauner, M.W., Chastang, C. and Valeyre, D. (1994) Chronic Diffuse Infiltrative Lung Disease: Determination of the Diagnostic Value of Clinical Data, Chest Radiography, and CT and Bayesian Analysis. *Radiology*, **191**, 383-390. <https://doi.org/10.1148/radiology.191.2.8153310>
- [23] Bhalla, M., Silver, R.M., Shepard, J.A. and McLoud, T.C. (1993) Chest CT in Patients with Scleroderma: Prevalence of Asymptomatic Esophageal Dilatation and Mediastinal Lymphadenopathy. *American Journal of Roentgenology*, **161**, 269-272.  
<https://doi.org/10.2214/ajr.161.2.8333359>
- [24] Bouros, D., Wells, A.U., Nicholson, A.G., et al. (2002) Histopathologic Subsets of Fibrosing Alveolitis in Patients with Systemic Sclerosis and Their Relationship to

- Outcome. *American Journal of Respiratory and Critical Care Medicine*, **165**, 1581-1586. <https://doi.org/10.1164/rccm.2106012>
- [25] Desai, S.R., Veeraghavan, S., Hansell, D.M., *et al.* (2004) CT Features of Lung Disease in Patients with Systemic Sclerosis: Comparison with Idiopathic Pulmonary Fibrosis and Nonspecific Interstitial Pneumonia. *Radiology*, **232**, 560-567. <https://doi.org/10.1148/radiol.2322031223>
- [26] Duxbury, B. and Roachat, T. (2015) Pneumopathies interstitielles liées aux connectivites. *Revue Médicale Suisse*, **11**, 2170-2175.
- [27] Colin, G., Nunes, H., Hatron, P.Y., Cadranet, J., Tillie, I. and Wallaert, B. (2010) Étude des pneumopathies interstitielles diffuses de la connectivite mixte. *Revue des Maladies Respiratoires*, **27**, 238-246. <https://doi.org/10.1016/j.rmr.2010.01.005>
- [28] Kozuka, T., Johkoh, T., Honda, O., *et al.* (2001) Pulmonary Involvement in Mixed Connective Tissue Disease: High-Resolution CT Findings in 41 Patients. *Journal of Thoracic Imaging*, **16**, 94-98. <https://doi.org/10.1097/00005382-200104000-00005>
- [29] Capobianco, J., Grimberg, A., Thompson, B.M., Antunes, V.B., Jasinowodolinski, D. and Meirelles, G.S. (2012) Thoracic Manifestations of Collagen Vascular Diseases. *RadioGraphics*, **32**, 33-50. <https://doi.org/10.1148/rg.321105058>

### Abbreviations List

- HRCT: High Resolution Computed Tomography
- ILD: Interstitial Lung Disease
- CTD: Connective Tissue Diseases
- ILD-CTD: ILD Associated with CTD
- NSIP: Non Specific Interstitial Pneumonia
- UIP: Usual Interstitial Pneumonia
- PM/DM: Polymyositis-Dermatomyositis
- ASS: Anti-Synthetase Syndrome
- RA: Rheumatoid Arthritis
- SLE: Systemic Lupus Erythematosus
- OP: Organizing Pneumonia
- LIP: Lymphoid Interstitial Pneumonia
- MIP: Maximal Intensity Projection
- MinIP: Minimal Intensity Projection
- MPR: Multiplanar Modes
- GGO: Ground Glass Opacities