

Childhood Glaucoma: An Overview

Parul Singh, Yogesh Kumar, Manoj Tyagi, Krishna Kuldeep, Parmeshwari Das Sharma

Department of Ophthalmology, Veer Chandra Singh Garhwali Government Medical Sciences and Research Institute, Srinagar, India.
Email: parulophtha@gmail.com

Received March 16th, 2012; revised April 27th, 2012; accepted May 28th, 2012

ABSTRACT

Several types of childhood glaucoma exist, and the terminology is based on the time of onset of disease and its potential cause. Though childhood glaucoma occurs less commonly than adults but can lead to permanent visual damage due to amblyopia, optic neuropathy or refractive error. A detailed evaluation should be done to establish diagnosis. Medical therapy has a limited role and surgery remains main modality for treatment. Childhood glaucoma is a treatable disease, if early diagnosis is established and therapeutic intervention done in time. In children with low vision efforts should be there to maintain residual vision and visual rehabilitation with low vision aids should be done.

Keywords: Childhood Glaucoma; Goniotomy; Trabeculotomy

1. Introduction

Glaucoma is less common in children than in adults. Although glaucoma can lead to permanent visual damage at any age, the consequences of the disease are more often severe in children due to additional damage that can happen to the developing visual system. Associated amblyopia and secondary refractive errors are common. Primary congenital glaucoma (PCG) is hereditary childhood glaucoma secondary to abnormal development of the filtration angle. Nonetheless, most ophthalmologists usually encounter the wide range of secondary forms of glaucoma in this age group. Glaucoma surgery has drastically improved the visual prognosis of children afflicted with glaucoma. However, late diagnosis of the condition can result in permanent and severe visual morbidity. Its affliction of young children makes glaucoma control a life-long goal requiring motivation and perseverance by patients, their parents and doctors. This article is intended to provide an overview of the disease at genetic levels, newer technological tools assisting in diagnosis, IOP lowering medications and refined surgical techniques.

1.1. Definition and Terminology

Relating to age of onset

- 1) Congenital glaucoma: The glaucoma that exists at birth, and usually before birth;
- 2) Infantile glaucoma: Glaucoma that occurs from birth until 3 years of age;
- 3) Juvenile glaucoma: Occurs after the age of three to teenage years.

Relating to development pattern

- 1) Developmental glaucoma: This term broadly encompasses all glaucomas resulting from abnormal development of the aqueous outflow system. This may or may not be associated with systemic anomaly;
- 2) Primary developmental glaucoma: This is the glaucoma resulting from maldevelopment of aqueous outflow system;
- 3) Secondary developmental glaucoma: This refers to glaucoma resulting from damage to aqueous outflow system due to maldevelopment of some other portion of the eye, e.g. eye with microspherophakia or dislocated lens.

Relating to anatomy

Hoskins classified developmental glaucoma anatomically by the structures involved:

- 1) Trabecular meshwork: Trabeculodysgenesis;
- 2) Iris and trabecular meshwork: Iridotrabeculodysgenesis;
- 3) Cornea and trabecular meshwork: Corneotrabeculodysgenesis [1].

1.2. Classification of Congenital and Infantile Glaucoma

Primary congenital glaucoma (Trabeculodysgenesis)

Secondary congenital glaucoma

- 1) Iridocorneotrabeculodysgenesis
 - a) Rieger's anomaly;
 - b) Axenfeld anomaly;
 - c) Peter's anomaly.
- 2) Iridotrabeculodysgenesis

- a) Stromal defects: Hypoplasia, hyperplasia;
- b) Anomalous iris vessels: Persistence of tunica vasculosa lenti;
- c) Structural anomalies: Holes, coloboma, aniridia;

Acquired glaucomas

- 1) Aphakia;
- 2) Corticosteroid induced;
- 3) Retinoblastoma;
- 4) Traumatic;
- 5) Uveitis.

2. Epidemiology

Primary congenital glaucoma is hereditary with a variable incidence in different populations, but an overall occurrence of 1 in 10,000 births is seen [2]. A greater incidence occurs in populations with higher rates of consanguinity [3,4]. Boys are more commonly affected in United States and Europe with boys to girls ratio of 3:2. Whereas, in Japan more girls are seen having this condition [5,6]. The majority (about 75%) of PCG cases are bilateral and asymmetric expression should be suspected in clinically apparent unilateral cases. More than 80% patients present within the first year of life, with 25% diagnosed in the neonatal period and 60% within the first 6 months of life [7].

3. Genetics

The majority of PCG cases are sporadic but 10% - 40% are familial with frequent association with consanguinity [8]. In the most familial cases, transmission is autosomal recessive with variable expression and penetrance of 40% - 100% [8].

Genetic heterogeneity of PCG confirmed by linkage studies explain discrepancies like unequal sex distribution, lower than expected number of affected siblings in familial cases, and transmission of the disease to successive generations [8]. Three loci for PCG have been found [8-10]. The initial locus on chromosome 2p21 (GLC3A) was described in 1995 by Sarfarazi *et al.* who identified significant genetic linkage to this region in 11 of 17 Turkish families [8,11]. Genetic heterogeneity was confirmed when a second locus on chromosome 1p36 (GLC3B) was found [9]. Genetic family analysis identified a third locus GLC3C on chromosome 14q24.3 [10]. Although three chromosomal loci have been linked to PCG, only CYP1B1 in locus GLC3A has been identified [12]. Mutations in these genes have been described as the predominant cause of PCG in Turkish and Saudi Arabian families [13]. It has been reported that 87% of familial and 27% sporadic case are due to mutation in this gene [8]. Approximately 45 mutations of this gene have been identified and include deletion, insertion, point mutation, mis-sense, non-sense, frameshift and terminator mutation

[14]. From all mutations studied, frameshift and R390C homozygous mutations were associated with severe phenotype and very poor prognosis. Primary juvenile glaucoma can be inherited in an autosomal dominant fashion. A mutation in the chromosome 1q23-25 region has been linked to this disease [15,16]. Genetic studies have also been conducted on few other glaucomas. In Axenfeld, Rieger anomaly, the gene has been mapped to chromosome 6p25 [17]. In aniridia, the most common inheritance pattern is autosomal dominant. The genetic locus for aniridia has been established as the PAX6 gene, located on 11p13 [18].

4. Pathogenesis

The exact mechanism involved in pathophysiology of primary infantile glaucoma is not known. One theory said that a pathologic membrane (known as Barkan's membrane) [19] covered and blocked the trabecular meshwork in primary infantile glaucoma. Clinical and histopathologic observations of the anterior chamber in infantile glaucoma have revealed that the anatomic relationship between the iris, trabecular meshwork and ciliary body are immature. The principal defect in primary infantile glaucoma is a failure of one or more steps in the normal development of the anterior chamber angle.

As the genes associated with primary infantile glaucoma are characterized further and the physiological or developmental role of the proteins they encode become better understood; the molecular, cellular and embryological pathophysiology of this rare disorder will become clear [12].

Among the secondary glaucomas of childhood, the underlying pathophysiology is as varied as that in adults. Occurrence at or shortly after birth indicates a profound developmental abnormality of anterior chamber angle whereas, manifestation later usually suggests a different process.

Secondary open angle also occur in young children. Both corticosteroid-induced and chronic uveitic glaucomas are described [20]. It is difficult to classify the underlying cause of glaucoma, that frequently follows pediatric cataract extraction. Walton examined 65 children in whom, pre-operative gonioscopy revealed no consistent angle defect but post-operative gonioscopy revealed filtration angle deformity [21]. Retained lens material was one of the risk factor known another cause may be presence of small cornea.

5. Presentation

The signs and symptoms of PCG are variable dependent on child's age and severity of glaucoma; and secondary corneal abnormalities. PCG is characterized by clinical triad of epiphora, blepharospasm and photophobia, but

these symptoms are often missed until the more alarming corneal edema becomes apparent. The corneal edema, may be subtle, especially in bilateral cases; or profound with enlarged corneal diameter and globe, breaks in Descemet's membrane (Haab's striae) and sometimes even acute hydrops.

Myopia is typical finding in infantile glaucoma. In older children, astigmatism and progressive axial myopia cause symptomatic decreased uncorrected visual acuity and refractive amblyopia.

Optic neuropathy is the most concerning consequence from glaucoma, because the neuropathy is irreversible once axonal death has occurred.

While cupping of the optic nerve in glaucoma is generally a gradual process in older children and adults, it can occur rapidly in infants. Reversibility of the cupping with normalization of the intra-ocular pressure (IOP) in young children occurs due to suspected relative immaturity and elasticity of lamina cribrosa. Less common presenting signs in infantile glaucoma include conjunctivitis, blepharitis and cellulitis.

6. Diagnosis and Ancillary Testing

It is important to do a complete ophthalmic examination in a child suspected of glaucoma. This includes IOP measurement, gonioscopy, optic nerve head examination and refraction. Check for the child's ability to fix and follow; and for the presence of nystagmus. Examination of the cornea is crucial with respect to size and clarity of the cornea and the presence of Haab's striae.

This examination can be done in clinic. With some practice, IOP can be measured in a conscious, swaddled infant using perkin's tonometer or tonopen. Usually IOP in infants with normal eyes is in the range of 11 - 14 mm Hg using these devices. The measurement of IOP greater than 20 mmHg in a calm, resting infant is suspicious for glaucoma when other signs and symptoms also suggest the disease. Measurements of IOP undertaken while a child cries and resists efforts to hold the eye open are invalid.

Examination of the optic nerve is attempted, because obvious cupping confirms the diagnosis. Shaffer and Hetherington noted a cup to disc ratio (C/D ratio) greater than 0.3 in 68% of 126 eyes affected by primary infantile glaucoma [22], whereas C/D ratio greater than 0.3 was found in less than 2.6% of newborns with normal eyes [23]. A Koepe infant diagnostic lens offers good visualization of disc using direct ophthalmoscope. Gonioscopy can also be performed with it even in a conscious infant. In the normal newborn eye, the iris usually inserts posterior to the scleral spur. In PCG, the iris commonly inserts anteriorly directly into the trabecular meshwork. This iris insertion is most commonly flat, although concave insertion may be rarely seen.

If the diagnosis of glaucoma is confirmed or strongly suspected based on clinical examination, an examination under anaesthesia is required. Unfortunately, most anesthetic agents and sedatives have lowering effect on IOP [24]. Tonometry should be best performed as soon as possible after induction of anesthesia. Corneal diameters are measured with a millimeter ruler or caliper and recorded. Detailed hand slit lamp examination of anterior segment is followed by gonioscopy and fundus examination.

Visual field defects are similar to those seen in adults with initial predilection for loss in arcuate areas, but child should be able to follow directions for field examination (perimetry). Although the technology has been around and algorithm is getting better and better, it is still difficult to apply them in children as they may not follow instructions or may not cooperate. Optical coherence tomography may be a better option and much easier as compared to visual field examination in young and non-cooperative patients.

7. Differential Diagnosis

Signs and symptoms	Condition
Tearing, discharge, conjunctival injection	Nasolacrimal duct obstruction infections Allergic conjunctivitis
Cloudy cornea, loss of corneal lusture, Haab's striae	Corneal dystrophy e.g. CHED, PPMF Forcep trauma Cysticercosis Sclerocornea Mucopolysaccharidosis I, Is, II, III infectious keratitis
Enlarged cornea, apparent asymmetry of globe size	Primary megalocornea Unilateral high myopia Proptosis lid retraction Contralateral microphthalmos Enophthalmos ptosis
Photophobia, blepharospasm	Uveitis corneal infection, abrasion or dystrophy Retinal cone dystrophy
High myopia	Pathologic myopia Vitreoretinal degeneration e.g. Stickler's syndrome
Enlarged cup to disc ratio	Physiologic optic nerve cupping optic nerve atrophy or anomaly

8. Management

The definitive treatment for primary infantile glaucoma is surgical. Medical therapy usually provides a supportive role to reduce the IOP temporarily, to clear the cornea, and to facilitate surgical intervention. Laser therapy has limited role in developmental glaucomas. Primary surgical treatment is usually with goniotomy or trabeculotomy, although combined trabeculotomy with trabeculectomy may be useful in certain populations with high risk of failure of goniotomy or trabeculotomy. Refractory congenital glaucomas may be managed by trabeculectomy with anti-fibrosis drugs, glaucoma drainage implants and cyclodestructive procedures (Figure 1).

8.1. Medical Management

Medications do play a limited role in the treatment of childhood glaucoma. In primary infantile glaucoma, medications may be used preoperatively to clear the corneal edema or post-operatively if the response to surgery is borderline and more time is needed to determine if further surgery is required.

8.1.1. Beta Blockers

They lower IOP by decreasing production of aqueous in the ciliary body. The drug should be used with extreme caution in neonates due to the possibility of bronchospasm, apnea and bradycardia. Cardiac abnormalities and bronchial asthma should be specifically excluded before its use. Use of 0.25%, rather than 0.5% is recommended in children, in order to reduce its side-effects. In 100 eyes with childhood glaucoma treated with timolol, 31% patients experienced a reduction in IOP [25].

8.1.2. Alpha-2 Agonists

They also decrease aqueous production but their use in children is limited because of central nervous system depression. In 30 patients with mean age of 10 years, brimodine treatment was associated with a mean reduction of IOP by 7% [26]. Two young children were transiently unarousable and five other children experienced extreme fatigue [26]. In another study involving 23 patients with mean age of 8 years, 18% had systemic adverse effects that necessitated stopping of the drug [27].

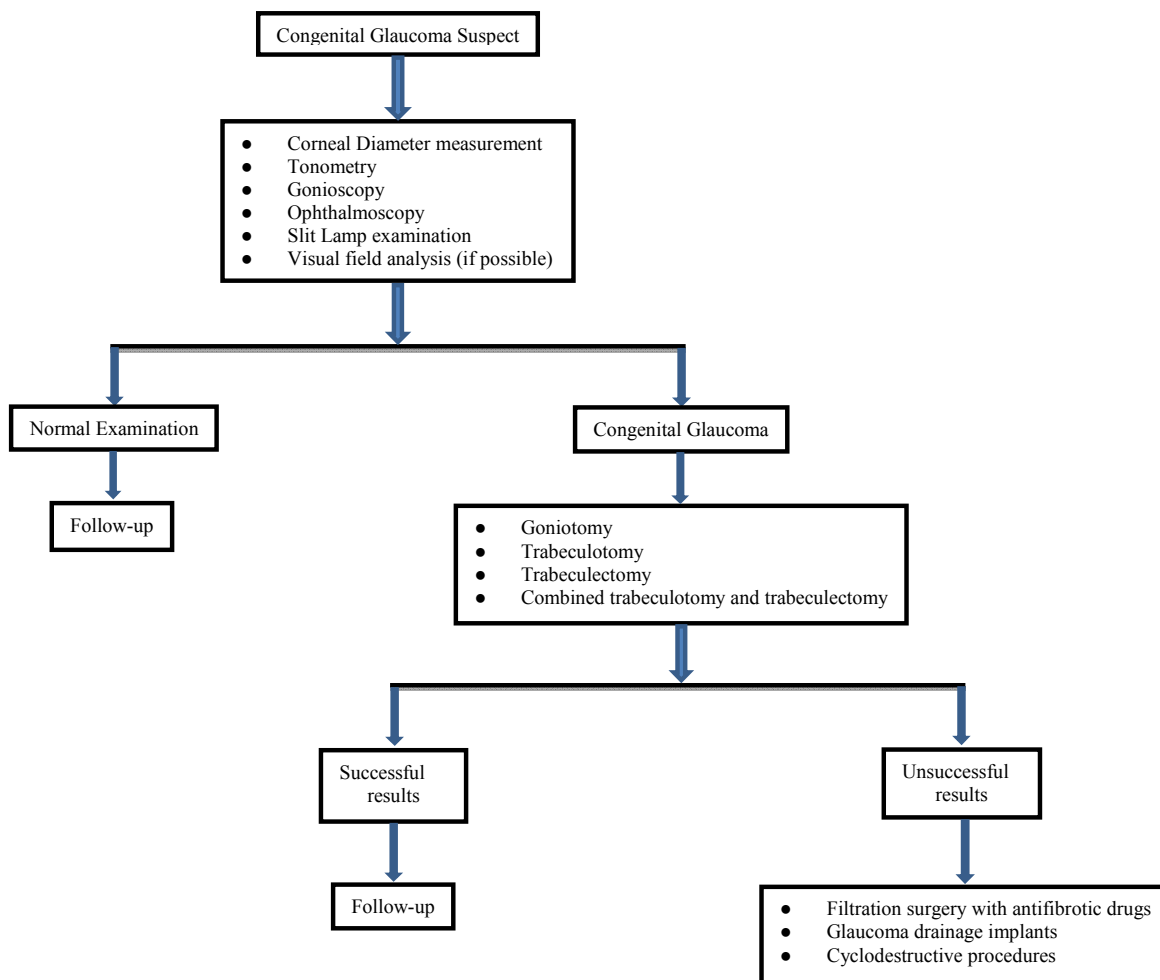


Figure 1. Flowchart of management of congenital glaucoma.

8.1.3. Carbonic Anhydrase Inhibitors (CAIs)

They suppress aqueous production and are available as either an oral formulation or as topical drop. The oral formulation may be more effective in IOP lowering but also produces more side-effects of diarrhea, lethargy, poor appetite and metabolic acidosis [28]. The mean was reduced by 36% and 27% compared with baseline, after treatment with acetazolamide and topical dorzolamide, respectively. All eyes showed an increase in IOP when switched from acetazolamide to dorzolamide with mean increase of 3.7mmHg [29]. Topical CAI can be expected to have additive benefit when used in conjunction with beta-blockers [30].

8.1.4. Prostaglandins Analogues

These drugs reduce IOP by enhancing uveo-scleral outflow [31]. Their side-effects include conjunctival hyperemia, iris and skin pigmentation and accelerated eyelash growth. High non-response rate has been reported in children with little IOP lowering in responders [32].

8.1.5. Miotics

They are ineffective for PCG, but can be used preoperatively before angle surgery.

8.2. Surgical Treatment

Early surgical intervention is of prime importance in the management of patients with PCG. Either goniotomy or trabeculotomy is the procedure of choice; goniotomy requires clear cornea while trabeculotomy may be performed if cornea is hazy or opaque. When greater chances of failure are present, trabeculotomy may be combined with trabeculectomy.

8.2.1. Goniotomy

A blade is inserted through the peripheral cornea 180° across from meshwork to be incised (usually the nasal or the temporal portions) and is then guided across the anterior chamber into the chamber angle. With the aid of gonioscopy lens, the trabecular meshwork is visualized, and the blade is used to make a linear incision through the meshwork for approximately one third of the circumference of eye. The reported rate of success of goniotomy in infantile glaucoma is 80% [33]. Endoscopic goniotomy has been successfully performed utilizing a co-axial ocular endoscope in presence of corneal opacification, which prevented standard goniotomy procedure [34].

8.2.2. Trabeculotomy

A scleral flap is created over the area of network to be incised. Through this flap a dissection into schlemm's canal is created. A trabeculotome is inserted into the canal and the meshwork is then opened, as instrument is rotated into the anterior chamber. Considering congenital

glaucoma of all grades of severity, trabeculotomy controls IOP in over 90% of eyes. The efficacy of this operation compared favorably with goniotomy. The results of trabeculotomy and goniotomy for infantile glaucoma were compared and found equally effective and safe [35]. The significant advantage of trabeculotomy for those cases with a cloudy cornea limiting visualization of the angle was described [36]. A newer trabeculotomy technique with protein suture passed 360° through Schlemm's canal has been mentioned [37].

8.2.3. Trabeculectomy

A trabeculectomy involves creating a full thickness opening in the sclera (sclerotomy) for outflow of aqueous. A partial thickness scleral flap covers the opening and the conjunctiva overlies the flap. Intraocular pressure can be significantly lowered with this. Success rate in adults is usually around 70% - 80%. In children, long term success rate is lower being around 50% [38] due to more aggressive wound healing response in children, which scars down sclerotomy or scleral flap. Children are also more prone to complications such as infections due to eye rubbing.

8.3. Management of Refractory Pediatric Glaucomas (Figure 1)

When the IOP is not controlled after the first surgery, the surgical options are filtration surgery with anti-fibrosis drugs; glaucoma drainage implants or cyclodestructive procedures.

8.3.1. Trabeculectomy with Anti-Fibrotic Agents

Mitomycin-C and 5-Fluorouracil are the two most commonly used anti-metabolites in glaucoma surgery. Although each of these medications decrease the scarring of blebs, they also create more potential for complications such as infection (endophthalmitis) [39-42].

8.3.2. Aqueous Drainage Implants

Implant surgery is an important treatment alternative for PCG patients who are poor candidates for angle incision therapy and trabeculectomy or who have proven to be refractory to these procedures. Glaucoma drainage implants may be characterized as non-restrictive devices such as Molteno and Baerveldt implants or valved such as krupin implants or Ahmed glaucoma valve. Reported complications of implants include hypotony with shallow anterior chamber, choroidal detachments, tube cornea touch, obstructed tube or plate, endophthalmitis and retinal detachment.

The surgical procedure is same for all implants [43]. The superior temporal quadrant is the preferred site. Following periotomy, the implant device is placed with its anterior edge approximately 8mm from limbus. The tube

is shortened and beveled and an incision is made into the anterior chamber to allow entry of tube parallel to iris. The tube is then protected with autologous sclera or pericardium and limbal peritomy is closed.

8.3.3. Cyclodestructive Procedures

These are selectively used for PCG which has proven refractory to medical therapy and to conventional surgical procedures to improve aqueous outflow and work by decreasing aqueous production. The required ciliary epithelial ablation is produced by trans-scleral cyclocryotherapy or by endoscopic diode laser cyclophotocoagulation. The ocular indications include a blind painful eye, a blind eye with high pressure, rapidly deteriorating cornea refractory to all treatment alternatives and, an eye with anatomic defect which preclude other glaucoma procedures.

8.4. Low Vision Rehabilitation

Regrettably, children with congenital glaucoma may end up with low vision despite treatment. Various low vision aids such as magnifiers, binoculars, telescopes are available for such patients to improve their quality of life. Some non-optical devices such as close circuit televisions, large print books exist for their help. Such patients should receive special care and vocational training from trained professionals, working specifically for visually impaired patients, in order to help them develop their abilities to maximum potential [44].

9. Conclusion

The main goal in managing primary congenital glaucoma is early diagnosis and therefore early surgical intervention. Following successful surgery, glasses should be prescribed and care must be taken to manage amblyopia for optimal visual rehabilitation.

REFERENCES

- [1] D. H. Hoskins, R. N. Shaffers and J. Hetherington, "Anatomical Classification of the Developmental Glaucomas," *Archives of Ophthalmology*, Vol. 102, No. 9, 1984, pp. 1331-1336. [doi:10.1001/archophth.1984.01040031081030](https://doi.org/10.1001/archophth.1984.01040031081030)
- [2] S. J. H. Miller, "Genetic Aspects of Glaucoma," *Transactions of the Ophthalmological Society of the UK*, Vol. 86, 1966, pp. 425-434.
- [3] S. C. Debnath, K. D. Teichmann and K. Salamah, "Trabeculectomy versus Trabeculotomy in Congenital Glaucoma," *British Journal of Ophthalmology*, Vol. 73, No. 8, 1989, pp. 608-611. [doi:10.1136/bjo.73.8.608](https://doi.org/10.1136/bjo.73.8.608)
- [4] A. Gencik, "Epidemiology and Genetics of Primary Congenital Glaucoma in Slovakia. Description of a Form of Primary Congenital in Gypsies with Autosomal-Recessive Inheritance and Complete Penetrance," *Developments in Ophthalmology*, Vol. 16, 1989, pp. 76-115.
- [5] V. P. DeLuise and D. R. Anderson, "Primary Infantile Glaucoma (Congenital Glaucoma)," *Survey of Ophthalmology*, Vol. 28, No. 1, 1983, pp. 1-19. [doi:10.1016/0039-6257\(83\)90174-1](https://doi.org/10.1016/0039-6257(83)90174-1)
- [6] R. N. Shaffer, "Genetics and the Congenital Glaucomas," *American Journal of Ophthalmology*, Vol. 60, 1965, pp. 981-994.
- [7] A. E. Kolker and J. Hetherington, "Congenital Glaucoma," In: *Becker-Shaffer's Diagnosis and Therapy of the Glaucomas*, 5th Edition, CV Mosby, St Louis, 1983, p. 317
- [8] M. Sarfarazi and I. Stoilov, "Molecular Genetics of Primary Congenital Glaucoma," *Eye*, Vol. 14, 2000, pp. 422-428. [doi:10.1038/eye.2000.126](https://doi.org/10.1038/eye.2000.126)
- [9] A. N. Akarsu, M. E. Turacli, S. G. Aktan, *et al.*, "A Second Locus (GLC3C) for Primary Glaucoma (Buphthalmos) Maps to the 1p36 Region," *Human Molecular Genetics*, Vol. 5, No. 8, 1996, pp. 1199-1203. [doi:10.1093/hmg/5.8.1199](https://doi.org/10.1093/hmg/5.8.1199)
- [10] I. R. Stoilov and M. Sarfarazi, "The Third Genetic Locus (GLC3C) for Primary Congenital Glaucoma (PCG) Maps to Chromosome 14q24.3," *Investigative Ophthalmology & Visual Science*, Vol. 43, 2002, pp. 1820-1827.
- [11] M. Sarfarazi, A. N. Arkarsu, A. Hossain, *et al.*, "Assignment of a Locus (GLC3A) for Primary Congenital Glaucoma (Buphthalmos) to 2p21 and Evidence for Genetic Heterogeneity," *Genomics*, Vol. 30, No. 2, 1995, pp. 171-178. [doi:10.1006/geno.1995.9888](https://doi.org/10.1006/geno.1995.9888)
- [12] I. Stoilov, A. Nurten and M. Sarfarazi, "Identification of Three Different Truncating Mutations in Cytochrome P4501B1 (CYP1B1) as the Principal Cause of Primary Congenital Glaucoma in Families Linked to the GLC3A on Chromosome 2p21," *Human Molecular Genetics*, Vol. 6, No. 4, 1997, pp. 641-647. [doi:10.1093/hmg/6.4.641](https://doi.org/10.1093/hmg/6.4.641)
- [13] B. A. Bejjani, R. A. Lewis, T. F. Tomey, *et al.*, "Mutations in CYP1B1, the Gene for Cytochrome P4501B1, Are the Predominant Cause of Primary Congenital Glaucoma in Saudi Arabia," *American Journal of Human Genetics*, Vol. 62, No. 2, 1998, pp. 325-333. [doi:10.1086/301725](https://doi.org/10.1086/301725)
- [14] S. G. Panicker, A. N. Mandal, A. B. M. Reddy, V. K. Gothwal and S. E. Hasnain, "Correlations of Genotype with Phenotype in Indian Patients with Primary Congenital Glaucoma," *Investigative Ophthalmology & Visual Science*, Vol. 45, No. 4, 2004, pp. 1149-1156.
- [15] A. T. Johnson, A. V. Drack, A. E. Kwitek, *et al.*, "Clinical Features and Linkage Analysis of a Family Autosomal Dominant Juvenile Glaucoma," *Ophthalmology*, Vol. 100, No. 4, 1993, pp. 524-529.
- [16] V. C. Sheffield, E. M. Stone, W. L. M. Alward, *et al.*, "Genetic Linkage of Familial Open Angle Glaucoma to Chromosome 1q21-q31," *Nature Genetics*, Vol. 4, No. 1, 1993, pp. 47-50. [doi:10.1038/ng0593-47](https://doi.org/10.1038/ng0593-47)
- [17] D. B. Gould, A. J. Mears, W. G. Pearce and M. A. Walter, "Autosomal Dominant Axenfeld-Rieger Anomaly Maps to 6p25," *American Journal of Human Genetics*, Vol. 61, No. 3, 1997, pp. 765-768.

- [doi:10.1016/S0002-9297\(07\)64340-7](https://doi.org/10.1016/S0002-9297(07)64340-7)
- [18] T. Glaser, D. S. Walton and R. L. Mass, "Genomic Structure, Evolutionary Conservative and Aniridia Mutations in the Human PAX6 Gene," *Nature Genetics*, Vol. 2, No. 3, 1992, pp. 232-239. [doi:10.1038/ng1192-232](https://doi.org/10.1038/ng1192-232)
- [19] O. Barkan, "Pathogenesis of Congenital Glaucoma," *American Journal of Ophthalmology*, Vol. 40, 1955, pp. 1-11.
- [20] I. Tugal-Tutkun, K. Havrlikova, W. J. Power and C. S. Foster, "Changing Patterns in Uveitis of Childhood," *Ophthalmology*, Vol. 103, No. 3, 1996, pp. 375-383.
- [21] D. S. Walton, "Pediatric Aphakic Glaucoma: A Study of 65 Patients," *Transactions of the American Ophthalmological Society*, Vol. 93, 1995, pp. 403-413.
- [22] R. N. Shaffer and J. Hetherington Jr., "The Glaucomatous Disc in Infants. A Suggested Hypothesis for Disc Cupping," *Transactions of the American Academy of Ophthalmology & Otolaryngology*, Vol. 73, No. 5, 1969, pp. 923-935.
- [23] K. T. Richardson and R. N. Shaffers, "Optic-Nerve Cupping in Congenital Glaucoma," *American Journal of Ophthalmology*, Vol. 62, No. 3, 1966, pp. 507-509.
- [24] R. N. Jaffar and A. K. Ghulamqadir, "Effect of Oral Choral Hydrate on the Intraocular Pressure Measurement," *Journal of Pediatric Ophthalmology and Strabismus*, Vol. 30, No. 6, 1993, pp. 372-376.
- [25] H. D. Hoskins Jr., J. Hetherington Jr., S. D. Magee, R. Naykhin and C. V. Migliazzo, "Clinical Experience with Timolol in Childhood Glaucoma," *Archives of Ophthalmology*, Vol. 103, No. 8, 1985, pp. 1163-1165. [doi:10.1001/archophth.1985.01050080075024](https://doi.org/10.1001/archophth.1985.01050080075024)
- [26] L. B. Enyedi and S. F. Freedman, "Safety and Efficacy of Brimonidine in Children with Glaucoma," *Journal of AAPOS*, Vol. 5, No. 5, 2001, pp. 281-284. [doi:10.1067/mpa.2001.117571](https://doi.org/10.1067/mpa.2001.117571)
- [27] R. J. Bowman, J. Cope and K. K. Nischal, "Ocular and Systemic Side-Effects of Brimonidine 0.25% Eye Drops (Alphagan in Children)," *Eye*, Vol. 18, 2004, pp. 24-26. [doi:10.1038/sj.eye.6700520](https://doi.org/10.1038/sj.eye.6700520)
- [28] L. I. Larsson and A. Alm, "Aqueous Humor Flow in Human Eyes Treated with Dorzolamide and Different Doses of Acetazolamide," *Archives of Ophthalmology*, Vol. 116, No. 1, 1998, pp. 19-24.
- [29] M. Portellos, E. G. Buckley and S. F. Freedman, "Topical versus Oral Carbonic Anhydrase Inhibitor for Pediatric Glaucoma," *Journal of AAPOS*, Vol. 2, No. 1, 1998, pp. 43-47. [doi:10.1016/S1091-8531\(98\)90109-4](https://doi.org/10.1016/S1091-8531(98)90109-4)
- [30] L. L. Wayman, L. I. Larsson, T. L. Maus and R. F. Brubaker, "Additive Effect of Dorzolamide on Aqueous Humor Flow in Patients Receiving Long Term Treatment with Timolol," *Archives of Ophthalmology*, Vol. 116, No. 11, 1998, pp. 1438-1440.
- [31] R. K. Parrish, P. Palmberg and W. P. Sheu, "A Comparison of Latanoprost, Bimatoprost and Travoprost in Patients with Elevated Intraocular Pressure: A 12-Week, Randomized, Masked-Evaluator Multicenter Study," *American Journal of Ophthalmology*, Vol. 135, No. 5, 2003, pp. 688-703. [doi:10.1016/S0002-9394\(03\)00098-9](https://doi.org/10.1016/S0002-9394(03)00098-9)
- [32] L. B. Enyedi, S. F. Freedman and E. G. Buckley, "The Effectiveness of Latanoprost for the Treatment of Pediatric Glaucoma," *Journal of AAPOS*, Vol. 3, No. 1, 1999, pp. 33-39. [doi:10.1016/S1091-8531\(99\)70092-3](https://doi.org/10.1016/S1091-8531(99)70092-3)
- [33] K. S. Morgan, B. Black, F. D. Ellis and E. M. Helveston, "Treatment of Congenital Glaucoma," *American Journal of Ophthalmology*, Vol. 92, 1981, pp. 799-803.
- [34] K. M. Joos and J. H. Shen, "An Ocular Endoscope Enables a Goniotomy Despite a Cloudy Cornea," *Archives of Ophthalmology*, Vol. 119, No. 1, 2001, pp. 134-135.
- [35] S. D. McPherson Jr. and D. MacFarland, "External Trabeculectomy for Developmental Glaucoma," *Ophthalmology*, Vol. 87, No. 4, 1980, pp. 302-305.
- [36] S. D. McPherson Jr. and D. P. Berry, "Goniotomy vs External Trabeculectomy for Developmental Glaucoma," *American Journal of Ophthalmology*, Vol. 95, No. 4, 1983, pp. 427-431.
- [37] A. D. Beck and M. G. Lynch, "360 Degrees Trabeculectomy for Congenital Glaucoma," *Archives of Ophthalmology*, Vol. 113, No. 9, 1995, pp. 1200-1202. [doi:10.1001/archophth.1995.01100090126034](https://doi.org/10.1001/archophth.1995.01100090126034)
- [38] G. R. Beauchamp and M. M. Parks, "Filtering Surgery in Children: Barriers to Success," *Ophthalmology*, Vol. 86, No. 1, 1979, pp. 170-180.
- [39] A. K. Mandal, D. S. Walton, T. John, *et al.*, "Mitomycin C Augmented Trabeculectomy in Refractory Congenital Glaucoma," *Ophthalmology*, Vol. 104, No. 6, 1997, pp. 996-1003.
- [40] R. Susanna, E. W. Oltrogge, J. C. E. Carani, *et al.*, "Mitomycin as Adjunct Chemotherapy with Trabeculectomy in Congenital and Developmental Glaucomas," *Journal of Glaucoma*, Vol. 4, No. 3, 1995, pp. 151-157. [doi:10.1097/00061198-199506000-00002](https://doi.org/10.1097/00061198-199506000-00002)
- [41] S. Waheed, D. C. Ritterband and D. S. Greenfield, "Bleb-Related Ocular Infection in Children after Trabeculectomy with Mitomycin C," *Ophthalmology*, Vol. 104, No. 12, 1997, pp. 2117-2120.
- [42] M. Zalish, H. Leiba and M. Oliver, "Subconjunctival Injection of 5-Fluorouracil Following Trabeculectomy for Congenital and Infantile Glaucoma," *Ophthalmic Surgery*, Vol. 23, No. 3, 1992, pp. 203-205.
- [43] M. Akimato, H. Tamihara, A. Negi and M. Nagata, "Surgical Results of Trabeculectomy ab Externo for Developmental Glaucoma," *Archives of Ophthalmology*, Vol. 112, No. 12, 1994, pp. 1540-1544.
- [44] A. K. Mandal and D. Chakrabarti, "Update on Congenital Glaucoma," *Indian Journal of Ophthalmology*, Vol. 59, No. 7, 2011, pp. 148-157. [doi:10.4103/0301-4738.73683](https://doi.org/10.4103/0301-4738.73683)