

Intracranial Fungal Infections: Overview from Two Large Tertiary Hospital in Upper Egypt and Literature Review

Mohamed Khallaf^{1*}, Abdin Khair-Allah Kasim²

¹Department of Neurosurgery, Faculty of Medicine, Assiut University, Assiut, Egypt

²Department of Neurosurgery, Faculty of Medicine, Suhaj University, Suhaj, Egypt

Email: *khalaf_1973@yahoo.com

How to cite this paper: Khallaf, M. and Kasim, A.K.-A. (2019) Intracranial Fungal Infections: Overview from Two Large Tertiary Hospital in Upper Egypt and Literature Review. *Open Journal of Modern Neurosurgery*, 9, 184-198.

<https://doi.org/10.4236/ojmn.2019.92018>

Received: April 1, 2019

Accepted: April 25, 2019

Published: April 28, 2019

Copyright © 2019 by author(s) and Scientific Research Publishing Inc. This work is licensed under the Creative Commons Attribution International License (CC BY 4.0).

<http://creativecommons.org/licenses/by/4.0/>



Open Access

Abstract

Purpose: Fungal infections of the central nervous system (CNS) are potentially lethal conditions with high morbidity and mortality. In this review, we summarise the most common clinical manifestations, diagnostic methods, and treatment strategies for intracranial fungal infection at two tertiary care teaching hospitals. **Material and methods:** Prospective hospital study is carried out at Department of Neurosurgery; Assiut and Suhaj University Hospitals between January 2010 to January 2018 (Minimum 12-months follow-up). Radiographs and hospital data of 74 patients with proven intracranial fungal infections were gathered and analyzed. There were no exclusion criteria: age, gender, clinical presentations, immunity status, radiological findings, laboratory, and microbiological data, types of management and outcome. In surgically treated patients, diagnosis was confirmed by pathologic evaluation. Gathered data were coded and entered into a computer and analyzed using SPSS version 22. **Results:** The greatest number of the patients had 40 to 60 years old (49; 66%) and the mean age was 44 years. There was an overwhelming male patient's ranged preponderance 66%; 49 cases. Sixty-three patients (85%) were immunosuppressed; 11 cases (15%) were immunocompetent. The most common causes of immunosuppression were diabetes 27 patients; 43%, on chemotherapeutic agents 19 patients; 31%, on corticosteroid 16 patients; 25% and AIDS in one patient; 1%. Five different fungal types were identified but *Cryptococcus spp.* was the most common cause of CNS fungal infection, occurring in 39 patients (53%). This was followed by *Candida spp.* in 14 patients (19%), *Aspergillus* in 11 patients (15%), *Blastomyces* in 7 patients (9%) and *Coccidioides* in 3 patients (4%). Headache was the most common presenting symptom, occurring in 33 patients (45%). Other relatively common

symptoms were nausea or vomiting 11 patients (15%), fever 10 patients; (13%), seizures 9 patients (12%), acute mental status changes 8 patients; (11%) and stroke like Symptoms 3 patients (4%). Different surgical procedures were done. Stereotactic biopsy is in 19 patients (deep; located in an eloquent region of the brain or multiple small lesion) or excision in 38 patients (cortical, relatively accessible regions of the brain), and CSF shunting in 17 patients. All patients received parenteral and, in some cases, oral antifungal chemotherapy in addition to surgical therapy. Overall mortality was 52.7% (39 deaths). An additional 8 surviving patients exhibited permanent morbidity due to neurological deficits and seizure disorders. **Conclusion:** This prospective population study demonstrates an insight into the intracranial fungal infection and management. CNS fungal infections have increased in frequency, particularly in immunocompromised patients; most infections are caused by *Cryptococcus spp.* Diabetes was the most common cause of immunosuppression and headache was the most common symptom at presentation. CNS fungal infection is still associated with a high mortality and morbidity. Prompt diagnosis; early and appropriate medical and surgical management are fundamental to optimize the outcome.

Keywords

Intracranial Fungal Infection, Immunocompromised, Surgery, Antifungal, Outcome

1. Introduction

Fungal infections of the central nervous system (CNS) are rare clinical entities presenting with protean clinical manifestations, difficult diagnostic dilemmas and special therapeutic challenges. The incidence of fungal infections of the CNS has gradually increased in recent years [1] [2]. There appears to be an increasing incidence of invasive fungal infections from 6.6% from 1993 to 1996 to 10.4% from 2001 to 2005 [3].

This increase in frequency is likely attributed to multiple factors including an aging population, increased use of disease-modifying drugs for treatment of autoimmune disorders, malignancies requiring use of cytotoxic drugs, increased number of bone marrow and solid-organ transplantations requiring long-term use of immunosuppressive agents, and finally, the pandemic spread of HIV/AIDS [4]. Rarely, fungal infection may follow direct inoculation of the brain during intracranial or trans-sphenoidal surgery or following trauma [5].

Intracranial fungal masses were rarely seen even in major neurosurgical centers in Egypt. Egypt has the largest population among the Middle East and North African countries, but fungal diseases are hardly addressed. No multicenter epidemiology studies have been reported, but the incidence of some fungal diseases in Egyptian population at risk has been reported previously from single centers;

mucormycosis [6] dermatophytosis [7].

The CNS fungal infections may present with various clinical syndromes which may be specific for certain fungi. Among these, common syndromes are basal meningitis, hydrocephalus, space-occupying lesions (such as cerebral abscesses, granulomas, etc.) stroke syndromes and spinal infections. There are many unanswered and unresolved epidemiological, laboratory, and clinical questions that need to be addressed and understood in the diagnosis, treatment, and prevention of intracranial fungal lesions.

CNS fungal infection is difficult to diagnose because of the paucity of laboratory tests for it and its nonspecific imaging and clinical features. The low rate of fungal isolation from CSF specimens can also confound the diagnostic accuracy in these patients. In general, symptomatic CNS fungal infection carries higher risks of morbidities and mortality as compared to viral, bacterial, or parasitic CNS disorders. An early recognition and an appropriate medical and surgical management strategies are therefore of paramount importance in improving the overall prognosis in CNS infection.

Our challenge is to develop new non-invasive tests for making an early diagnosis. Simultaneously, we urgently need to commit to the development of new antifungal agents that have a broad spectrum of activity, a good safety profile, excellent pharmacokinetic characteristics and a cost that makes them accessible for the treatment of these mycoses.

It is important to understand that intracranial fungal infection represents one of the greatest challenges to public health services, because of their high incidence of morbidity and mortality and financial cost involved in their management. In this review, we summarise the most common clinical manifestations, diagnostic methods, and treatment strategies for intracranial fungal infection at two tertiary care teaching hospitals as such data base is helpful to clinicians and may spur additional efforts to systematically study these uncommon infections.

2. Patients & Methods

74 Patients with proven intracranial fungal infection were enrolled from 2 participating sites (Assiut and Suhaj Teaching Hospitals). Cases were enrolled prospectively from January 2010, through January 2018 (Minimum 12-months follow-up) with no exclusion criteria. Culture and/or histopathological evidence of tissue invasion by the fungus is the gold standard for diagnosis and is classified as proven disease.

The collected data includes basic demographic data of the cases regarding age, sex, immunity status, clinical presentations, radiological findings, laboratory and microbiological data, types of management and outcome. In surgically treated patients; diagnosis was confirmed by pathologic evaluation. The data were obtained in Excel program. All cases of CNS infections identified via this process were confirmed and coded.

Other body segments were imaged as needed to exclude or detect other system

affection. Collaboration is usually arranged between the teamwork according to the extent of fungal infection and mainly depends on the Neurosurgeons, ENT surgeons. Pediatrician and Ophthalmic surgeon may have a role.

Small fungal SOLs are managed with aggressive antifungal medications and supportive care whereas significantly large lesions may also need craniotomy or stereotactic or guided surgical interventions. Stereotactic biopsy/aspiration is resorted to when the intracranial fungal masses deep seated, located in an eloquent region of the brain or when the masses are multiple. Open craniotomy is performed for suspected intracranial fungal masses that are in relatively accessible regions of the brain and radical excision is feasible and safe. VP shunts were inserted either as primary procedures or as a secondary procedure when patients develop hydrocephalus. Patients underwent a follow-up image (CT scan-MRI brain) according to their neurological condition.

Data was collected in Excel sheet (Microsoft office 2010), then were analyzed using SPSS version 22 (SPSS, Inc., Chicago, IL). The results were expressed as frequency and percent in qualitative data and mean \pm SD for quantitative data.

The study was conducted after getting ethical clearance and the permission from Assiut and Suhaj University Teaching Hospital administration. Thorough explanation of the purpose of the study and how data will be treated with respect and confidentiality was provided to the participants. Informed consent according to the criteria set by the local research ethics committee in our Centres had to be obtained in writing before surgery. If consent could not be obtained because the patient was in coma, consent was obtained from relatives.

3. Results

3.1. Socio Demographic Data

This prospective hospital based, study was carried out on 74 patients with intracranial fungal infections admitted to Department of Neurosurgery, Assiut and Suhaj University Hospitals between January 2010 and January 2018. Patient demographics are provided in **Table 1**. The greatest number of the patients had 40 to 60 years old (49; 66%) and the mean age was 44 years.

There was an overwhelming male patient's ranged preponderance 66%; 49 cases. Sixty-three patients (85%) were immunosuppressed, 11 case (15%) were immunocompetent (**Table 1**). The most common causes of immunosuppression were diabetes 27 patients; 43%, on chemotherapeutic agents 19 patients; 31%, on corticosteroid 16 patients; 25% and AIDS in one patient; 1% (**Table 1**).

3.2. Clinical Data

Table 1 summarizes a variety of clinical syndromes that were seen. Headache was the most common presenting symptom, occurring in 33 patients (45%). Other relatively common symptoms were nausea or vomiting 11 patients (15%), fever 10 patients (13%), seizures 9 patients (12%), acute mental status changes 8 patients (11%) and stroke like Symptoms 3 patients (4%).

Table 1. Demographics of 97 patients CNS fungal infection.

Variable	Number	Percent
Age		
• below 20	7	10%
• 20 - 40	18	24%
• 40 - 60	49	66%
Sex		
• Male	49	66%
• Female	25	34%
Immunosuppressed		
• Yes	63	85%
• No	12	15%
Causes of immunosuppression		
• Diabetes	27	43%
• Chemotherapeutic agents	19	31%
• Corticosteroid	16	25%
• AIDS	1	1%
clinical presentation		
• Headache	33	45%
• Nausea or Vomiting	11	15%
• Fever	10	13%
• Seizures	9	12%
• Acute mental status changes	8	11%
• Stroke like Symptoms	3	4%

3.3. Laboratory and Microbiology Data

As displayed in **Table 2**, five different fungal types were identified but *Cryptococcus spp.* was the most common cause of CNS fungal infection, occurring in 39 patients (53%). This was followed by *Candida spp.* in 14 patients (19%), *Aspergillus* in 11 patients (15%), *Blastomyces* in 7 patients (9%) and *Coccidioides* in 3 patients (4%) (**Table 2**).

3.4. Management and Outcome Data

Stereotactic biopsy is in 19 patients (deep; located in an eloquent region of the brain or multiple small lesion) or excision in 38 patients (cortical, relatively accessible regions of the brain), CSF shunting in 17. All patients received parenteral and, in some cases, oral antifungal chemotherapy in addition to surgical therapy. Overall mortality was 52.7% (39 deaths). An additional 8 surviving patients exhibited permanent morbidity due to neurological deficits, seizure disorders.

Case [1]: Pre-operative CT and MRI T1 weighted image with contrast brain with post-operative CT of left frontal supraorbital fungal mass totally excised confirmed pathologically as Cryptococcosis [**Figure 1**].

Case [2]: Pre and post-operative Ct and MRI brain showing left frontobasal fungal infection with paranasal sinuses involvement totally excised, confirmed pathologically as Blastomycosis [**Figure 2**].

Table 2. Fungal organism types.

Organism Type	Number	Percent
Cryptococcus	39	53%
Candida	14	19%
Aspergillus	11	15%
Blastomyces	7	9%
Coccidiosis	3	4%

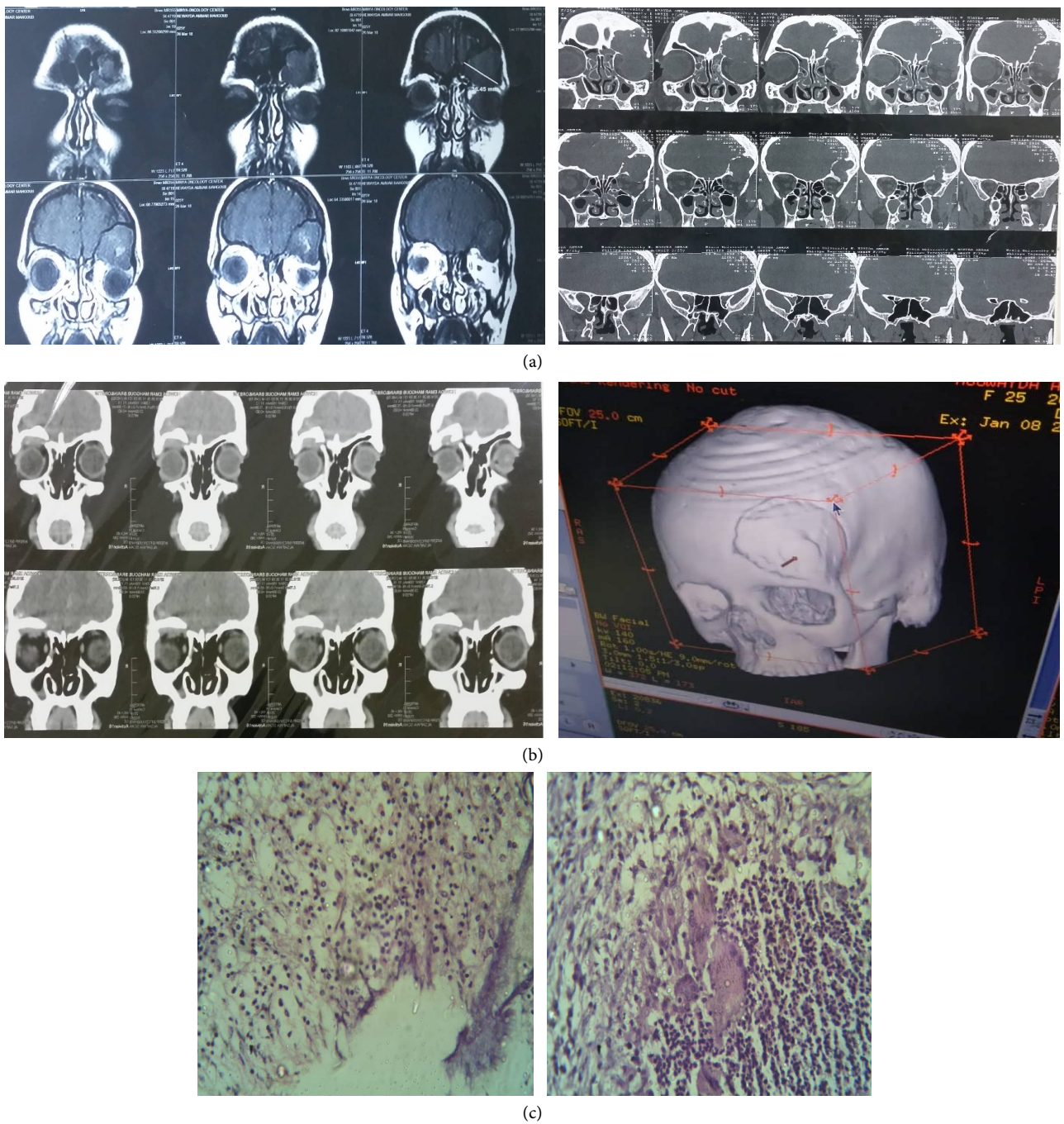


Figure 1. Pre operative (a), post operative; (b) imaging and pathological slid; (c) of cryptococcal fungal infection.

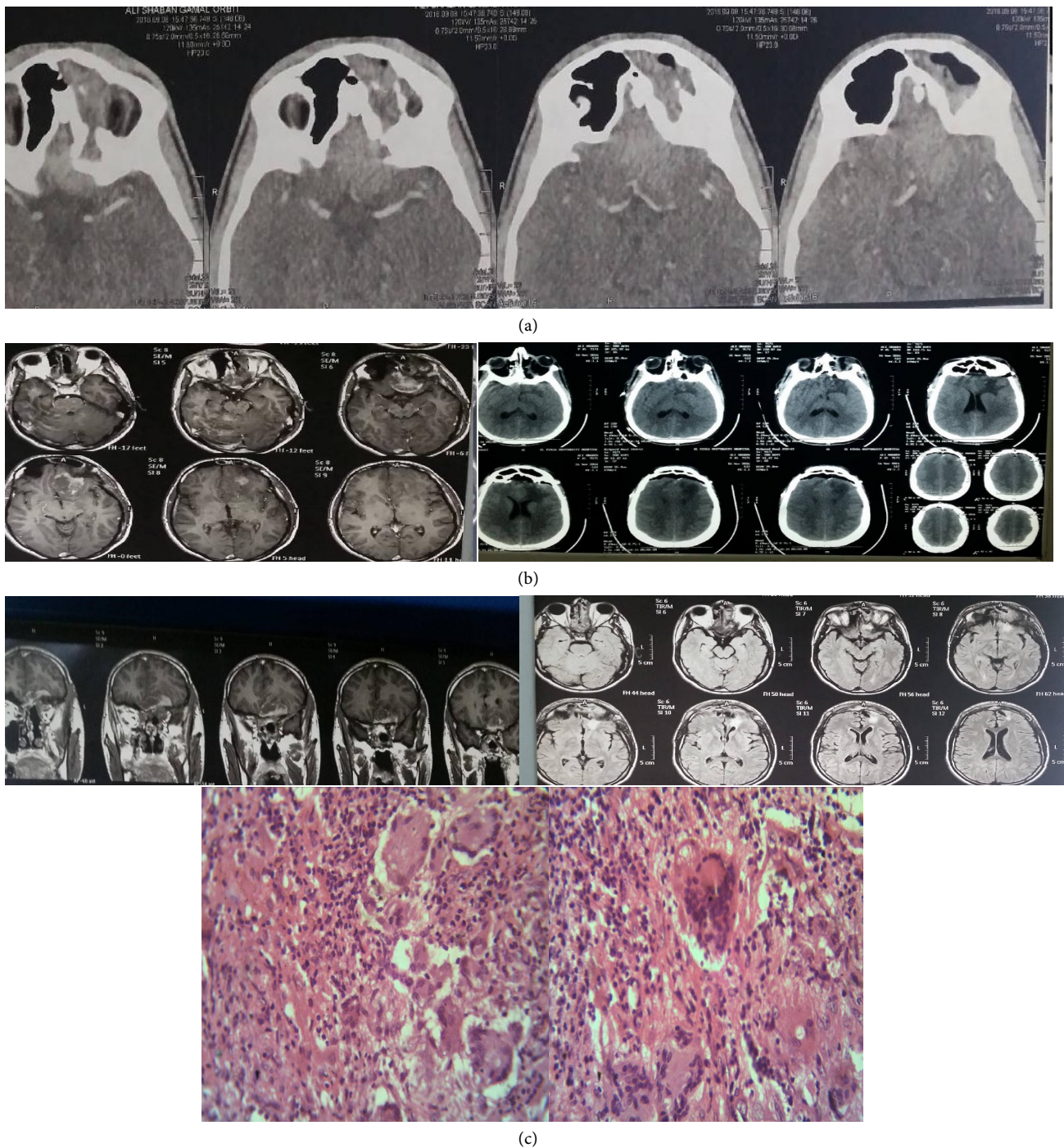


Figure 2. Pre operative (a) and post operative; (b) imaging and pathological slides; (c) of Blastomycosis.

4. Discussion

4.1. Incidence

Intracranial fungal infections are uncommon entities, although, they are being increasingly recognized in recent years due to more elaborative use of intensive care units for serious medical disorders, advancements in transplant procedures and concomitant use of immunosuppressive therapies as well as the pandemic

spread of HIV [8]. In our study; sixty-three patients (85%) were immunosuppressed, 11 cases (15%) were immunocompetent (Table 1). The most common causes of immunosuppression were diabetes 27 patients; 43%, chemotherapeutic agents 19 patients; 31%, corticosteroid 16 patients; 25% and AIDS in one patient; 1% (Table 1). Diabetes is a fast-growing health problem in Egypt with a significant impact on morbidity, mortality, and health care resources. Currently, the prevalence of type 2 diabetes (T2D) in Egypt is around 15.6% of all adults aged 20 to 79 [9].

4.2. Types of Organism

Identifying the etiological agent as fungal and not bacterial is vital since antibacterial therapy is not effective against fungi and CNS mycoses lead to high morbidity and mortality. Although >100 thousand fungal species are recognized, only a couple of hundred have been suggested to be pathogenic to humans and 10% - 15% of pathological fungi produce systemic and/or central nervous system (CNS) mycosis [4]. The common fungal pathogens that cause intracranial infections include *Candida*, *Aspergillus*, *Mucor*, *Cryptococcus saccharomyces*, *Northcardia brasiliensis*, and *Histoplasma* [10]. Similar findings were noted in our patient population, with 39 patients (53%) with CNS fungal infection attributed to *Cryptococcus*. This was followed by *Candida spp.* in 14 patients (19%), *Aspergillus* in 11 patients (15%), *Blastomyces* in 7 patients (9%) and *Coccidiosis* in 3 patients (4%) (Table 2).

The CNS fungal infections usually result from pulmonary, intestinal, cardiac, or craniofacial mycoses and therefore intracranial seedlings occur either during hematogenous dissemination or by direct extension from the juxta-cranial sites. Direct contiguous spread to the CNS occurs from the paranasal sinuses, orbits, petro-mastoid region and retro-pharyngeal area in some patients. Direct implantation may result during the period of trauma, intensive care procedures and intracranial operations.

4.3. Clinical Presentation

Despite the aggressive nature of these infections, presenting symptoms can be subtle and nonspecific, and even patients with disseminated fungal infection with multiorgan involvement may not present with organ-specific changes or clinical signs. So appreciation of the patient's medical history (maintaining a high degree of clinical suspicion for immunocompromised patients) is the first step to making the correct diagnosis.

Intracranial fungal masses can be seen in any age group but most patients are in the third, fourth and fifth decades of life. Similar findings were noted in our patient population, with the greatest number of the patients had 40 to 60 years old (49; 66%) and mean age was 44 years (Table 1). There was an overwhelming male patient's ranged preponderance 66%; 49 cases (Table 1). They have been reported even in neonates, infants and young children. The duration of its

symptoms, which ranges from days to months and years, differs in accordance with the progress and timely diagnosis of the disease.

The clinical presentation may be classified as diffuse and focal infections. Diffuse infection is characterized by meningitis, is mainly caused by *Cryptococcus* and *Candida albicans*. Clinical features of fungal meningitis and meningoencephalitis are usually reported as headaches, fever, nausea, vomiting, visual impairment, papilledema, seizure, and acute mental status changes [4]. Similar findings were noted in our patient population, with headache being the most common initial clinical presentation in thirty-three patients 45% (Table 1). Localized form in the macrospore and capsular tissue. Focal infection mainly manifests as granuloma and abscess and is caused by *Aspergillus*, *Candida*, *zygomycetes*, and some species of black fungus [10].

Rarely, patients with fungal aneurysms (commonly involve the proximal intracranial vessels especially the intradural portion of the internal carotid artery) are present with subarachnoid hemorrhage [11]. Interestingly, fever is an infrequent symptom in patients with intracranial fungal masses and is seen in only 10% - 31% of patients [12] [13]. Similar findings were noted in our patient were fever represented in 10 patients; (13%) (Table 1).

CNS fungal granulomas are commonly produced by Aspergillosis, Histoplasmosis, Blastomycosis, Paracoccidioidomycosis, Cyclosporiasis, Mucormycosis, Cryptococcosis, etc. Aspergillosis and Mucormycosis of the paranasal sinuses infect the subjacent meninges and brain parenchyma to produce frontal and temporal granulomas whereas hematogenous spread of other fungi from elsewhere produces parietal granulomas in general. Additionally, patients with any of these presentations might manifest features of raised intracranial pressure, seizures and altered sensorium [14]. Spinal fungal infections are relatively rare entities and may present as intradural, extradural and/or vertebral lesions. Spinal column may be affected from upper cervical to the sacral region; however, upper thoracic level of the spine is most commonly affected [15].

4.4. Laboratory Investigations

It includes conventional and biochemical examination of the CSF; pathogenic test of the CSF; immunologic test [16]. Galactomannan antigen testing in CSF showed a sensitivity of 88% and a specificity of 96% for CNS Aspergillosis [17]. CSF antigen testing was found to have a sensitivity of 93% and specificity of 100% for Coccidioidal meningitis [18]. β -D-glucan testing of CSF demonstrated 100% sensitivity and 98% specificity for meningitis caused by *E. rostratum* [19].

4.5. Imaging

Computed tomography (CT) and magnetic resonance (MR) imaging techniques provide the most meaningful image-based examination of fungal infections, particularly mycotic infection, of the CNS [20] [21]. It can be helpful in determining extra-CNS sources of infection, such as sinusitis or mastoiditis [22]. However

imaging diagnosis should not be considered as a replacement for pathological or microbiological diagnosis as anti-fungal agents are generally toxic and should not be administered on a long-term basis to any patient without definitive diagnosis of a fungal infection.

CT and MRI only reveal intracranial mass or masses that enhance with contrast and can also provide evidence of involvement of the paranasal sinuses and the mastoid sinus. Based on the presence or absence of radiological evidence of paranasal sinus disease; intracranial fungal masses were classified into two types: rhinocerebral type and purely intracranial type that was further divided into intracerebral or extracerebral forms [23].

It has been postulated that MR appearances are characteristic for intracranial fungal masses caused by different fungal agents. Cryptococcomas appear as hypointense masses on T2W images whereas Aspergillomas have an intermediate signal intensity on T2W sequences [13]. During growth, abscessed lesions associated with fungal infection display irregular, discontinuous, thick wall ring reinforcements. Some clinicians refer to the “open loop” as the characteristic presentation of intracranial fungal infection [24].

The commonest location for a primary intracranial fungal masses is the supratentorial compartment with the majority of lesions being present in the frontal lobes followed by temporal lobes. The posterior fossa structures are very infrequently involved especially by isolated infections and may only be occasionally involved when there are several intracranial fungal masses [14].

4.6. Management

There are many unanswered questions related to the management of CNS fungal infections and their medications. Therefore, management controversies are abounding and the available data do not provide satisfactory answers to questions and controversies. CNS fungal infections often require treatment by a multidisciplinary team. Unquestionably, CNS fungal infections pose serious challenges in their management with controversies surrounding their medical and surgical therapies. Surgical approach combined with medical therapy is the most successful method of treating suspected fungal central nervous system (CNS) infections [25]. Control of diabetes, radical surgical procedures to the orbit and paranasal sinuses (Excision of necrotic and infected tissues as well as the drainage of paranasal sinuses), are needed.

4.6.1. Antifungal

The early initiation of antifungal medication is crucial, and the choice of medication should be based on its pharmacologic properties and available supporting evidence and it is the mainstay of therapy because early therapy has been shown to limit progression of disease and because the performance of diagnostic testing remains limited [26] [27]. There are many questions and controversies ranging from the choice of antifungal medications in CNS mycoses to calculation of their doses, and the route of administration as well as effective therapeutic combina-

tions.

Recent advances in antifungal pharmacotherapy are attempting to provide drugs with their greater efficacy and lesser toxicity especially in such invasive CNS fungal infection. Among the antifungal drugs, the Amphotericin B had remained first line of therapy for many decades in invasive fungal infections but is not effective in many forms of mycoses [28]. Fortunately, many useful antifungal drugs were introduced during the last two decades; the new triazoles and most recently, echinocandins. These medications are used more frequently in combinations [29].

4.6.2. Surgical Options

Surgical options are less controversial in cases of focal or localized superficial cortico-subcortical lesions (such as abscesses and granulomas) in the non-eloquent areas of the brain. Whereas invasive multifocal lesions, deep cerebral and or brain stem lesions, focal lesions rapidly spreading to involve large parts of the brain and major vascular invasions are usually not surgically amenable or curable.

Surgery for intracranial fungal masses can be of different types, namely stereotactic procedures; craniotomy; shunt surgery; and treatment of fungal aneurysms. Generally, radical surgery is advocated for intracranial fungal masses but there is no unanimity regarding the radicality of the excision especially for the rhinocerebral form of the disease. Surgery should always be followed by antifungal therapy for prolonged periods.

4.6.3. Stereotactic Procedures

Stereotactic biopsy/aspiration is resorted to when the intracranial fungal masses is deep seated (e.g. ganglionic, brain stem, thalamus), located in an eloquent region of the brain (e.g. motor regions) or when the masses are multiple and the object of surgery is to arrive at a diagnosis and obtain pus/tissue for culture studies [30]. Stereotactic craniotomies might also be done in patients with intracranial fungal masses to reduce the morbidity of a craniotomy procedure and shorten the duration of the surgery [31]. In our study; stereotactic biopsy was done in 19 patients (deep; located in an eloquent region of the brain or multiple small lesion).

4.6.4. Open Craniotomy

Open craniotomy is performed for suspected intracranial fungal masses that are in relatively accessible regions of the brain and radical excision is feasible and safe. Open surgery is also done often when the diagnosis of intracranial fungal masses is not suspected [13]. In our study; excision was indicated in 38 patients (cortical, relatively accessible regions of the brain). From the literature, there is no conclusive evidence that radical and aggressive surgery improves outcome in patients with intracranial fungal masses but a reasonably radical approach would be advisable whenever it is feasible without severe morbidity or additional neu-

rological deficits [13].

4.6.5. Shunt

Several authors have documented the need for VP shunts in patients with intracranial fungal masses either as primary procedures or as a secondary procedure when patients with intracranial fungal masses on medical therapy develop hydrocephalus. It is presumed that hydrocephalus in these patients is the result of arachnoiditis of the basal cisterns producing a communicating type of hydrocephalus. CSF shunting was inserted in 17 patients in our series.

4.7. Prognosis and Outcome

Despite the introduction of novel agents into the armamentarium of antifungal therapies in the past decade, the incidence of and mortality associated with invasive fungal infections remain far higher than hoped, and these infections continue to pose a challenge for the medical community. High mortality and morbidity have been uniformly reported in almost all series of patients with intracranial fungal masses. The mortality rates range from around 40% in immunocompetent patients to 92% in transplant recipients [14]; 63% was in Dubey *et al.* series [13]; 66.7% in the series reported by Siddiqui *et al.* [32] and 50% in Njambi [33] 2007, Selby R1997 series [34]. In our series; the mortality rate was 52%.

The major cause of mortality and morbidity is the involvement of major cerebral blood vessels by the fungi leading to major strokes. Vasculitis seems to be a frequent sequel to surgery for intracranial fungal masses in the skull base region and several authors have recorded mortality due to stroke following surgery for such lesions [35]. The other reason for poor outcome in immunocompetent patients with intracranial fungal masses is the delay in diagnosis. Finally, some of the mortality and morbidity in patients with intracranial fungal masses is also attributable to the antifungal agents. Amphotericin B is notorious for causing renal and liver failure and has other serious side effects.

There were several important study limitations. The sample size was not large enough to provide strong evidence for clinical practice. CNS fungal infection is difficult to diagnose because of the paucity of laboratory tests for it and its non-specific imaging and clinical features making it difficult to capture all of the CNS fungal infections seen at our two centers during the study time period. The strength of our study is that it was based on a defined population without selection based on examined, operated and followed up by the authors only as neither neurosurgical treatment nor neurosurgical intensive care was available in other institutions in our area.

5. Conclusion

Fungal infections of CNS are rare clinical entities presenting with various clinical presentation, difficult diagnostic dilemmas and special therapeutic challenges with a high mortality rate not only in immunocompromised but also in immunocompetent patients. Increased prevalence of diabetes associated with the ex-

tensive uses of corticosteroids and cytotoxic drugs have increased the frequency of CNS infection. *Cryptococcus* species and *Candida spp.* predominate among fungal infections of the CNS. CNS fungal infections often require treatment by a multidisciplinary team. A surgical approach (stereotactic biopsy and/or partial or radical surgical excision of the mass) combined with antifungal therapy is the most successful method of treating suspected fungal infections.

Acknowledgements

We would like to thank Dr. Osama Ramadan; Assistant lecturer of Neurosurgery; Assiut University Hospital for his kind assistance in providing data collection and statistical support during the analysis of the study data.

Conflicts of Interest

The authors state no conflicts of interest.

Financial Support and Sponsorship

Nil.

References

- [1] Raparia, K., Powell, S.Z., Cernoch, P. and Takei, H. (2010) Cerebral Mycosis: 7-Year Retrospective Series in a Tertiary Center. *Neuropathology*, **30**, 218-223. <https://doi.org/10.1111/j.1440-1789.2009.01067.x>
- [2] Rajshekhar, V. (2007) Surgical Management of Intracranial Fungal Masses. *Neurology India*, **55**, 267-273. <https://doi.org/10.4103/0028-3886.35688>
- [3] Lehrnbecher, T., Frank, C., Engels, K., Kriener, S., Groll, A.H., Schwabe, D., Sharma, R.R. and Gurusinge, N.T. (2010) Trends in the Postmortem Epidemiology of Invasive Fungal Infections at a University Hospital. *Journal of Infection*, **61**, 259-265. <https://doi.org/10.1016/j.jinf.2010.06.018>
- [4] Sharma, R.R. (2010) Fungal Infections of the Nervous System: Current Perspective and Controversies in Management. *International Journal of Surgery*, **8**, 591-601. <https://doi.org/10.1016/j.ijssu.2010.07.293>
- [5] Sharma, R.R., Gurusinge, N.T. and Lynch, P.G. (1992) Cerebral Infarction Due to *Aspergillus arteritis* Following Glioma Surgery. *British Journal of Neurosurgery*, **6**, 485-490. <https://doi.org/10.3109/02688699208995040>
- [6] Zaki, S.M., Elkholy, I.M., Elkady, N.A. and Abdelghany, K. (2014) Mucormycosis in Cairo, Egypt: Review of 10 Reported Cases. *Medical Mycology*, **52**, 73-80. <https://doi.org/10.3109/13693786.2013.809629>
- [7] Zaki, S.M., Ibrahim, N., Aoyama, K., Shetaia, Y.M., Abdel-Ghany, K. and Mikami, Y. (2009) Dermatophyte Infections in Cairo, Egypt. *Mycopathologia*, **167**, 133-137. <https://doi.org/10.1007/s11046-008-9165-5>
- [8] Gavito-Higuera, J., Mullins, C.B., Ramos-Duran, L., Chacon, C.I.O., Hakim, N. and Palacios, E. (2016) Fungal Infections of the Central Nervous System: A Pictorial Review. *Journal of Clinical Imaging Science*, **6**, 24. <https://doi.org/10.4103/2156-7514.184244>
- [9] Hegazi, R., El-Gamal, M., Abdel-Hady, N. and Hamdy, O. (2015) Epidemiology of and Risk Factors for Type 2 Diabetes in Egypt. *Annals of Global Health*, **81**, 814-820.

- <https://doi.org/10.1016/j.aogh.2015.12.011>
- [10] Li, X. and Li, X. (2017) Progress in the Treatment of Fungal Infections of the Central Nervous System. *Infection International*, **6**, 61-65.
<https://doi.org/10.1515/ii-2017-0161>
- [11] Hurst, R.W., Judkins, A., Bolger, W., Chu, A. and Loevner, L.A. (2001) Mycotic Aneurysm and Cerebral Infarction Resulting from Fungal Sinusitis: Imaging and Pathological Correlation. *American Journal of Neuroradiology*, **22**, 858-863.
- [12] Nadkarni, T. and Goel, A. (2005) Aspergilloma of the Brain: An Overview. *Journal of Postgraduate Medicine*, **51**, 37-41.
- [13] Dubey, A., Patwardhan, R.V., Sampath, S., Santosh, V., Kolluri, S. and Nanda, A. (2005) Intracranial Fungal Granuloma: Analysis of 40 Patients and Review of the Literature. *Surgical Neurology*, **63**, 254-260.
<https://doi.org/10.1016/j.surneu.2004.04.020>
- [14] Rajshekhar, V. (2007) Surgical Management of Intracranial Fungal Masses. *Neurologia India*, **55**, 267-273. <https://doi.org/10.4103/0028-3886.35688>
- [15] Bennett, J.E. (2005) Introduction to Mycoses. In: Mandell, G.L., Bennett, J.E., Dolin, R., Eds., *Mandell, Douglas, and Bennett's Principles and Practice of Infectious Diseases*, 6th Edition, Churchill Livingstone, London, 2935e8.
- [16] Fan, J., He, J., Wu, D., *et al.* (2010) Clinical Manifestation and Laboratory Diagnosis of Common Fungal Infection Diseases of the Central Nerve System. *J. Brain Nerv. Dis.*, **18**, 473-476.
- [17] Chong, G.M., Maertens, J.A., Lagrou, K., Driessen, G.J., Cornelissen, J.J. and Rijnders, B.J. (2016) Diagnostic Performance of Galactomannan Antigen Testing in Cerebrospinal Fluid. *Journal of Clinical Microbiology*, **54**, 428-431.
<https://doi.org/10.1128/JCM.02913-15>
- [18] de Pauw, B., Walsh, T.J., Donnelly, J.P., *et al.* (2008) Revised Definitions of Invasive Fungal Disease from the European Organization for Research and Treatment of Cancer/Invasive Fungal Infections Cooperative Group and the National Institute of Allergy and Infectious Diseases Mycoses Study Group (EORTC/MSG) Consensus Group. *Clinical Infectious Diseases*, **46**, 1813-1821. <https://doi.org/10.1086/588660>
- [19] Litvintseva, A.P., Lindsley, M.D., Gade, L., *et al.* (2014) Utility of (1-3)- β -D-Glucan Testing for Diagnostics and Monitoring Response to Treatment during the Multistate Outbreak of Fungal Meningitis and Other Infections. *Clinical Infectious Diseases*, **58**, 622-630. <https://doi.org/10.1093/cid/cit808>
- [20] Jiménez Caballero, P.E. and Mollejo Villanueva, M. (2009) Cerebral Aspergilloma in an Immunocompetent Patient: Radiological and Histopathological Findings. *Neurología*, **24**, 275.
- [21] Ferrés, G.M., Bidart, H.T. and Zubieta, A.M. (2010) Importance of Images and Etiological Diagnosis of Central Nervous System Involvement in Immunocompromised Patient. *Revista chilena de infectología*, **27**, 541-543.
<https://doi.org/10.4067/S0716-10182010000700009>
- [22] Wahba, H., Truong, M.T., Lei, X., *et al.* (2008) Reversed Halo Sign in Invasive Pulmonary Fungal Infections. *Clinical Infectious Diseases*, **46**, 1733-1737.
<https://doi.org/10.1086/587991>
- [23] Sharma, B.S., Khosla, V.K., Kak, V.K., Banerjee, A.K., Vasishtha, R.K., Prasad, K.S., *et al.* (1997) Intracranial Fungal Granuloma. *Surgical Neurology*, **47**, 489-497.
[https://doi.org/10.1016/S0090-3019\(96\)00209-1](https://doi.org/10.1016/S0090-3019(96)00209-1)
- [24] Chen, Y., He, Y., Li, W., *et al.* (2010) CT and MRI Manifestation of the Intracranial

Fungal Infection. *Journal of Imaging Intervention*, **7**, 66-68.

- [25] Neves, N., Santos, L., Reis, C. and Sarmiento, A. (2014) *Candida albicans* Brain Abscesses in an Injection Drug User Patient: A Case Report. *BMC Research Notes*, **7**, 837. <https://doi.org/10.1186/1756-0500-7-837>
- [26] Greene, R.E., Schlamm, H.T., Oestmann, J.W., *et al.* (2007) Imaging Findings in Acute Invasive Pulmonary Aspergillosis: Clinical Significance of the Halo Sign. *Clinical Infectious Diseases*, **44**, 373-379. <https://doi.org/10.1086/509917>
- [27] Cornely, O.A., Maertens, J., Bresnik, M., *et al.* (2007) Liposomal Amphotericin B as Initial Therapy for Invasive Mold Infection: A Randomized Trial Comparing a High-Loading Dose Regimen with Standard Dosing (AmBiLoad Trial). *Clinical Infectious Diseases*, **44**, 1289-1297. <https://doi.org/10.1086/514341>
- [28] Karthaus, M. (2010) Guideline Based Treatment of Invasive Aspergillosis, *Mycoses*, **53**, 36-43. <https://doi.org/10.1111/j.1439-0507.2009.01840.x>
- [29] Schwartz, S. and Thiel, E. (2009) Cerebral Aspergillosis: Tissue Penetration Is the Key. *Medical Mycology*, **47**, S387-S393. <https://doi.org/10.1080/13693780802537953>
- [30] Arunkumar, M.J., Rajshekhar, V., Chandy, M.J., Thomas, P.P. and Jacob, C.K. (2000) Management and Outcome of Brain Abscess in Renal Transplant Recipients. *Postgraduate Medical Journal*, **76**, 207-211. <https://doi.org/10.1136/pmj.76.894.207>
- [31] Middelhof, C.A., Loudon, W.G., Muhonen, M.D., Xavier, C. and Greene, C.S. (2005) Improved Survival in Central Nervous System Aspergillosis: A Series of Immunocompromized Children with Leukemia Undergoing Stereotactic Resection of Aspergillomas. Report of Four Cases. *Journal of Neurosurgery*, **103**, 374-378. <https://doi.org/10.3171/ped.2005.103.4.0374>
- [32] Siddiqui, A.A., Shah, A.A. and Bashir, S.H. (2004) Craniocerebral Aspergillosis of Sinonasal Origin in Immunocompetent Patients: Clinical Spectrum and Outcome in 25 Cases. *Neurosurgery*, **55**, 602-613. <https://doi.org/10.1227/01.NEU.0000134597.94269.48>
- [33] Njambi, S., Huttova, M., Kovac, M., Freybergh, P.F., Bauer, F. and Muli, J.M. (2007) Fungal Neuroinfections: Rare Disease But Unacceptably High Mortality. *Neuroendocrinology Letters*, **28**, S25-S26.
- [34] Selby, R., Ramirez, C.B., Singh, R., Kleopoulos, I., Kusne, S., Starzl, T.E. and Fung, J. (1997) Brain Abscess in Solid Organ Transplant Recipients Receiving Cyclosporine-Based Immunosuppression. *The Archives of Surgery*, **132**, 304-310. <https://doi.org/10.1001/archsurg.1997.01430270090019>
- [35] Nadkarni, T. and Goel, A. (2005) Aspergilloma of the Brain: An Overview. *Journal of Postgraduate Medicine*, **51**, s37-s41.