



# Rare Case of Kleine-Levin Syndrome with Mega Cisterna Magna

Abdul-Rahman Sallam Alqubaty<sup>1</sup>, Hadi Mohammed Mujlli<sup>2\*</sup>, Zumurudah Taha Haroon<sup>1</sup>

<sup>1</sup>Neurology Department, Medical College, Sana'a University, Sana'a, Yemen

<sup>2</sup>Medical Department, Medical College, Thamar University, Dhamar, Yemen

Email: Neuroepileptic.center@gmail.com, <sup>\*</sup>dr.hadimujlli@gmail.com, dr.zumurudah@hotmail.com

Received 12 March 2016; accepted 26 March 2016; published 30 March 2016

Copyright © 2016 by authors and OALib.

This work is licensed under the Creative Commons Attribution International License (CC BY).

<http://creativecommons.org/licenses/by/4.0/>



Open Access

## Abstract

Kleine-Levin syndrome (KLS) is an uncommon syndrome characterized by recurrent episodes of hypersomnia, behavioural and/or cognitive disturbances, abnormal eating and hypersexual behaviour. The diagnosis is clinical and requires a high index of suspicion and exclusion of other neurological conditions and sleep disorders. We report a case of 15-year-old male who had recurrent episodes of hypersomnia with hyperphagia, hypersexuality, disinhibition and cognitive dysfunction. His brain CT scan shows Mega cistern magna and EEG during the episode shows sharp and spike wave in both frontal and temporal lobes with secondary generalization. The patient became symptom-free after receiving Na Valporate.

## Keywords

Kleine-Levin Syndrome (KLS), Mega Cisterna Magna, Na Valporate

**Subject Areas:** Neurology

## 1. Introduction

Kleine-Levin syndrome is a recurrent hypersomnia characterized by episodes of hypersomnia separated by intervening periods of normal behavior. In addition to hypersomnia, at least one of the following symptoms must be present: cognitive or mood disturbances, hyperphagia with compulsive eating, hypersexuality, or abnormal behavior such as irritability, aggression, or personality changes [1].

The exact prevalence of KLS is unknown, but it is considered a very rare disease, possibly affecting one in a million. The literature search by Arnulf *et al.* in Pub Med between 1962 and 2004 in English and non-English languages found 186 cases [2].

It was suggested that KLS could result from viral or post infectious autoimmune encephalitis with a primary

\*Corresponding author.

involvement of the hypothalamus because of the important role of this structure in regulating sleep and behavior [1].

Mega cisterna magna is a part of “Dandy-Walker Complex” and it is characterized by the enlargement of the cisterna magna, morphologically intact vermis and cerebellar hemispheres [3].

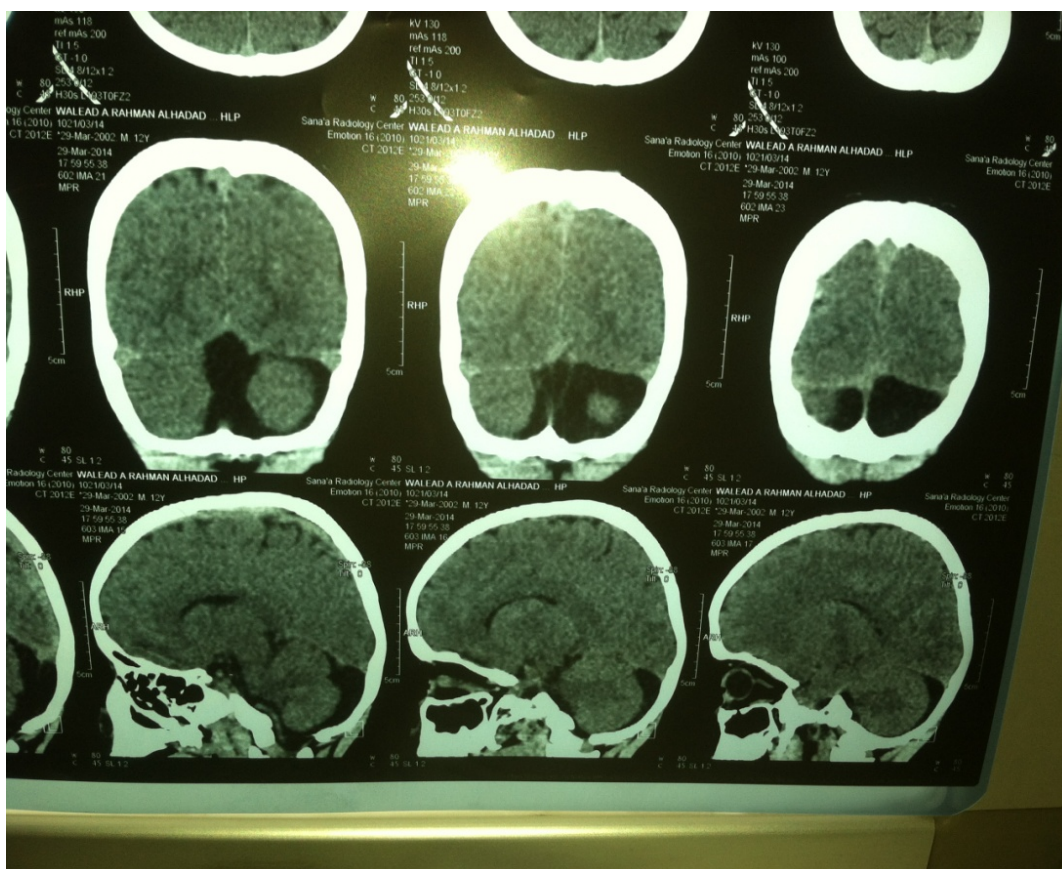
## 2. Case Presentation

Our patient is male and 13 years old, his past history was uneventful, as his peripartum period and milestone were normal and no past history of fever or trauma of neurological importance. He was in good health, normal behaviour and good academic achievement until two years ago, when his academic achievement decline due to decrease his cognitive abilities as decrease concentration and learning difficulties, meanwhile patient had episodic attacks of hyperphagia, hyper sexuality, disinhibition, aggression and hypersomnia lasting for 8 to 10 days and in between the episodes he is normal and forgetful for the previous event unless from the cognitive dysfunction. He received antipsychotic drugs with no any improvement.

There was no family history of consanguinity or similar condition.

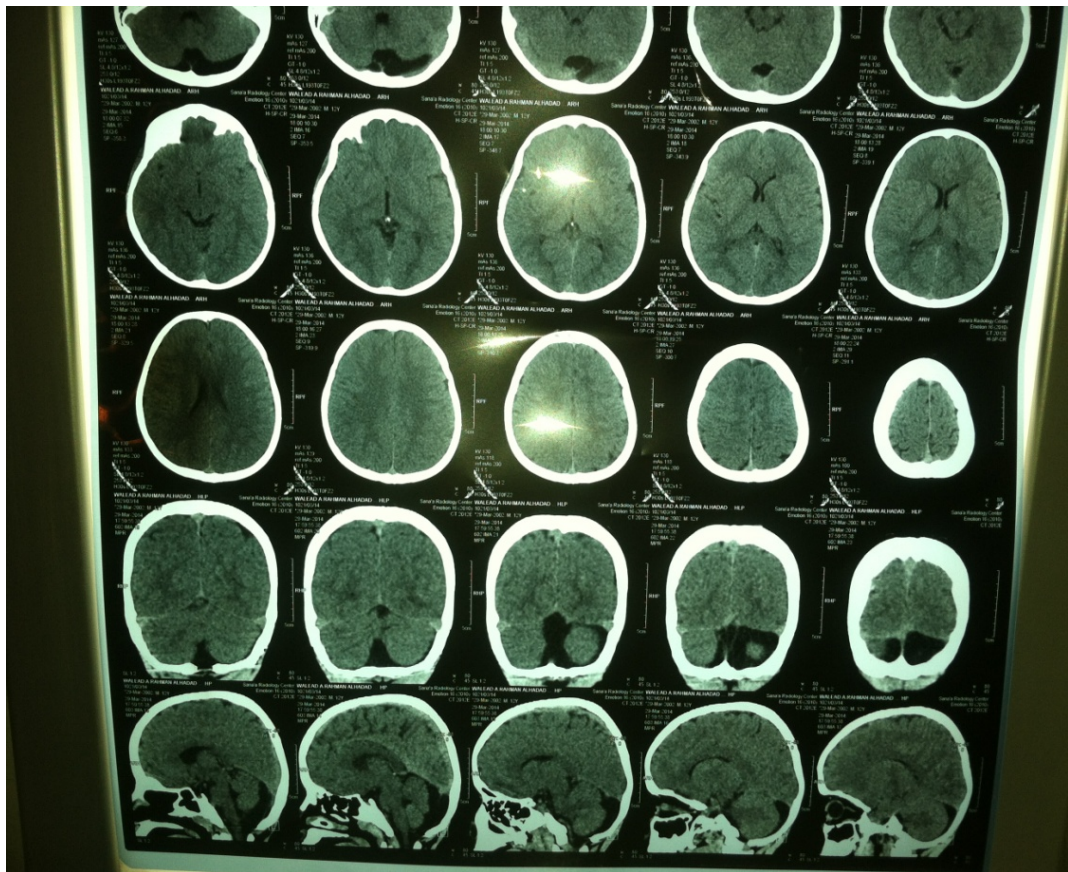
His neurological examination was normal, the laboratory test for complete blood count, serum electrolyte including (Na, K, Mg, Cl), liver function, kidney function and thyroid and parathyroid hormones were normal. The Brain CT scan shows Mega cisterna magna (Figure 1, Figure 2).

His EEG recording during the episode shows focal discharge as sharp and spike waves in the frontal and temporal lobes at both hemispheres with secondary generalization, while in between the episode the secondary generalization is absent (Figure 3, Figure 4). Then patient received Na Valporate in proper dose according to his body weight and after 3 months duration from starting treatment he was completely free from his previous condition including marked improvement if his cognitive function and academic achievement.



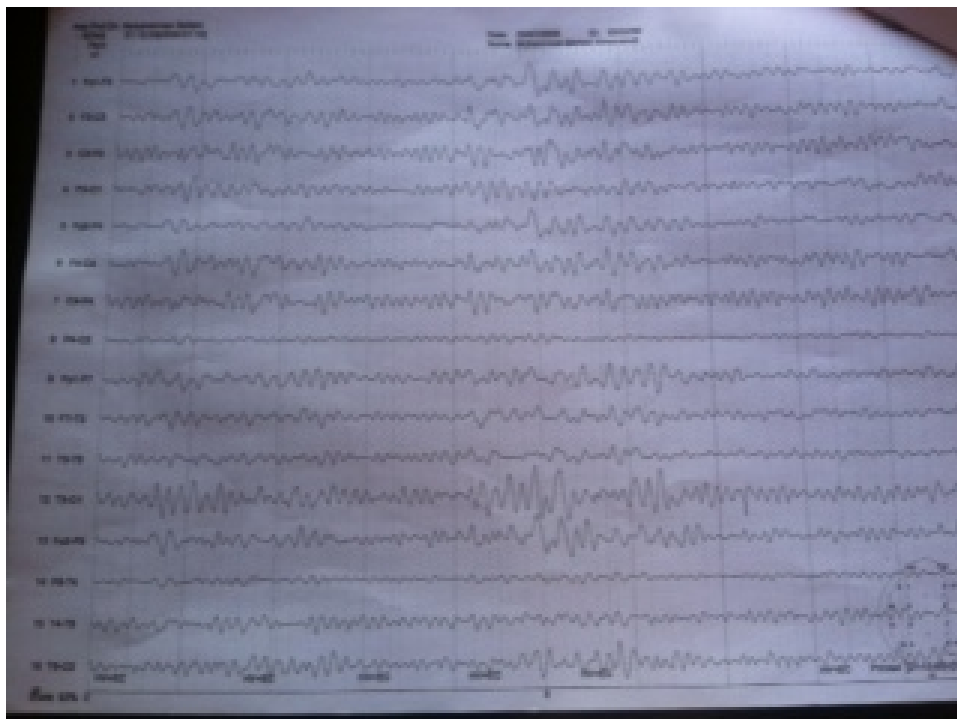
N.B: There are light flashes from the camera in some cut of film

**Figure 1.** Bain CT scan.



N.B: There are light flashes from the camera in some cut of film

**Figure 2.** Bain CT scan.



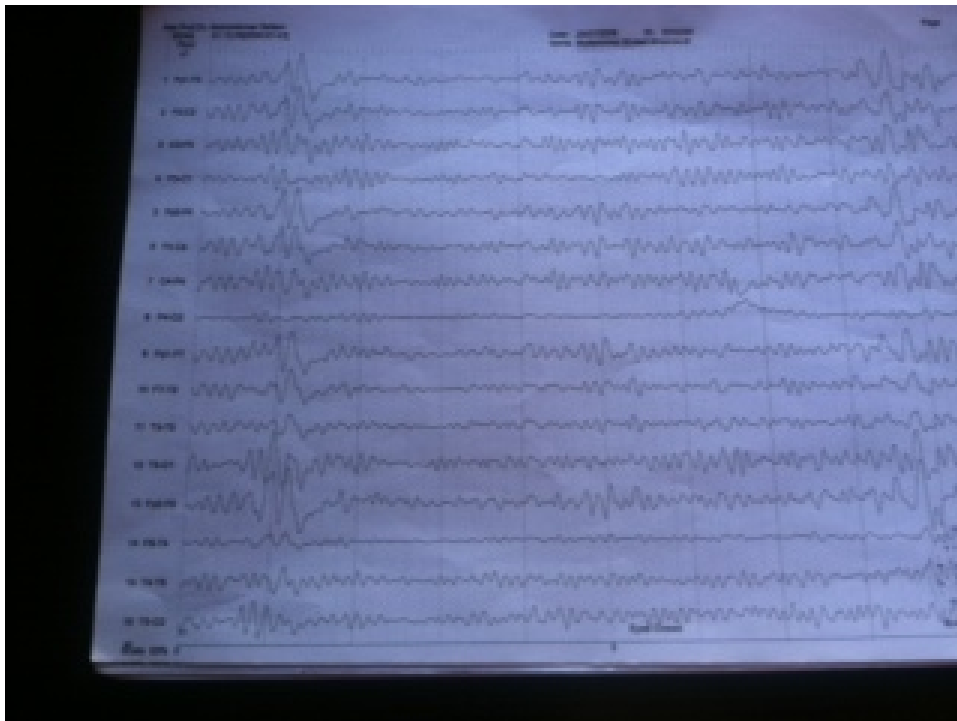


Figure 3. EEG during the episode.

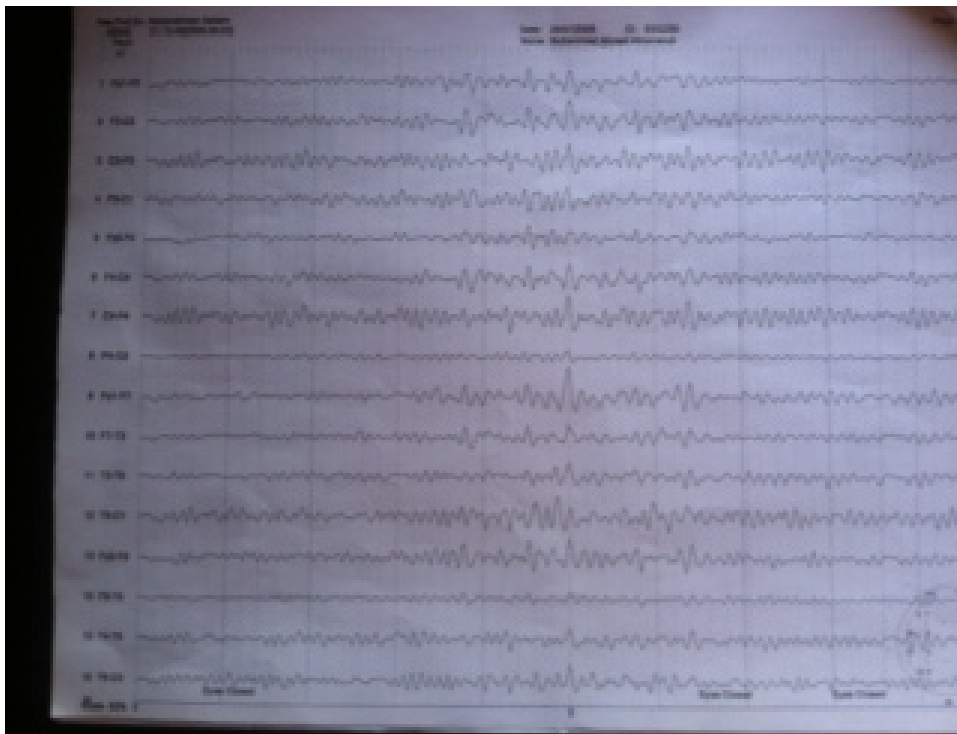


Figure 4. EEG in between the episodes.

EEG recording during the episode shows focal discharge as sharp and spike waves in the frontal and temporal lobes at both hemispheres with secondary generalization.

EEG in between the episodes the secondary generalization is absent.

### 3. Discussion

Considering the pathophysiology of KLS, the hypothalamic hypo-metabolism may implicate sleep regulation, control of food intake, and sexual behavior. The decreased orbitofrontal and anterior parasagittal brain metabolism may correlate with motivational and behavioral symptoms (such as apathy, dis-inhibition, inappropriate conduct, abnormal eating patterns), while the decreased metabolism in posterior areas might reflect altered perception (delusions, hallucinations, dream-like experiences). Increased caudate, cingulate, and premotor metabolism could result from recruitment of compensatory mechanisms. Enhanced activity surrounding the primarily affected regions represents a well-known compensatory mechanism following focal brain injury, or an adaptive response to neural disorganization of diffuse brain damage [4].

In functional neuroimaging studies using SPECT [5] [6] thalamic hypo-perfusion was the most consistent finding during the symptomatic period. Other studied reported abnormalities include hypothalamus, basal ganglia, frontal, and temporal hypo-perfusion.

These findings appear concordant with the symptoms reported by patients and suggest that KLS is associated with specific and widespread organic brain abnormalities [4].

In about 75% cases, EEG demonstrates diffuse slowing of the background during the episodes. Less often, EEG may show low frequency, high amplitude delta or theta waves predominantly in temporal or frontotemporal regions, occurring in isolation or in sequences [7].

Rarely, isolated spikes or sharp waves may be seen [8].

In our case EEG shows focal discharge as sharp and spike waves in the frontal and temporal lobes at both hemispheres with secondary generalization, while in between the episode the secondary generalization is absent (Figure 3, Figure 4).

We suppose the abnormalities found in the EEG were due to possible role of hypothalamic, thalamic and frontotemporal dysfunction [9] [10].

We try to found explanation for the presence of mega cistern magna in our patient and we know that the cerebellum plays an important role in coordination and motor functions [11]. Besides its involvement in motor and vestibulo-ocular regulation, it is considered to be involved in modulation of mood [12].

In this case, mega cisterna magna might contribute to the activation of cerebellum.

Cerebellar structures, especially the vermis, are considered to be associated with the pathophysiology of psychiatric disorders such as schizophrenia [13]. Cerebellar vermal neurons may play a role in the modulation of mood [14]. Also, vermal lesions are associated with behavioural and affective changes [15]. Our patient became symptoms free after receiving Na Valoprate; Sodium Valproic Acid which is one of the (AED) Anti-Epileptic Drugs, old generation (Trad. Name as Depakin, Valpromed, Valpron..., tab. 200 mg) BD for 2 weeks then TDS. 10 - 15 mg/kg/day. The dosage should be increased by 5 - 10 mg/kg/week to achieve optimal clinical response.

### 4. Conclusion

In this case report, mega cisterna magna and Klein-Levin syndrome may be found coincidentally together or any cerebellar dysfunction due to mega cisterna magna may cause or contribute to the appearance of affective symptoms. Also our patient became symptom-free after receiving Na Valoprate.

### References

- [1] Ramdurg, S. (2010) Kleine-Levin Syndrome: Etiology, Diagnosis, and Treatment. *Annals of Indian Academy of Neurology*, **13**, 241-246. <http://dx.doi.org/10.4103/0972-2327.74185>
- [2] Arnulf, I., Lin, L., Gadoth, N., File, J., Lecendreux, M., Franco, P., Zeitzer, J., Lo, B., Faraco, J.H. and Mignot, E. (2008) Kleine-Levin Syndrome: A Systematic Study of 108 Patients. *Annals of Neurology*, **63**, 482-493. <http://dx.doi.org/10.1002/ana.21333>
- [3] Turan, T., Beşirli, A., Asdemir, A., Özsoy, S. and Eşel, E. (2010) Manic Episode Associated with Mega Cisterna Magna. *Psychiatry Investigation*, **7**, 305-307. <http://dx.doi.org/10.4306/pi.2010.7.4.305>
- [4] Haba-Rubio, J., Prior, J.O., Guedj, E., et al. (2012) Kleine-Levin Syndrome: Functional Imaging Correlates of Hyperomnia and Behavioral Symptoms. *Neurology*, **79**, 1927. <http://dx.doi.org/10.1212/WNL.0b013e318271f85a>
- [5] Landtblom, A.M., Dige, N., Schwerdt, K., Safstrom, P. and Granerus, G. (2002) A Case of Kleine-Levin Syndrome Examined with SPECT and Neuropsychological Testing. *Acta Neurologica Scandinavica*, **105**, 318-321. <http://dx.doi.org/10.1034/j.1600-0404.2002.1c162.x>

- [6] Huang, Y.S., Guilleminault, C., Kao, P.F. and Liu, F.Y. (2005) SPECT Findings in the Kleine-Levin Syndrome. *Sleep*, **28**, 955-960.
- [7] Abhijit, D., Meena, G., Yogesh, P., Yogesh, P. and Amit, B. (2014) Kleine-Levin Syndrome—A Syndrome of Periodic HyperSomnia: A Case Report. *Indian Journal of Applied Research*, **4**.
- [8] Elian, M. (1968) Periodic Hypersomnia. *Electroencephalography and Clinical Neurophysiology*, **24**, 192-193.
- [9] Huang, Y.S., Guilleminault, C., Kao, P.F. and Liu, F.Y. (2005) SPECT Findings in the Kleine-Levine Syndrome. *Sleep*, **28**, 955-960.
- [10] Hong, S.B., Joo, E.Y., Tae, W.S., Lee, J., Han, S.J. and Lee, H.W. (2006) Episodic Diencephalic Hypoperfusion in Kleine-Levin Syndrome. *Sleep*, **29**, 1091-1093.
- [11] Schmahmann, J.D. (1991) An Emerging Concept. The Cerebellar Contribution to Higher Function. *Archives of Neurology*, **48**, 1178-1187. <http://dx.doi.org/10.1001/archneur.1991.00530230086029>
- [12] Brambilla, P., Harenski, K., Nicoletti, M., Mallinger, A.G., Frank, E., Kupfer, D.J., et al. (2001) MRI Study of Posterior Fossa Structures and Brain Ventricles in Bipolar Patients. *Journal of Psychiatric Research*, **35**, 313-322. [http://dx.doi.org/10.1016/S0022-3956\(01\)00036-X](http://dx.doi.org/10.1016/S0022-3956(01)00036-X)
- [13] Ichimiya, T., Okubo, Y., Suhara, T. and Sudo, Y. (2001) Reduced Volume of the Cerebellar Vermis in Neuroleptic-Naive Schizophrenia. *Biological Psychiatry*, **49**, 20-27. [http://dx.doi.org/10.1016/S0006-3223\(00\)01081-7](http://dx.doi.org/10.1016/S0006-3223(00)01081-7)
- [14] Mills, N.P., Delbello, M.P., Adler, C.M. and Strakowski, S.M. (2005) MRI Analysis of Cerebellar Vermal Abnormalities in Bipolar Disorder. *The American Journal of Psychiatry*, **162**, 1530-1532. <http://dx.doi.org/10.1176/appi.ajp.162.8.1530>
- [15] Schoch, B., Kaiser, O., Groetschel, H., Dimitrova, A., Hein-Kropp, C., et al. (2005) Behavioral and Affective Changes in Children and Adolescents with Chronic Cerebellar Lesions. *Neuroscience Letters*, **381**, 102-107. <http://dx.doi.org/10.1016/j.neulet.2005.02.011>