



The Calcifying Epithelial Odontogenic Tumor (Pindborg Tumor): A Case Report

Mehmet Cemal Akay*, Ayhan Tetik, Mert Zeytinoğlu

Ege University, Faculty of Dentistry, Department of Oral and Maxillofacial Surgery, Bornova, İzmir, Turkey
Email: *cemalakay@yahoo.com

Received 3 August 2014; revised 26 September 2014; accepted 27 October 2014

Copyright © 2014 by authors and OALib.

This work is licensed under the Creative Commons Attribution International License (CC BY).

<http://creativecommons.org/licenses/by/4.0/>



Open Access

Abstract

Calcifying Epithelial Odontogenic Tumor (CEOT) is a rare benign odontogenic tumor that was first described by Pindborg in 1955. It accounts for less than 1% of all odontogenic neoplasms. This lesion is a locally aggressive benign odontogenic neoplasm arising from epithelial tissue. The radiographic appearance is characterized by uni- or multilocular radiolucent areas with radiopaque masses of varying sizes; there is a frequent association with an unerupted tooth. Most CEOT are intraosseous lesions which are most common in the mandible, with most of these occurring in the molar and premolar regions of the mandible. Malignant transformation and metastasis is rare. The aim of the current report was to describe the clinical radiological and histopathological findings in a case of mandibular CEOT.

Keywords

Calcifying Epithelial Odontogenic Tumor, Mandible, Impacted Tooth

Subject Areas: Dentistry, Oncology

1. Introduction

The calcifying epithelial odontogenic tumour (CEOT) is a rare tumor. It was first described as a separate pathologic entity by a Dutch pathologist Jens Jorgen Pindborg in 1955 [1] [2]. The term “Pindborg’s tumour” was first used by Shafer and colleagues in 1963 [3]. CEOT accounts for 0.4% to 3% of all odontogenic tumors. This tumor more frequently affects adults, with a peak incidence in the fourth and fifth decades of life and equal sex distribution [4]. Radiographically, CEOT is characterized by a uni- or multilocular lesion that often shows a mixed radiolucent-radiopaque pattern [5]. It usually involves the premolar-molar area of mandible [6]. Treatment consists in the surgical removal of the lesion, with recurrence in 14% of cases [7]. The prognosis is considered good [5]. The present report showed a case of CEOT in a 26-year-old male patient manifested as a

*Corresponding author.

hard nodule on the right mandibular premolar region.

2. Case Report

A 26-year-old man was referred to our clinic in May 2012. He presented with facial asymmetry and paresthesia on the right side of the posterior mandible. Intraoral examination of the patient showed a 2.5×3 cm in size expansion on the buccal aspect of right molar region of the mandible. The swelling was tender and increased progressively over a period of 1 year. Panoramic radiograph revealed a mixed radiolucent-radiopaque lesion, which was multilocular with coarse trabeculae and scattered foci of calcification extending from right lower first premolar to first molar region with a radio opaque mass representing embedded second premolar (**Figure 1**: Pre-operative radiographic image shows CEOT with an impacted second premolar). The provisional clinical diagnosis of ameloblastoma, odontogenic keratocyst and malignant CEOT was made. Under local anesthesia, extraction of impacted second premolar and enucleation of the lesion were performed and the specimen was submitted for histopathology (**Figure 2** and **Figure 3** shows surgical enucleation of the tooth and pathologic mass).

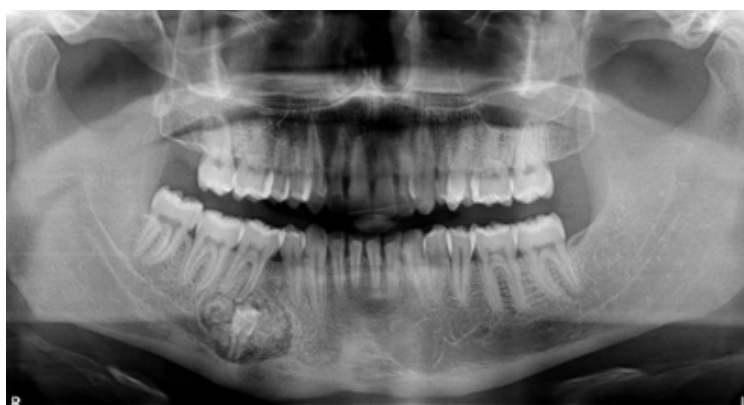

Figure 1. Radiographic image of CEOT at the time of treatment.

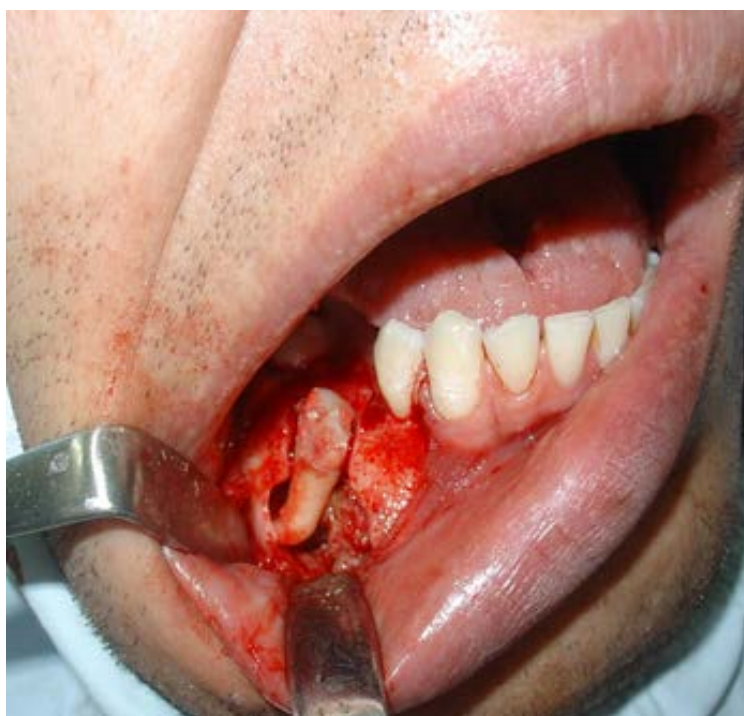

Figure 2. Surgical extraction of the tooth.

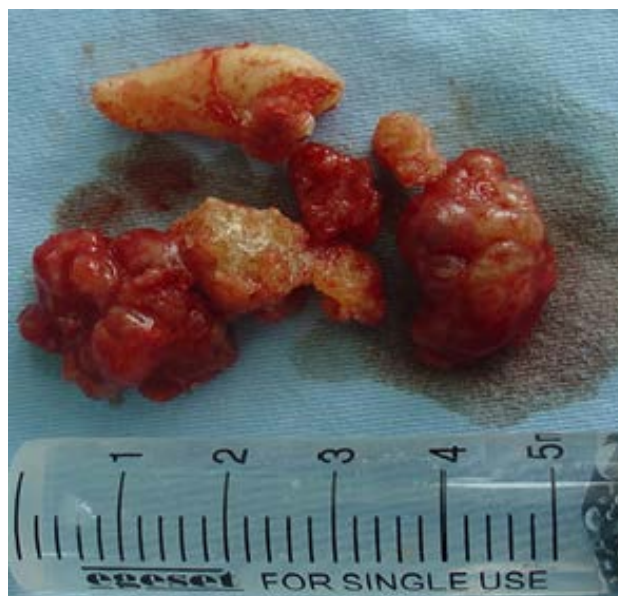

Figure 3. Surgical enucleation of the lesion.

After enucleation of the tumor, iodoform gauze applied to the cavity. The cavity was irrigated and the gauze was changed every 4 days. An impression of the cavity was taken and an acrylic obturator was fabricated. Then it inserted in after 14 days of the surgery (**Figure 4**: Clinical appearance of the surgical obturator). The obturator was reduced in size at every monthly recall. Histopathological examination showed strands of polyhedral epithelial cells with pleomorphic nuclei and calcification in the form of Liesegang rings (**Figure 5**: Photomicrograph showing liesegang rings (white arrows) and strands of polhedral epithelial cells with pleomorphic nuclei [H & E \times 100]). The diagnosis confirmed calcifying epithelial odontogenic tumor. Numerous spherical calcified masses were seen in a background of cellular degeneration with scant fibrous stroma. At the eight-month post-operative visit, the patient had no complaints expect parasthesia. After three years of the operation, bone healing in the affected area was progressing well (**Figure 6** and **Figure 7**: Postoperative clinical and radiological appearance (36 months after the operation shows bone healing with no recurrence).

3. Discussion

Since the publication of Pindborg *et al.*'s article [8], there have been numerous articles on CEOT cases. Today, approximately 200 cases of CEOT have been reported in the literature. It's a slow growing neoplasm that occurs as intraosseous (96%) and extraosseous (4%) variants [9] [10]. Its histogenesis is uncertain. It usually involves the premolar-molar area of the mandible, there is no gender predilection and the peak incidence is found between the fourth and fifth decades of life [4]. In the 113 cases reviewed by Franklin and Pindborg, patients age ranged from 8 to 92 years with a mean age of 40 years [9]. Mandibular cases are more frequently reported than their maxillary counterparts, and about 80% are located in the premolar and molar regions [11]. A frequent radiographic finding in these tumors has been the presence of calcifying structures of varying sizes inside the lesions. Besides this, the cases reported in the literature have mostly been painless, of a slow evolution, and in an intraosseous area [5] [12]. Supporting the literature, the present study reports the case of Pindborg tumor, located premolar region of the mandible and showing the presence of calcifying structures in the radiographic exam. However, some of the characteristics found in this case are uncommon when compared with the literature, such as the fact that the tumor has affected a patient below the age of 30 and showed rapid growing with pain.

Etiology of this lesion is not clear. Majority of the investigators are of the opinion that, the tumour cells originate from the striatum intermedium of the normal dental lamina [13], an idea based on the morphologic similarity of the tumour cell to the normal cells of stratum intermedium and a finding of high activity of alkaline phosphatase and adenosine triphosphate at both sites [9]. There is a marked predilection for the molar-premolar area of mandible with about 50% cases associated with unerupted or embedded teeth [13]. The clustering of radio-opaque flecks at the coronal area of impacted teeth is a feature originally described by Pindborg and is con-

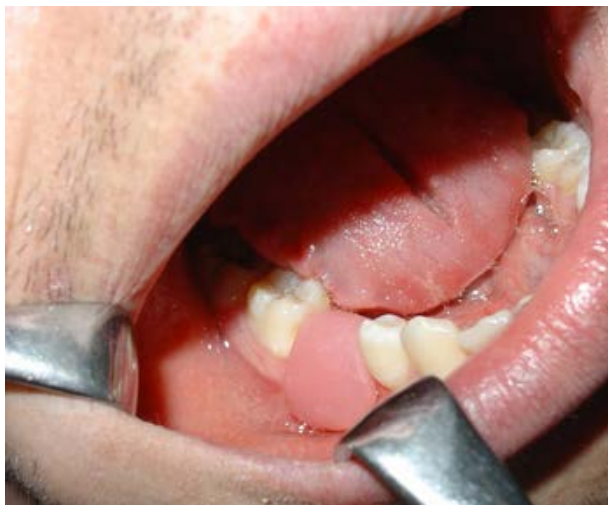

Figure 4. Clinical appearance of the surgical obturator.

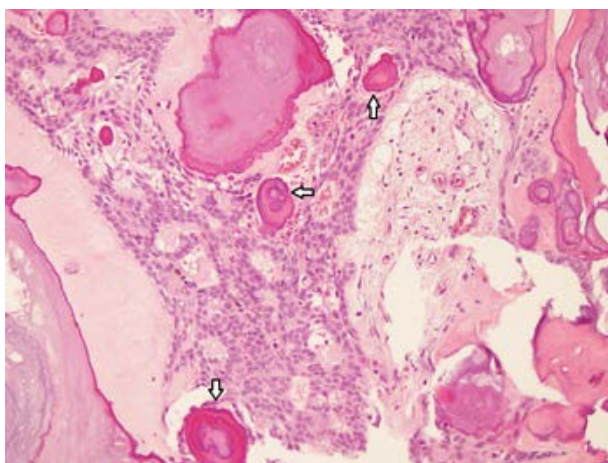


Figure 5. Photomicrograph showing liesegang rings (white arrows) and strands of polihedral epithelial cells with pleomorphic nuclei [H & E \times 100].

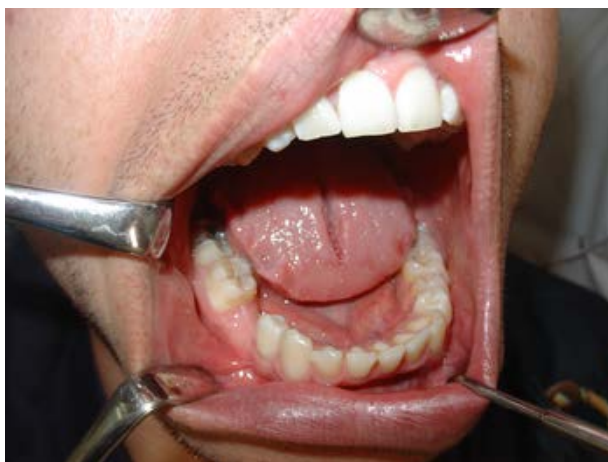

Figure 6. Clinical appearance of postoperative healing (36 months after the operation).

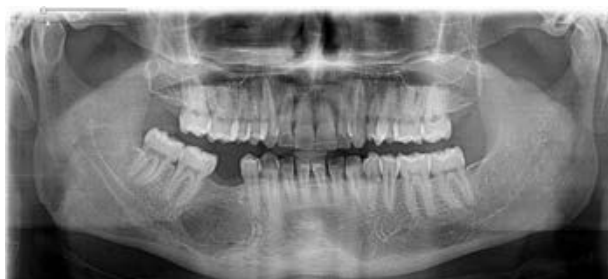

Figure 7. Postoperative radiologic appearance (36 months after the operation).

sidered by others to be typical of a CEOT [14]. Similarly, our case showed more calcifications at the crown of the unerupted second premolar. CEOT occurred premolar area of mandible with unerupted teeth in our case.

Radiographically, according to a study by Kaplan *et al.*, 58% of CEOTs are unilocular, 27% multilocular, and 15% nonloculated [14]. The radiographic findings in our case showed a loculated/trabeculated radiolucent thin membrane around the impacted second premolar.

The diagnosis of CEOT is based on histological examination, revealing polyhedral neoplastic cells which have abundant eosinophilic, finely granular cytoplasm with nuclear pleomorphism and prominent nucleoli. Most of the cells are arranged in broad ramifying and anastomosing sheet like masses with little intervening stroma; similar morphologic features were visualized in our case. An extracellular eosinophilic homogenous material staining like amyloid is characteristic of this tumour with concentric calcified deposits, resembling psammoma bodies called “Liesegang rings [15]-[17]. This case also depicted calcific foci in abundance and also fused amorphous calcareous aggregates. Some of these tumors may be epithelium-predominant with minimal amyloid whereas others may be amyloid-predominant with small islands of epithelium. Still others may have abundant clear cells [18]. A mixed lesion along with adenomatoid odontogenic tumor has also been reported [19]. The given section in our case revealed islands and strands of polyhedral epithelial cells in a fibrous stroma. The fibrous stroma revealed the presence of numerous calcifications, suggestive of lesion progression and a lesion of long standing. Congo red testing for amyloid was negative in the present case as the amyloid had become calcified.

The differential diagnosis includes adenomatoid odontogenic tumor, calcifying odontogenic cyst, dentigerous cyst, ameloblastic fibro-odontoma and odontoma. It is an infiltrative neoplasm and causes destruction with local expansion. Definitive resection of the entire mass with tumor-free surgical margins (en bloc resection) is the preferred treatment as tumor will recur if not completely removed. Long-term follow ups are recommended [15]. Local recurrence rates of 10% - 15% have been reported [20]. Treatment of CEOT involves enucleation of smaller lesions and resection of large ones [21]. Surgical decision-making often depends on case parameters such as the anatomic location of the tumor, the size and duration, histopathologic findings, patient age, health status, and consideration of reconstruction methods following surgical procedure [22]. The lesion in the presented case was performed, including a marginal portion of apparently healthy bone, and enucleated with impacted second premolar. The presented patient was regularly reviewed for 3 years with no clinical or radiological signs of recurrence and remains symptom free. However, we will periodically examine over the next five years to verify the possible recurrence of the lesion.

References

- [1] Baunsgaard, P., Løntoft, E. and Sorensen, M. (1983) Calcifying Epithelial Odontogenic Tumor (Pindborg Tumor): An Unusual Case. *Laryngoscope*, **93**, 635-638.
- [2] Pindborg, J.J. (1958) A Calcifying Epithelial Odontogenic Tumor. *Cancer*, **11**, 838-843.
[http://dx.doi.org/10.1002/1097-0142\(195807/08\)11:4<838::AID-CNCR2820110423>3.0.CO;2-5](http://dx.doi.org/10.1002/1097-0142(195807/08)11:4<838::AID-CNCR2820110423>3.0.CO;2-5)
- [3] Shafer, W.G., Hine, M.K. and Levy, B.M. (1963) A Textbook of Oral Pathology, 2nd Edition, W. B. Saunders Company, Philadelphia, 217.
- [4] Cicconetti, A., Tallarico, M., Bartoli, A., Ripari, A. and Maggiani, F. (2004) Calcifying Epithelial Odontogenic (Pindborg) Tumor. A Clinical Case. *Minerva Stomatol*, **53**, 379-387.
- [5] Sahni, P., Nayak, M.T., Singhvi, A. and Sharma, J. (2012) Clear Cell Calcifying Epithelial Odontogenic (Pindborg)

- Tumor Involving the Maxillary Sinus: A Case Report and Review of Literature. *Journal of Oral and Maxillofacial Pathology*, **16**, 454-459. <http://dx.doi.org/10.4103/0973-029X.102520>
- [6] Sedghizadeh, P.P., Wong, D., Shuler, C.F., Linz, V., Kalmar, J.R. and Allen, C.M. (2007) Multifocal Calcifying Epithelial Odontogenic Tumor. *Oral Surgery, Oral Medicine, Oral Pathology, Oral Radiology and Endodontics*, **104**, 30-34. <http://dx.doi.org/10.4103/0973-029X.102520>
- [7] Whitt, J., Barker, B., Rokos, J. and Dunlap, C. (2012) Calcifying Epithelial Odontogenic Tumor: Report of a Series of Ten Cases. *Oral Surgery, Oral Medicine, Oral Pathology, Oral Radiology*, **114**, 68-69.
- [8] Pindborg, J.J., Simonsen, E.K. and Hansen, P.B. (1966) A Case of Calcifying Epithelial Odontogenic Tumor. *Tandlaegebladet*, **70**, 822-830.
- [9] Franklin, C.D. and Pindborg, J.J. (1976) The Calcifying Epithelial Odontogenic Tumor. A Review and Analysis of 113 cases. *Oral Surgery, Oral Medicine, Oral Pathology*, **42**, 753-765. [http://dx.doi.org/10.1016/0030-4220\(76\)90098-0](http://dx.doi.org/10.1016/0030-4220(76)90098-0)
- [10] Reichart, P.A., Philipsen, H.P., Eds. (2004) *Odontogenic Tumors and Allied Lesions* Quintessence Publishing, London, 43-59.
- [11] Philipsen, H.P. and Reichart, P.A. (2000) Calcifying Epithelial Odontogenic Tumour: Biological Profile Based on 181 Cases from the Literature. *Oral Oncology*, **36**, 17-26. [http://dx.doi.org/10.1016/S1368-8375\(99\)00061-5](http://dx.doi.org/10.1016/S1368-8375(99)00061-5)
- [12] Lin, J., Bianchi, M., Popnikolov, N.K. and Abaza, N.A. (2013) Calcifying Epithelial Odontogenic Tumor: Case Report with Immunohistochemical and Ultrastructural Study and Review of the Literature. *Journal of Oral and Maxillofacial Surgery*, **71**, 278-289. <http://dx.doi.org/10.1016/j.joms.2012.06.171>
- [13] Goldenberg, D., Sciubba, J., Koch, W. and Tufano, R.P. (2004) Malignant Odontogenic Tumors: A 22-Year Experience. *Laryngoscope*, **114**, 1770-1774. <http://dx.doi.org/10.1097/00005537-200410000-00018>
- [14] Kaplan, I., Buchner, A., Calderon, S. and Kaffe, I. (2001) Radiological and Clinical Features of Calcifying Epithelial Odontogenic Tumour. *Dentomaxillofacial Radiology*, **30**, 22-28. <http://dx.doi.org/10.1038/sj.dmf.4600566>
- [15] Akhtar, K., Khan, N., Zaheer, S., Sherwani, R. and Hasan, A. (2010) Pindborg Tumor in an Adolescent. *Oman Medical Journal*, **25**, 47-48.
- [16] Krolls, S.O. and Pindborg, J.J. (1974) Calcifying Epithelial Odontogenic Tumor. A Survey of 23 Cases and Discussion of Histomorphologic Variations. *Archives of Pathology*, **98**, 206-210.
- [17] Pindborg, J.J., Vedtofte, P., Reibel, J. and Praetorius, F. (1991) The Calcifying Epithelial Odontogenic Tumor. A Review of Recent Literature and Report of a Case. *Acta Pathologica, Microbiologica et Immunologica Scandinavica*, **23**, 152-157.
- [18] Habibi, A., Saghravanian, N., Zare, R. and Jafarzadeh, H. (2009) Clear Cell Variant of Extrasosseous Calcifying Epithelial Odontogenic Tumor: A Case Report. *Journal of Oral Science*, **51**, 485-488. <http://dx.doi.org/10.2334/josnusd.51.485>
- [19] Damm, D.D., White, D.K., Drummond, J.F., Poindexter, J.B. and Henry, B.B. (1983) Combined Epithelial Odontogenic Tumor: Adenomatoid Odontogenic Tumor and Calcifying Epithelial Odontogenic Tumor. *Oral Surgery, Oral Medicine, Oral Pathology*, **55**, 487-496. [http://dx.doi.org/10.1016/0030-4220\(83\)90235-9](http://dx.doi.org/10.1016/0030-4220(83)90235-9)
- [20] Tabangay-Lim, I.M., Mallari, R.N., Lacsamana, N.M., Paz, D.D.Z., Villafuerte, A.R.R. and Quilendrin, P.R.M. (2005) Recurrent Calcifying Epithelial Odontogenic Tumor (Pindborg Tumor): A Case Study. *Oral Oncology Extra*, **41**, 259-266. <http://dx.doi.org/10.1016/j.ooe.2005.04.006>
- [21] Shanmuga, P.S., Ravikumar, A., Krishnarathnam, K. and Rajendiran, S. (2009) Intraosseous Calcifying Epithelial Odontogenic Tumor in a Case with Multiple Myeloma. *Journal of Oral and Maxillofacial Pathology*, **13**, 10-13. <http://dx.doi.org/10.4103/0973-029X.48742>
- [22] Peterson, L.F., Ellis, E., Hupp, J.R. and Tucker, M.R., Eds. (1998) *Odontogenic Cysts and Tumors*. In: *Contemporary Oral and Maxillofacial Surgery*, 3rd Edition, Mosby-Year Book, St. Louis, 545-552.