

# Role of Multidetector CT in Staging of Gastric Carcinoma

Hisham Mostafa Kamel Emam<sup>1</sup>, Ehab Mansour Mohammed Moussa<sup>1</sup>,  
Mohammed Abouelmaged<sup>2</sup>, Maha Ragab Ismail Ibrahim<sup>1\*</sup>

<sup>1</sup>Radiodiagnosis Department, Faculty of Medicine, Assiut University, Assiut, Egypt

<sup>2</sup>Surgical Oncology Department, South Egypt Cancer Institute, Assiut, Egypt

Email: \*Maharagab45@gmail.com

**How to cite this paper:** Emam, H.M.K., Moussa, E.M.M., Abouelmaged, M. and Ibrahim, M.R.I. (2019) Role of Multidetector CT in Staging of Gastric Carcinoma. *Journal of Cancer Therapy*, 10, 565-579. <https://doi.org/10.4236/jct.2019.107046>

**Received:** May 22, 2019

**Accepted:** July 19, 2019

**Published:** July 22, 2019

Copyright © 2019 by author(s) and Scientific Research Publishing Inc.

This work is licensed under the Creative Commons Attribution International License (CC BY 4.0).

<http://creativecommons.org/licenses/by/4.0/>



Open Access

## Abstract

**Background:** Radiology plays an essential role in the diagnosis, staging and surveillance of oncology patients. CT is the most sensitive imaging modality in the workup of these patients. **Aim of the Study:** The aim of this work is to detect the role of MDCT (multidetector computed tomography) in the preoperative investigation of gastric adenocarcinoma patients according to TNM staging. **Patients and Methods:** This is a prospective study enrolling 20 patients who had histologically proven adenocarcinoma based upon an upper gastrointestinal endoscopic biopsy for MDCT staging of gastric carcinoma during the period from June 2016 to June 2017. The MSCT data were correlated and compared with the histopathological results. The study was conducted in the Radiology Department of Assiut University Hospital using 64-MDCT (Toshiba Aquilion). **Results:** According to our study results, the sensitivity of determining T1 stage on CT scan can't be detected as there was only 1 case pathologically proved T1 and overstaged as T2 by MSCT; however, accuracy and specificity are quite high, which was 95% and 100% respectively. For T2 stage tumors (25.0% of cases), accuracy is 95%, sensitivity—100%, and specificity—93.7%. According to our results the accuracy and sensitivity of T3 staging are 75% and 100%, while those of T4 stage were 75% and 44.4% respectively. Tumor was correctly staged in 14 of 20 patients (the valid T staging rate was 70.0%). Tumor was under-staged in 5 of 20 patients (25.0%) (staged as T3, but pathologically proven to be T4a). As regards N staging accuracy found results for N0 (62.5%), N2 (87.5%) and N3 (75%), while N1 accuracy recorded 37.5%. As regards the nodal staging sensitivity which had a range from (0% for N4) to (66% for N2) this wide range of sensitivity demonstrates the problem of CT in nodal staging. As regards sensitivity of M0, accuracy was 100% and 85% respectively. While that of M1 was (62.5%) and (85%) respectively. **Conclusion:** MSCT can be the first choice

for the preoperative evaluation of patients with gastric carcinoma. It presents excellent accuracy in the staging of tumor invasion depth (T) and in the staging of metastatic neoplastic disease (M). Despite the good accuracy in the staging of patients without lymph node disease (N0), the method presents limitations in the staging of lymph node involvement.

## Keywords

Multidetector CT, Gastric Carcinoma

---

## 1. Introduction

Gastric cancer is the 4th most common cancer and the 2nd leading cause of cancer-related deaths worldwide after lung cancer. Despite a steady decline in the incidence rate over the last few decades, the absolute incidence has risen due to the aging of the worldwide population. The incidence of gastric cancer is particularly common in eastern Asia [1].

Chronic inflammation (especially chronic *Helicobacter Pylori* infection), exposure to diverse carcinogens, and genetic susceptibility are among factors associated with an increased risk of gastric cancer.

Adenocarcinoma is the most frequent histological subtype of gastric cancer, representing about 95% of cases, and the other subtypes comprise lymphomas, tumors of stromal origin and other more rare subtypes as neuroendocrine tumors.

Patients' survival is related to the tumor invasion depth and lymph node involvement. Five-year survival for patients with advanced tumors ranges between 7% and 27%, while five-year survival for patients with early-stage tumors achieves 85% - 100% [2].

Some early-stage tumors (T1) may be endoscopically (mucosectomy) or laparoscopically resected. On the other hand, some protocols indicate neoadjuvant chemotherapy and/or radiotherapy in cases of advanced gastric cancer [3].

Thus, the definition of an appropriate therapy depends on an accurate preoperative staging and may increase the cure rates and improve the patients' quality of life.

The TNM (tumor-node metastasis) staging system is one of the most commonly used staging systems, and is currently at its seventh edition [4] [5].

Preoperative staging is frequently performed with abdominal ultrasonography, computed tomography and endoscopic ultrasonography [6]. Until recently, endoscopic radiography was regarded as the best method of preoperative staging to determine the degree of tumor invasion (category T) [7].

The most recent international consensus corroborated the necessity of preoperative TNM staging and pointed out multidetector-row computed tomography as the best staging method [8] [9], which has demonstrated similar or superior accuracy as compared with endoscopic ultrasonography for T-staging and a

clear advantage in relation to other methods for N- and M-staging.

Multidetector-row computed tomography, particularly those apparatuses with 16 or more channels, offers rapid acquisition of submillimetric sections, isotropic multiplanar reconstruction and postprocessing options such as virtual endoscopy, which increases the method accuracy in the local staging [10]. Additionally, computed tomography can evaluate lymph nodes and other organs [11].

Some studies have reported that MDCT with MPR images increases the accuracy of T staging in patients with gastric cancer. Thus, MDCT with MPR images is used as a routine protocol for gastric cancer staging.

## 2. Aim of the Work

The aim of this work is to evaluate the role of multidetector computed tomography in the preoperative investigation of tumor invasion depth, lymph node and metastatic involvement according to the TNM classification, in patients with gastric adenocarcinoma.

## 3. Patients and Methods

The study was conducted in the Radiology Department of Assuit University Hospital using 64-MDCT (Toshiba Aquilion) during a 12-month period from June 2016 to June 2017.

### **Inclusion criteria:**

Patients who had histologically proven adenocarcinoma of the stomach based upon an upper gastrointestinal endoscopic biopsy.

### **Exclusion criteria:**

Patients who have an allergy to the IV contrast media and patients with renal impairment may both are excluded from the study.

Patients were recruited from the outpatient clinic and inpatient ward of the surgical oncology department at South Egypt Center Institute and surgery department at Assiut University Hospital and were included in the image analysis of this prospective study (11 women, and 9 men; mean age, 51 years; age range, 25 - 71 years).

Among the 20 patients, the majority of them presented with persistent vomiting and weight loss (9 patients), followed by epigastric pain (5 patients), then gastric outlet obstruction (5patients), and hematemesis (1 patient)

### **The routine workup of these cases includes:**

- 1) Full history taking.
- 2) Upper GIT endoscopy and biopsy of suspicious lesion(s).
- 3) Histopathological evaluation of the biopsy.
- 4) Metastatic workup including contrast enhanced MDCT examination of the abdomen and pelvis for accurate staging.
- 5) Therapeutic plane either by surgical excision, chemotherapy or neoadjuvant chemotherapy before surgical excision.
- 6) Postoperative histopathological evaluation and staging of the excised tu-

mour tissue and/or lymph nodes and comparing them with MSCT results.

**The MSCT examination:**

- Contrast enhanced MDCT examination of the abdomen and pelvis with 2D MPR for staging of the gastric carcinoma.
- In our 20 patients using water or gas as oral contrast. Water was used for gastric distention for 18 patients (10 women and 8 men). In 2 patients, both gas and water was used for gastric distention (1 man and 1 woman).
- Imaging analysis and radiological staging were correlated with surgical findings and postoperative pathological staging of the resected tumour in all patients.

**Ethical considerations:**

The study was approved by the institutional Ethical Review Board. The nature of the study was adequately explained to the patients, and an informed consent was obtained from all the patients before participating in this study.

**Imaging Technique:**

**1) Scanning protocol:**

CT was performed using 64-MDCT scanner (Toshiba Aquilion) [with detector configuration of  $64 \times 0.5$  mm, rotation time of 0.35 second, 120 kV, and 93 mAs] and 64-MDCT scanner (GE) [with detector configuration of  $64 \times 0.75$  mm, pitch of 1.25, rotation time of 0.5 second, 120 kVp, and 93 mA].

**2) Patient preparation:**

All patients underwent CT examination after overnight fasting to empty the stomach. All patients received an intramuscular injection of 20 mg of hyoscine butylbromide (Buscopan) 5 minutes before the examination to decrease bowel peristalsis and to facilitate hypotonia.

**3) Oral contrast:**

200 ml mannitol (10% concentration) was added to 1000 to 1500 mL water and given at a steady rate (approximately 150 ml every 5 minutes) over a period of 45 minutes before the scan. The patient is then transferred to the scanner table, drinking the last cup on the table. The abdomen was scanned in the supine position. In 2 patients gas also was used to distend the stomach. Effervescent granules (Fawar fruit, effervescent salt, 10 g) with a minimum amount of water (<10 mL) was orally administered to obtain gastric distention with the patient already on the CT table just before scanning.

**4) IV contrast:**

Non-ionic contrast material (Omnipaque 350, 100 mL) was administered intravenously with a power injector at rate of 3 mL/sec. For acquisition of the arterial phase, CT scanning was started 30 seconds after intravenous injection of the contrast medium. The second sequence was started after 70 seconds for the portal phase.

**Imaging Analysis:**

Imaging analysis consisted primarily of a review of the axial scans. Then MPR images were evaluated to confirm the abnormality. The depth of tumor invasion

was evaluated on MPR images, with projections oriented vertical to the tumor to avoid partial-volume effects. All lymph nodes were simultaneously evaluated with transverse, coronal, and sagittal MPR images.

#### Statistical Analysis:

Data was summarized using mean and standard deviation (S.D.) for quantitative variables and number and percent for qualitative variables.

## 4. Results

Our study includes 55% females, and 45% males, with mean age and standard deviation of 51.30 and 12.22 respectively. The most frequent clinical presentation was persistent vomiting and weight loss, encountered in 9 patients (45%) followed by dyspepsia and epigastric pain in 5 patients (25%) gastric outlet obstruction is detected in 5 patients while one patient only was presented with hematemesis and anemia (**Table 1**).

Using endoscopic findings as a reference, MDCT could accurately localize the tumor in all patients who underwent surgery (the valid detection rate was 100%). Both site and shape of the gastric lesion are described in **Table 2**.

According to our study results (**Table 3**), the sensitivity of determining T1 stage on CT scan can't be detected as there was only 1 case pathologically proved T1 and overstaged as T2 by MSCT, however, accuracy and specificity are quite high, they were 95% and 100% respectively For T2 stage tumors (25.0% of cases), accuracy is 95%, sensitivity 100%, and specificity 93.7%. The accuracy and sensitivity of T3 staging were 75% and 100%, while that of T4 stage were 75% and 44.4% respectively. So as shown in (**Table 4**) the correct Tstaging rate reach 70%, the under staging rate 25%, while the over staging rate is 5.0%. As regards N staging (**Table 5** & **Table 6**) we found that the sensitivity of MSCT was 33.33% in N0 staging, 66% in N1, and 0% in N2 staging (as no cases staged as N2); and 0% also in N3 (4 patients staged pathologically as N3, 3 of them staged as N1 and 1 as N2). As regards M staging **Table 7** shows that 8 of 20 patients (40.0%) had distant metastasis.

From the 8 patients with distant metastasis, MDCT detected 5 of them as follow (hepatic metastasis in 1 patient, Pancreatin, colonic, and diaphragmatic metastasis

**Table 1.** Clinical and demographic data.

Variables	NO. (%)
<b>Sex</b>	
Male	9 (45.0)
Female	11 (55.0)
<b>Age (years)</b>	51.3 (25 - 71) (SD ± 12.22)
<b>Presentation</b>	
Persistent vomiting and weight loss	9 (45.0)
Dyspepsia and Epigastric pain	5 (25.0)
Gastric outlet obstruction	5 (25.0)
Hematemesis and anemia	1 (5.0)

**Table 2.** Both site and shape of the gastric lesion MSCT.

(a)			
	No.	%	
<b>Site of Gastric lesion by MDCT</b>			
Pyloric region	7	35.0	
Cardia and GEJ	6	30.0	
Lesser curvature	3	15.0	
Greater curvature	2	10.0	
Incisuraangularis	1	5.0	
Diffuse infiltration	1	5.0	

(b)			
	No.	%	
<b>Shape of lesion by MDCT</b>			
Focal mural thickening	10	50.0	
Polypoidal soft tissue thickening	5	25.0	
Gastric(intramural) mass	4	20.0	
Diffuse mural thickening	1	5.0	

**Table 3.** Comparison between T staging by MDCT and pathology.

Pathological tumor staging	Number of patients	MDCT				Sensitivity (%)	Specificity (%)	PPV (%)	NPV (%)	Accuracy (%)
		T1	T2	T3	T4					
T1	1	0	1	0	0	100		95	95	
T2	4	0	4	0	0	100	93.75	80	100	95
T3	6	0	0	6	0	100	64.29	54.55	100	75
T4	9	0	0	5	4	44.44	100	100	68.75	75
P. value		<0.001**								

**Table 4.** Results of T staging.

T staging	%
Correct T staging rate	70.0%
Under-staging rate	25.0%
Over-staging rate	5.0%

**Table 5.** Comparison between N staging by MDCT and pathology.

Pathological tumor staging	Number of patients	MDCT				Sensitivity (%)	Specificity (%)	PPV (%)	NPV (%)	Accuracy (%)
		N0	N1	N2	N3					
N0	9	3	6	0	0	33.33	100	100	53.85	62.5

**Continued**

N1	3	0	2	1	0	66.67	30.77	18.18	80.0	37.5
N2	0	0	0	0	0	-	87.5	0	100	87.5
N3	4	0	3	1	0	0	100	-	75.0	75.0
P. value	0.489									

**Table 6.** Results of N staging.

N staging	%
Correct N staging rate	31.25%
Under-staging rate	43.75%
Over-staging rate	25%

**Table 7.** Comparison between M staging by MDCT and pathology.

Pathological tumor staging	Number of patients	MDCT		Sensitivity (%)	Specificity (%)	PPV (%)	NPV (%)	Accuracy (%)
		M0	M1					
M0	12	12	0	100	62.5	80	100	85
M1	8	3	5	62.5	100	100	80	85
P. value	0.008**							

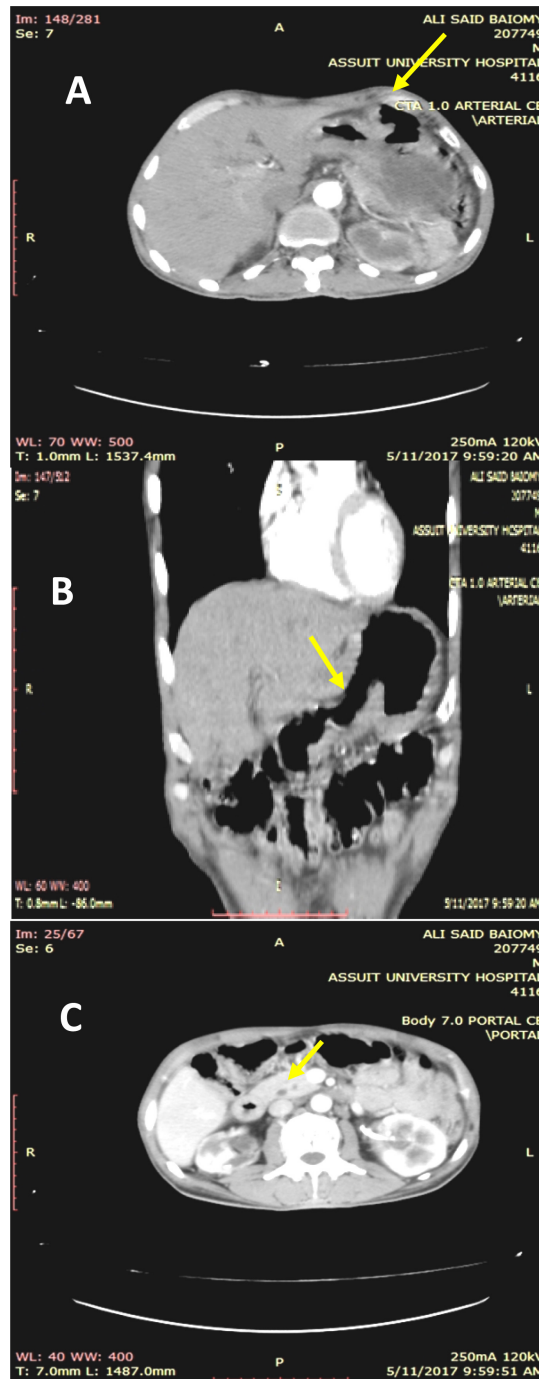
in another one. Pulmonary metastasis in 1 patient, 1 patient with direct (duodenal) spread. And last one with distal nodal metastasis.

The results regarding *M staging* sensitivity of M0 and accuracy were 100% and 85% respectively. The results regarding M1 was (62.5%) for sensitivity and (85%) for accuracy (**Table 7** and **Figures 1-3**).

## 5. Discussion

Gastric cancer is still the second most common cause of cancer-related death in the world [12]. The role of MDCT is to differentiate between benign and malignant gastric neoplasm and determine the stage and gastric spread of gastric carcinoma, which is vital in choosing between palliative or radical surgical treatment. In addition, MDCT is used to monitor response to treatment. Furthermore, it has been shown to be a very important prognostic factor in patients with gastric cancer by evaluation and estimation of tumor invasion depth after MPR [13].

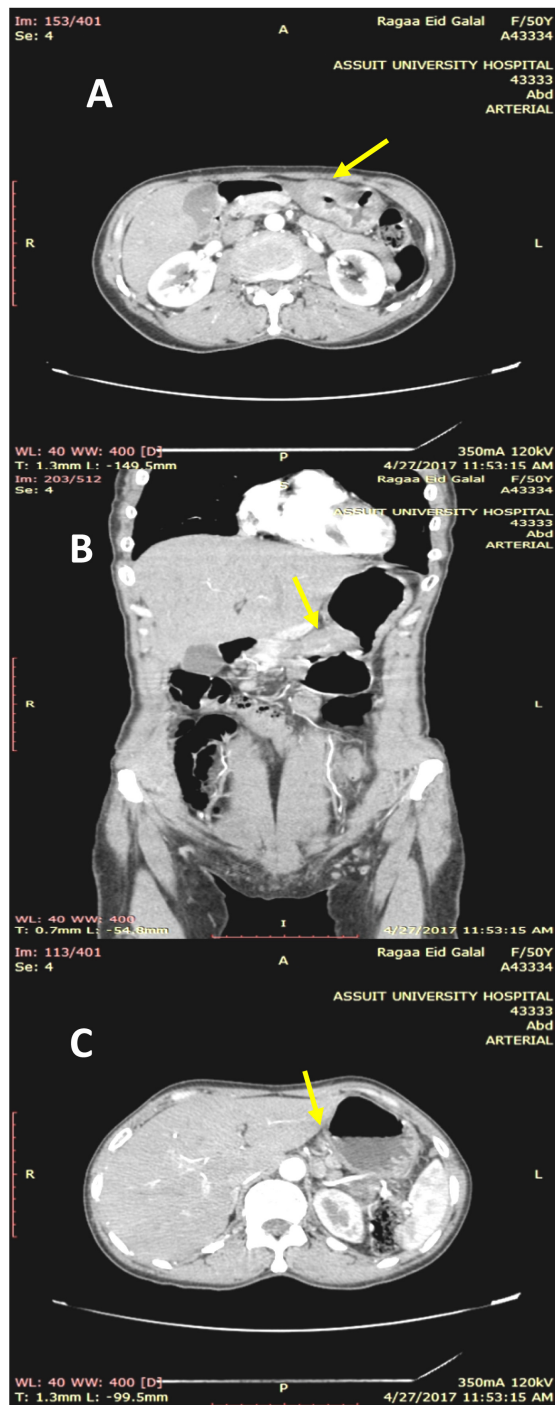
In the current study, statistical analysis, correlation, and comparison of MSCT findings with that of histopathological results were performed for the 20 patients included in our study. We found female patients were more affected (11/20) (55.0%) in comparison with male patients (9/20) (45.0%). This is not in agreement with that the findings of Macdonald *et al.* [13], who found that cancer of the stomach affects the male population more commonly compared with the



**Figure 1.** A 50-year-old male presented with persistent vomiting for 1 month. Upper GIT endoscopy: Ulcerative mass on lesser curvature grows toward the pylorus Localized mural thickening (arrow) of gastric antral region more appreciated at the anterior wall with slightly fungating mural growth encroaching upon the pyloric region with no definite complete obstruction with clear surrounding fat planes in axial (A), coronal (B) planes, paraaortic lymph nodes detected (C): staged as T3 N1 M1 while Postoperative pathological staging was T4a N3M1.

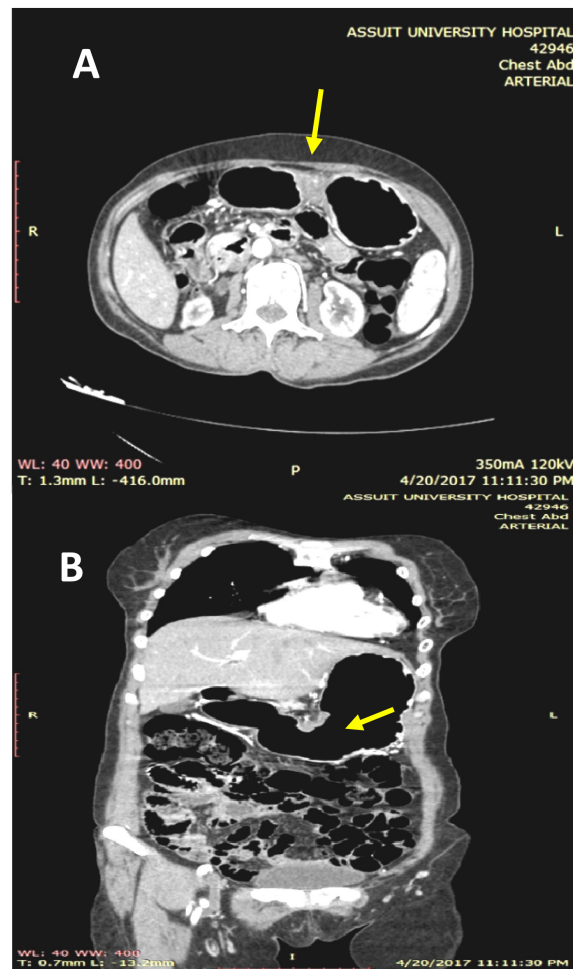
female population. They attributed this to the fact that men are more frequently exposed to the risk factors of gastric cancer.





**Figure 2.** A 50-year-old female presented with gastric outlet obstruction. MSCT revealed gastric body mass (4.5 × 1.5 cm), encroaching upon the gastric lumen and cause complete obstruction, the mass infiltrating the surrounding fat planes around it (arrow) planes in axial (A), coronal (B) planes, 3 perigastric lymph nodes detected (C), no distant metastasis, staged as: T4a N2 M0 while Post-operative pathological staging was T4a N3M0.

Most of the patients had complaints at the time of diagnosis in the study of Allum *et al.* [14], who found that dyspepsia, dysphagia, weight loss, and anemia were the most common clinical presentations. This coincides with the findings



**Figure 3.** A 60-year-old female presented with epigastric pain for 1 month. Upper GIT endoscopy: Malignant featuring ulcer on incisura angularis, MSCT revealed mural gastric wall thickening at incisura angularis (yellow arrow). in axial (A) and coronal (B) planes, with clear fat planes around the lesion, no abdominal lymphadenopathy, no distant metastasis, correctly staged as T3 N0 M0.

of our study, in which the most frequent clinical presentation was persistent vomiting and weight loss, encountered in 9 patients (45%) followed by dyspepsia and epigastric pain in 5 patients (25%), gastric outlet obstruction is detected in 5 patients while one patient only was presented with hematemesis and anemia.

MSCT findings of gastric cancer according to *Perez & Brady* [15] included focal, nodular, or an irregular thickening of the gastric wall, polypoid soft tissue density, intramural mass, and diffuse mural thickening with narrowing of the lumen. This is in agreement with the findings of our study, in which, of the 20 patients we found that; 10 patients (50%) with focal mural thickening, 5 patients (25.0%) with polypoidal soft tissue thickening, 4 patients (20.0%) with gastric intramural mass and one case (5%) with diffuse mural thickening.

In MSCT study, the assessment of gastric wall thickness is an integral part. It was found to vary between 3 and 7 mm. The mucosa of the stomach enhances with intravenous contrast and the stomach layers are best appreciated in the ar-

terial phase of contrast enhancement, when there is no positive contrast in the stomach [16]. Focal thickening of 6 mm or greater in a fully distended stomach and/or focal abnormal enhancement of the gastric wall was considered diagnostic of gastric carcinoma [17].

In our study, gastric tumor enhancement was detected in patients in the arterial phase (14/20) (5 patients with heterogenous and 9 with homogenous enhancement).

On MSCT, the depth of tumor invasion was classified as follows: T0, no evidence of alteration of the gastric wall with a normal fat plane; T1, invasion to mucosa or submucosa [17]; T2, invasion to muscularispropria [18]; T3, invasion to subserosa [19]; and T4, invasion to serosa & adjacent organs or structures [20]. In the current study, the sensitivity of MSCT in depiction and staging of gastric malignant tumors was recorded in comparison and correlation with histopathological results as gold standard.

According to our study results, the sensitivity of determining T1 stage on CT scan cannot be detected as there was only 1 case pathologically proved T1 and overstaged as T2 by MSCT, however, accuracy and specificity are quite high, they were 95% and 100% respectively. This result is in agreement with D'Elia *F et al.* [21], which reported that the low staging sensitivity of CT is caused mainly by overstaging (stage T1 tumor as stage T2). They explained that the main causes of overstaging are due to the difficulty in observing the multilayered pattern of the gastric wall especially in the areas where the gastric wall is thinner (prepyloric) and the partial volume averaging effects in the areas scanned obliquely (gastric angle).

However, the sample of T1 group is very small (only 5% of tumors were at stage T1), so the results should be interpreted with caution.

For T2 stage tumors (25.0% of cases), accuracy is 95%, sensitivity—100%, and specificity—93.7%. This is like the results of *Kristina et al.* [22], which reported that when water is used as a contrast, the results of T2 staging was, accuracy 83.8, sensitivity 100% and specificity 82.9% respectively.

As regards T3 stage, T3 stage tumors appear as thickening of the wall with uneven outer layer of gastric wall and/or infiltration of perigastric tissues. According to new 7<sup>th</sup> UICC T stage classification, it is very difficult to differentiate T3 and T4a stages on CT scans, because serosa is not visible, and subserosa fatty tissue is different in every person. It can also be challenging to differentiate perigastric tissues infiltration in cases of gastric cancer from perigastric inflammation or fibrosis; this is why T2 stage tumors may mimic T3 and T4 stage tumors. Direct tumor spread and its invasion into adjacent tissues and organs correspond with T4b stage tumors [23] [24].

According to our results the accuracy and sensitivity of T3 staging are 75% and 100%, while that of T4 stage were 75 and 44.4 respectively. This in agreement of the results of previous reports [25], recorded that the overall accuracy of CT in preoperative T staging of gastric cancer ranges from 69% to 85%.

Regional lymph node where considered to be involved when the shorter axis

diameter was greater than 6 mm for the perigastric region, and greater than 8 mm for extraperigastric lymph node. In addition to this size criteria, central necrotic lymph node and clustered lymph node regardless of size were also considered to represent local metastases. N staging was determined as follows: N0, no evidence of lymph node metastasis; N1, 1 - 2 lymph nodes; N2, 3 - 6 lymph nodes; and N3, more than 7, (N3a 7 - 15 & N3b more than 15) lymph nodes affected [26].

In N staging of gastric cancer, the accuracy of previous reports was ranged between 51% and 76% [19]. Our results using MDCT have shown similar results for N0 (62.5%), N2 (87.5%) and N3 (75%), while N1 accuracy recorded 37.5% not in agreement with previous reports.

In our current study we found that the sensitivity of MSCT was 33.33% in N0 staging, 66% in N1, and 0% in N2 staging (as no cases staged as N2); and 0% also in N3 (4 patients staged pathologically as N3, 3 of them staged as N1 and 1 as N2). According to the previous studies, the wide ranges of sensitivity (48% to 91%) demonstrate the problem of CT in nodal staging [27]. CT has significant inherent limitations in the nodal staging of gastric cancer because of the high frequency of microscopic nodal invasion (involvement of normal-size nodes) and the poor differentiation between reactive or inflammatory and metastatic nodal enlargement.

Most common distant metastases of gastric cancer are in the liver. Less common are in lungs, suprarenal glands, kidneys, bones, brain and digestive system. In case of disseminated gastric cancer, you can see peritoneal metastases that correlate with cancer size and T stage.

It is important to diagnose carcinomatosis before the surgery. CT scan carcinomatosis signs are: ascites, great omentum nodes, thickening and nodes of small intestine walls, intraperitoneal infiltration of fatty tissue, contrast enhancement. Ascites is the predisposing factor of peritoneal metastases. Chang *et al.* measured the ascites volume on CT scans and found that  $\geq 50$  mL of ascites means carcinomatosis in 75% - 100% of patients [28].

According to Barros *et al.* [29] sensitivity of M0 is (93 - 100)%, and accuracy is (90%), our results was similar 100% and 85% respectively. The results regarding M1 was (62.5%) for sensitivity and (85%) for accuracy compared with (72% - 83%) sensitivity and 90% accuracy in Barros *et al.* [29] results. Currently, the limitation of computed tomography in M1 staging and low M1 sensitivity is related to the limitation in detection of secondary peritoneal involvement [30]. In the present study, three cases were classified as M0 at the preoperative evaluation, but peritoneal metastatic implants were intraoperative found and were later histopathologically confirmed. After retrospective analysis, one of these cases presented a small amount of ascites in the posterior cul de sac, but the presence of peritoneal implant could not be tomographically detected in any of the cases.

## 6. Conclusion

Multidetector CT with MPR is very essential nowadays in estimation of gastric

neoplasms. Detailed CT examination of the stomach can be best performed using double contrast, IV and oral (we use water as neutral oral contrast in this article). Accurate CT examination has an advantage over endoscopy in estimation of extraluminal lesions, lymph nodes and distant metastasis. So MSCT can differentiate between benign and malignant gastric neoplasms, determine the stage and spread, and also monitor the response to treatment. As regarding its role in staging, MSCT presents excellent accuracy in the staging of tumor invasion depth (T) and in the staging of metastatic neoplastic disease (M). Despite the good accuracy in the staging of patients without lymph node disease (N0), the method presents limitations in the staging of lymph node involvement.

### Conflicts of Interest

The authors declare no conflicts of interest regarding the publication of this paper.

### References

- [1] Ferlay, J., Soerjomataram, I. and Ervik, M. (2013) Globocan 2012 v1.0, Cancer Incidence and Mortality Worldwide: IARC CancerBase No. 11. International Agency for Research on Cancer, Lyon, France. <http://globocan.iarc.fr>
- [2] Thrumurthy, S.G., Chaudry, M.A. and Hochhauser, D. (2013) The Diagnosis and Management of Gastric Cancer. *British Medical Journal*, **347**, f6367. <https://doi.org/10.1136/bmj.f6367>
- [3] Blakely, A.M. and Miner, T.J. (2013) Surgical Considerations in the Treatment of Gastric Cancer. *Gastroenterology Clinics of North America*, **42**, 337-357. <https://doi.org/10.1016/j.gtc.2013.01.010>
- [4] Edge, S., Byrd, D.R. and Compton, C.C. (2010) The American Joint Committee on Cancer: The 7th Edition of the *AJCC Cancer Staging Manual* and the Future of TNM. *Annals of Surgical Oncology*, **17**, 1471-1474. <https://doi.org/10.1245/s10434-010-0985-4>
- [5] Lee, M.H., Choi, D., Lee, M.W. and Park, M.J. (2012) Gastric Cancer: Imaging and Staging with MDCT Based on the 7th AJCC Guidelines. *Abdominal Imaging*, **37**, 531-540. <https://doi.org/10.1007/s00261-011-9780-3>
- [6] Park, S.R., Kim, M.J. and Ryu, K.W. (2010) Prognostic Value of Preoperative Clinical Staging Assessed by Computed Tomography in Resectable Gastric Cancer Patients: A Viewpoint in the Era of Preoperative Treatment. *Annals of Surgery*, **251**, 428-435. <https://doi.org/10.1097/SLA.0b013e3181ca69a7>
- [7] Furukawa, K., Miyahara, R. and Itoh, A. (2011) Diagnosis of the Invasion Depth of Gastric Cancer Using MDCT with Virtual Gastroscopy: Comparison with Staging with Endoscopic Ultrasound. *American Journal of Roentgenology*, **197**, 867-875. <https://doi.org/10.2214/AJR.10.5872>
- [8] Coburn, N., Seevaratnam, R. and Paszat, L. (2014) Optimal Management of Gastric Cancer: Results from an International RAND/UCLA Expert Panel. *Annals of Surgery*, **259**, 102-108. <https://doi.org/10.1097/SLA.0b013e318288dd2b>
- [9] Dixon, M., Cardoso, R., Tinmouth, J., *et al.* (2014) What Studies Are Appropriate and Necessary for Staging Gastric Adenocarcinoma? Results of an International RAND/UCLA Expert Panel. *Gastric Cancer*, **17**, 377-382. <https://doi.org/10.1007/s10120-013-0262-x>

- [10] Moschetta, M., Marzullo, A., Scardapane, A., Angelelli, G., Stabile-Ianora, A.A. and Anglani, A. (2009) Preoperative T Staging of Gastric Carcinoma Obtained by MDCT Vessel Probe Reconstructions and Correlations with Histological Findings. *European Radiology*, **20**, 138-145. <https://doi.org/10.1007/s00330-009-1482-7>
- [11] Kwee, R.M. and Kwee, T.C. (2009) Imaging in Assessing Lymph Node Status in Gastric Cancer. *Gastric Cancer*, **12**, 6-22. <https://doi.org/10.1007/s10120-008-0492-5>
- [12] Rocco, A. and Nardone, G. (2007) Diet, *H pylori* Infection and Gastric Cancer: Evidence and Controversies. *World Journal of Gastroenterology*, **13**, 2901-2912. <https://doi.org/10.3748/wjg.v13.i21.2901>
- [13] Macdonald, J.S., Smalley, S.R., Benedetti, J., *et al.* (2001) Chemo-Therapy after Surgery Compared to Surgery Alone for Adenocarcinoma of the Stomach or Gastroesophageal Junction. *The New England Journal of Medicine*, **395**, 725-730. <https://doi.org/10.1056/NEJMoa010187>
- [14] Allum, W.H., Blazeby, J.M., Griffin, S.M., *et al.* (2011) Guidelines for the Management of Oesophageal and Gastric Cancer. *Gut*, **60**, 1449-1472. <https://doi.org/10.1136/gut.2010.228254>
- [15] Perez, C.A. and Brady, L.W. (2008) Principles and Practice of Radiation Oncology. Lippincott Williams & Wilkins, Philadelphia, PA, 620-636.
- [16] Yan, C., Zhu, Z.G., Yan, M., *et al.* (2009) Value of Multidetectorrow Computed Tomography in the Preoperative T and N Staging of Gastric Carcinoma: A Large-Scale Chinese Study. *Journal of Surgical Oncology*, **100**, 205-214. <https://doi.org/10.1002/jso.21316>
- [17] Hargunani, R., Maclachlan, J., Kaniyur, S., *et al.* (2009) Cross-Sectional Imaging of Gastric Neoplasia. *Clinical Radiology*, **64**, 420-429. <https://doi.org/10.1016/j.crad.2008.09.012>
- [18] Moore, J.R. (2009) Gastric Carcinoma 30 Years Review. *Canadian Journal of Surgery*, **29**, 25-28.
- [19] Kim, H.S., Han, H.Y., Choi, J.A., *et al.* (2001) Preoperative Evaluation of Gastric Cancer: Value of Spiral CT during Gastric Arteriography (CTGA). *Abdominal Imaging*, **26**, 123-130. <https://doi.org/10.1007/s002610000167>
- [20] Kumano, S., Murakami, T. and Kim, T. (2005) T Staging of Gastric Cancer: Role of Multi-Detector Row CT. *Radiology*, **237**, 961-966. <https://doi.org/10.1148/radiol.2373041380>
- [21] D'Elia, F., Zingarelli, A., Grani, M. and Palli, D. (2000) Hydro-Dynamic CT Preoperative Staging of Gastric Cancer: Correlation with Pathological Findings. A Prospective Study of 107 Cases. *European Radiology*, **10**, 1877-1881. <https://doi.org/10.1007/s003300000537>
- [22] Kristina, Z., Irena, K. and Mindaugas, K. (2015) Comparison of Different Methods of Multislice Spiral Computed Tomography for the Preoperative Gastric Cancer Staging. *Surgical Science*, **6**, 427-435. <https://doi.org/10.4236/ss.2015.69061>
- [23] Washington, K. (2010) 7th Edition of the AJCC Cancer Staging Manual: Stomach. *Annals of Surgical Oncology*, **17**, 3077-3079. <https://doi.org/10.1245/s10434-010-1362-z>
- [24] Kwon, S.J. (2011) Evaluation of the 7th UICC TNM Staging System of Gastric Cancer. *Journal of Gastric Cancer*, **11**, 78-85. <https://doi.org/10.5230/jgc.2011.11.2.78>
- [25] Mani, N.B., Suri, S., Wig, J.D. and Gupta, S. (2001) Two-Phase Dynamic Contrast-Enhanced Computed Tomography with Water-Filling Method for Staging of

Gastric Carcinoma. *Clinical Imaging*, **25**, 38-43.

[https://doi.org/10.1016/S0899-7071\(99\)00134-5](https://doi.org/10.1016/S0899-7071(99)00134-5)

- [26] Chamadol, N., Wongwiwatchai, J. and Bhudhisawasd, J. (2008) Accuracy of Spiral CT in Preoperative Staging of Gastric Carcinoma: Correlation with Surgical and Pathological Findings. *Journal of the Medical Association of Thailand*, **91**, 356-363.
- [27] Botet, J.F., Lightdale, C.J., Zauber, A.G., *et al.* (1991) Preoperative Staging of Gastric Cancer: Comparison of Endoscopic US and Dynamic CT. *Radiology*, **181**, 426-432. <https://doi.org/10.1148/radiology.181.2.1924784>
- [28] Chang, D.K., Kim, J.W., Kim, B.K., *et al.* (2005) Clinical Significance of CT-Defined Minimal Ascites in Patients with Gastric Cancer. *World Journal of Gastroenterology*, **11**, 6587-6592. <https://doi.org/10.3748/wjg.v11.i42.6587>
- [29] Barros, R.H.O., Penachim, T.J. and Martins, D.L. (2015) Multidetector Computed Tomography in the Preoperative Staging of Gastric Adenocarcinoma. *Radiologia Brasileira*, **48**, 74-80. <https://doi.org/10.1590/0100-3984.2014.0021>
- [30] Kim, Y.H., Lee, K.H., Park, S.H., *et al.* (2009) Staging of T3 and T4 Gastric Carcinoma with Multidetector CT: Added Value of Multiplanar Reformations for Prediction of Adjacent Organ Invasion. *Radiology*, **250**, 767-775. <https://doi.org/10.1148/radiol.2502071872>