

# Topical 40% *Loranthus europaeus* Ointment as an Alternative Medicine in the Treatment of Acute Cutaneous Leishmaniasis versus Topical 25% Podophyllin Solution

Khalifa E. Sharquie\*, Adil A. Noaimi, Banaz M. Saleh, Zinah A. Sharara, Wasnaa S. Al-Salam

Department of Dermatology, College of Medicine, University of Baghdad, Iraqi & Arab Board for Dermatology & Venereology, Baghdad Teaching Hospital, Medical City, College of Medicine, Baghdad, Iraq

Email: \*ksharquie@ymail.com, adilnoaimi@yahoo.com, banazali2014@yahoo.com, zeena.shararah@gmail.com, wasnaa.alsalam@hotmail.com

**How to cite this paper:** Sharquie, K.E., Noaimi, A.A., Saleh, B.M., Sharara, Z.A. and Al-Salam, W.S. (2017) Topical 40% *Loranthus europaeus* Ointment as an Alternative Medicine in the Treatment of Acute Cutaneous Leishmaniasis versus Topical 25% Podophyllin Solution. *Journal of Cosmetics, Dermatological Sciences and Applications*, 7, 148-163.

<https://doi.org/10.4236/jcdsa.2017.72013>

**Received:** January 18, 2017

**Accepted:** June 17, 2017

**Published:** June 20, 2017

Copyright © 2017 by authors and Scientific Research Publishing Inc.

This work is licensed under the Creative Commons Attribution International License (CC BY 4.0).

<http://creativecommons.org/licenses/by/4.0/>



Open Access

## Abstract

**Background:** Cutaneous leishmaniasis (CL) is an endemic disease in Iraq, now is running in an outbreaks. Many therapies have been tried in treatment of the disease. **Objective:** *Loranthus europaeus* (LE) is a well-known medical plant and has many pharmacological effects in many *in vitro* studies. The aim of the study is to evaluate the effectiveness of 40% LE ointment and compared it with topical 25% podophyllin solution in treatment of acute CL. **Patients and Methods:** Thirty five patients with acute CL were enrolled in this single blinded, therapeutic, comparative study, which was done in the Department of Dermatology, Baghdad Teaching Hospital, Baghdad, Iraq during January 2015-July 2015. The total number of lesions were 86 (76 lesions treated and ten lesions in a covered area left without treatment as control). Duration of lesions ranged from 4 to 12 ( $7.37 \pm 2.77$ ) weeks. The size of lesions ranged from 0.5 - 7 ( $2.81 \pm 1.76$ ) cm. Diagnosis was confirmed by biopsy and/or smears. Lesions were divided in to two groups and scored as (mild, moderate, marked, complete cure) according to a modified Sharquie's leishmania score to assess the objective response to the topical or systemic therapy. **Group A:** Thirty three (43.42%) lesions treated with topical 25% podophyllin solution once weekly for maximum 6 weeks. **Group B:** Forty three (56.58%) lesions treated with 40% LE ointment once daily at bedtime for 6 hours under occlusion for maximum 6 weeks. The followed-up was carried out every 2 weeks for 8 weeks during treatment, then monthly for next three months after end of therapy. **Results:** the total number of lesions was 86 lesions, 46 (53.49%) were ulcerated and 40 (46.51%) were dry; 18 (51.43%) patients had single lesion while 17 (48.57%) patients had multiple lesions. At the end of therapy (6

weeks after starting treatment), the cure rate was 84.84% in **Group A**, and 79.07% in **Group B**. When the two groups compared with each other there was no statistical significance difference were  $P$  value = 0.648. While untreated ten lesions that lefts as control did not showed any signs of healing. **Conclusion:** Topical 40% *Loranthus europaeus* ointment is a new effective modality for treatment of acute CL and as effective as 25% podophyllin solution with no any noticeable local or systemic side effects.

## Keywords

Cutaneous Leishmaniasis, Alternative Therapy, *Loranthus europaeus*

## 1. Introduction

Cutaneous Leishmaniasis (CL) is a major public health problem in the WHO Eastern Mediterranean, when over 100,000 new cases of CL are reported annually but the actual incidence is estimated to be three to five times higher, since not all cases of CL are reported to health authorities [1].

Iraq is considered as an endemic country where the most common causative agents are *L. major* and *L. tropica* that approved recently by PCR technique. [2] In the last few years, Iraq is suffering from severe outbreaks of the disease, due to floods that occurred because of heavy rains which result in the rise of water level and sank of many towns and villages that led to displacement and spread of rodents, and also due to continuous wars and huge displacement of thousands of people from their places and living in bad conditions and poor housing made them more exposure to sand fly. Although it is not a life threatening condition but in most situations, the treatment is mandatory to prevent permanent disfigured [1].

Many different therapeutic interventions are used including systemic, local and physical treatment, in addition to alternative therapy [3].

Systemic treatments like Pentavalent antimonial compounds (sodium stibogluconate and meglumine antimoniate), have been used since many years, but due to the painful intra-muscular administration with long treatment periods, serious side effects are not always available and the emergence of antimonial-resistant [4] [5], other systemic drugs can be used: antifungal [6] [7] dapsone [8], and oral zinc sulfate [9]. While topical treatment had been effectively used either intralesionally given like pentavalent antimony compounds [10], hypertonic saline [11], 2% zinc sulfatesolution [12] and metronidazole [13]. Or topically applied such as paromomycin [14] and physical therapy in mode of vaporization, cauterization, freezing, and application of heat can be used like microwave therapy [15] 50% TCA [16] and cryotherapy [17].

Podophyllin is a plant extract; it is used in treatment of many cutaneous diseases like genital wart, oral hairy leukoplakia, psoriasis, basal cell carcinoma and recently used in treatment of CL with high encouraging result reach to 85% cure rate [18] [19] [20] [21] [22].

The seeking for alternative therapies as topical one is safer and less painful to the patients, and now in an increasing especially when failure of main systemic medical treatments, the drugs are not available or expensive. Many herbal remedies have been used for long period of time in both traditional and modern medicine around world and different plants of medical value used worldwide for treatment of CL [23] [24].

Natural products extracted from plants and used for treatment of CL in many *in vitro* studies and discovered to have activity against leishmania parasite [25] [26].

In this study we selected the medicinal plant *Loranthus europaeus* was based on the fact that this plant was not previously used as antileishmanial agent, and because it contains many bioactive compounds that had been extracted and investigated in many *in vitro* studies from other plants and showed antileishmanial activity.

### 1.1. *Loranthus europaeus*

**Synonyms:** (Latin name [27]: *Loranthus europaeus* Jacquin; in Europe [28]: European yellow mistletoe, Summer mistletoe; in Italy [29]: *Vischio quercino*; in Arabic [30]: Hib el-debgh, Habet pukour, Fulful Hawa and Balaw-Demoke in kirdish [31]).

### 1.2. Classification: [32]

***Loranthus*:** is a genus of parasitic plants that grows on the branches of woody trees. It belongs to the family *Loranthaceae* (the showy mistletoe family) and this genus have 1253 species [33] [34].

***Loranthus europaeus*:** is a hemi-parasite mistletoe, it is a deciduous plant (flower are produced in May and June), dull brown twinges, the fruit is yellow roundish berry, which remain sticky even after dried, the fruits ripen in late autumn and gradually fall off in late winter, the plant grows vigorously on aging trees mostly on branches of oak, and chestnut as host trees. Once established, the mistletoe take minerals and water from the host tree, and block sunlight through its dense foliage, the most important vectors of yellow mistletoe are birds. [35] It is distributed in south-west Europe, south Russia, Anatolia, Iran and Iraq. [31] In Iraq, *LE* grows in the North especially in Amadia, Roundoze and Sulymania (**Figure 1**) [30] [31].

### 1.3. *Loranthus europaeus* in the Folk Medicine

*LE* had a known importance in Iraqi folk medicine for long time ago, for treating boils and abscess ,were a dry fruit used in form of poultice after mastication and moisture in mouth ,it is claimed that the poultice cause maturation and acceleration the drainage of pus from the boils, however the mechanism of action of this was unknown, until 2006, a study from Iraq done and explained the effect of *LE* oil extract in pyogenic inflammation in animals and concluded that the oil extract may act as immunomodulator during bacterial infection and it is contain

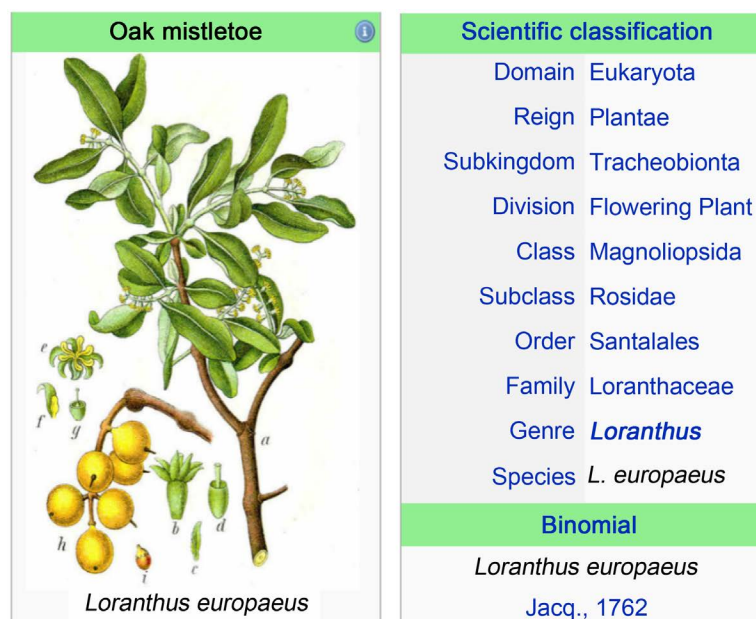


Figure 1. *Loranthus europaeus* classification [32].

many substances that act as a chemotactic agent for neutrophil and promote macrophage activity [30].

#### 1.4. Chemical Constituents of *Loranthus europaeus*

Many studies showed that *LE* contain many biological compounds including: Flavonoids (kaempferol, quercetin [36] & rutin [37]), alkaloids [38], glycosides, carbohydrate, aldehyde, ketones, protein, polysaccharide, triterpenoid [39] and monoterpenoides [40], phenolic acid (caffeic and gallic acids) [41], lipid include Palmitic acid, paraffin  $C_{30}H_{62}$  and wax alcohol and sugar include sucrose [42].

The mechanism of action of many of these active ingredients had been extracted from other plants and investigated *in vitro* studies for demonstrating antileishmanial activity such as: Alkaloids that are able to intercalate DNA or interfere with the metabolism of aromatic amino acids in parasite [43].

As the iron ( $Fe^{2+}$ ) is essential for organism growth and replication inside macrophage, a chelator effect of the quercetin had been evaluated in interference of parasite's iron metabolism and showed leishmanicidal action, in addition quercetin can induce the production of reactive oxygen species (ROS), that leading to mitochondrial dysfunction and ultimately causing parasite death [44]-[49].

The leishmanicidal activity of caffeic acid may attribute to the interaction with iron and it could cause change in the structure of cytoplasmic proteins that inhibit cell division. [50] *LE* also contain polysaccharide and aldehyde that show education in an accelerate wound healing [40], this may contribute to rapid ulcer healing of CL and decrease scar formation which is the main target in CL treatment, and also the antimicrobial effect that prevent secondary bacterial infection [30].

In addition to above *LE* have many other pharmacological effects like: antioxidant [41] [42], anti-microbial [30], anti-inflammatory [38], anti-tumor [39],

immunomodulation [51], neuroprotective effects [52] and acceleration of wound and burn healing [34] [53].

### 1.5. Side Effects of *Loranthus europaeus*

Topical poultice after mastication used in drainage of abscess, this method used for long time ago as folk medicine in Iraq, and no any topical and systemic sides effects had been mentioned in medical literatures from used it topically.

While recently many *in vitro* studies showed side effects from used it systemically including hematopoietic toxicity and genotoxic effect on bone marrow and peripheral blood cells of mice [54] [55].

The aim of the present work is to evaluate 40% *Loranthus europaeus* ointment as an alternative therapy in the treatment of acute cutaneous leishmaniasis.

## 2. Patients and Methods

This is an interventional, case controlled, single blinded, comparative, therapeutic study conducted in the Department of Dermatology, Baghdad Teaching Hospital, Medical City, Baghdad, Iraq, from January 2015 to July 2015.

Full history was taken from each patient regarding the following: age, gender, address, duration of the lesions and their number, history of previous therapy, family history, past medical history, obstetric history regarding pregnancy and past drug history. Close physical examination was performed regarding site, size, type of the lesions and regional lymphadenopathy.

A total of 35 patients with typical acute CL, enrolled in this study, with 19 (54.29%) patients were female and 16 (45.71%) patients were males, with female to male ratio was 1.1:1, their ages ranged from 2 - 60 years old with a median about 30 years old a mean  $\pm$  SD  $26.48 \pm 16.61$ .

Patients with the following criteria were excluded from this study: pregnancy, chronic diseases like diabetes mellitus, peripheral neuropathy, poor peripheral circulation, immune compromised patients and other severe illness, and patients on prolonged corticosteroid therapy ,lesions with surface area more than 10 cm<sup>2</sup> or lesions close to vital organ like eyes, also patients who received any anti-leishmanial treatment either local or systemic, if the lesions of more than 12 weeks duration were excluded to possibility of self-healing.

The total number of lesions were 87, divided as follow: seventy six lesions treated, 46 (60.53%) lesions were ulcerated, 30 (39.47%) lesions were non-ulcerated, while 10 non ulcerated lesions in a covered area were left untreated as a control after obtaining the consent from the patients. The size of lesions ranged from 0.5 - 7 cm in diameter with a mean  $\pm$  SD  $2.81 \pm 1.76$  cm. The duration of lesions ranged from 4 - 12 weeks with a mean  $\pm$  SD  $7.37 \pm 2.77$  weeks.

Formal consent was taken from each patient after full interrogation and explanation to each patient about the nature of disease, course ,treatment modalities and their complications, follow up, prognosis and need for pre and post treatment photograph. Also the ethical approval was granted by the Scientific Committee of the Scientific Council of Dermatology and Venereology-Iraqi

Board for Medical Specializations. In all patients, the diagnosis was done by history and clinical examination, and confirmed by biopsy and smear. Smear was done by cleaning the lesion with 70% alcohol then using a dental broach. A sample was taken from more than one area of the lesion, smeared onto a clean glass slide, and stained with Leishman stain. Then a microscopical examination of the smear was done to demonstrate the amastigotes inside or outside the macrophages.

Lesions had been divided into two groups:

Group A: Fifteen patients with 33 lesions, 17 (51.52%) lesions were ulcerated while 16 (48.48%) lesions were non-ulcerated treated with 25% topical podophyllin in tincture benzoin. It was prepared by dissolving 25 g of podophyllin resin powder, purchased from Merck Company, Germany, in 100 ml of tincture benzoin, stored in tight, light resistant container and kept at room temperature. Prior to application, adjacent skin protected by applying petrolatum then the solution was applied with a cotton-tipped applicator. For the non-ulcerated type, the lesion was covered with thin layer of solution, while for ulcerated type, the solution was applied to the margin of the ulcer. The amount of solution that was used in each session did not exceed 0.5 ml and the surface area treated did not exceed 10 cm<sup>2</sup> in order to minimize the local and the systemic side effects of the drug. The solution was allowed to dry in approximately 2 minutes and the patient instructs to wash off it after 4 - 6 hours. The solution was applied once weekly for maximum 6 weeks.

Group B: Twenty patients with 43 lesions, 29 (67.44%) lesions were ulcerated, 14 (32.56%) lesions were non-ulcerated, treated by topical 40% *Loranthus europaeus* ointment.

The plant obtained from the local Iraqi market for herbs and medicinal plants, the product cleaned properly by took only dry fruit and removed other remnant material of the plant, then 40% *Loranthus europaeus* ointment was prepared after crushed 40 grams of dry fruit by mortar then 60 grams of petrolatum (Vaseline®) was added, mixed them together until a coherent mixture formed and kept in a 30 gram tight sterile container and kept at room temperature, the treatment given to the patient in each visit after advise him to used it once daily at bed time for at least 6 hours under occlusion until cure for maximum 6 weeks.

### Assessment and Follow-Up

The lesions were assessed in the first and subsequent visits, by monitoring the change in the color of lesions, measuring diameter of the color and indurated area using tape measure by taking the diameter of regular lesion while in irregular one, multiple diameters were measured and take the mean, the same was done with the ulcer diameter. Photos were taken in each visit in the same place, distance and illumination, by Samsung Galaxy note 10.1 with camera resolution 8 Megapixel.

The followed-up carried out every 2 weeks for 8 weeks during treatment, then monthly for next three months after end of therapy to monitor any sign of re-

lapse, during each visit the lesion of the patients was re-scored to record the grade of the response and any local and systemic side effect.

In the present study, Sharquie modified his previous score to be more sensitive and specific, so scoring done by using “A modified Sharquie’s leishmania score to assess the objective response to topical or systemic therapy” (**Table 1**) [56]:

Score 16-12..... Mild response.

Score 12-8..... Moderate response.

Score 8-4 ..... Marked response.

Score 4-0 ..... Complete clearance.

Both marked and complete responses are considered as a cure.

### 3. Statistical Analysis

Was done by using SPSS v.20, were chi square used to compare between grades of response between two groups, while paired t-test was used to compare means of score between visits for each group, P value  $\leq 0.05$  was considered significant.

### 4. Results

Thirty five patients included in this study and no defaulted accord.

Regarding the numbers of lesions, 18 (51.43%) patients had single lesion and 17 (48.57%) patients had multiple lesions the most common site of body that frequently affected were in the lower extremities 38 (50%) lesions, then the upper extremities 31 (40.79%) lesions, while in the face were 4 (5.26%) lesions. Family history of CL was positive in ten (28.6%) patients and most of patients were from Baghdad.

1) According to the therapeutic response in each group from first visit until 6 weeks after treatment were as (**Table 2**).

Group A: Thirty three (43.42%) had been treated with topical 25% podophyllin solution.

In the baseline first visit: The mean  $\pm$  SD of the score was (13.64  $\pm$  1.950). After 2 weeks from starting treatment: The mean score  $\pm$  SD was (10.97  $\pm$  1.723) this was statistically significant when compared with baseline first visit, where p value  $< 0.0001$ .

**Table 1.** A modified Sharquie’s Leishmania score to assess the objective response to the topical or systemic therapy.

Score	Change in the color of lesion	Reduction rate in the color diameter of lesion	Reduction rate in the induration of lesion	Reduction rate of ulcer/crust
4	Bright red	-	-	-
3	Red	0 - 25%	0 - 25%	0 - 25%
2	Dusky red	25% - 50%	25% - 50%	25% - 50%
1	Dark brown	50% - 75%	50% - 75%	50% - 75%
0	Light brown	>75%/clearance	>75%/clearance	>75%/clearance

**Table 2.** The mean and SD of the score of response to the treatment in each group from first visit to the end of therapy.

GROUP		First visit	After 2 weeks	After 4 weeks	After 6 weeks
Group A	Mean $\pm$ SD	13.64 $\pm$ 1.950	10.97 $\pm$ 1.723	7.67 $\pm$ 2.072	4.45 $\pm$ 2.489
	P*	-	<0.0001	<0.0001	<0.0001
Group B	Mean $\pm$ SD	15.16 $\pm$ 1.326	11.58 $\pm$ 1.418	8.23 $\pm$ 2.125	4.72 $\pm$ 2.693
	P*	-	<0.0001	<0.0001	<0.0001

P\* = p value, paired t-test used in both groups to compare mean score of response in subsequent visit with baseline first visit.

After 4 weeks: The mean score  $\pm$  SD was 7.67  $\pm$  2.072, this was statistically significant when compared with baseline visit, where p value < 0.0001.

After 6 weeks: The mean score  $\pm$  SD was 4.45  $\pm$  2.489, also this was statistically significant when compared with baseline visit, where p value < 0.0001. (Figure 2) showed forty years old female with cutaneous leishmaniasis on the chest A: before treatment B: after 4 weeks treatment with 25% topical podophylline solution

Group B: Forty three (56.58%) lesions had been treated with topical 40% *Loranthus europaeus* ointment.

In baseline first visit: The mean  $\pm$  SD of the score was 15.16  $\pm$  1.326.

After 2 weeks from treatment: The mean score  $\pm$  SD was 11.58  $\pm$  1.418. this was statistically significant when compared with baseline visit, where p value < 0.0001.

After 4 weeks: The mean score  $\pm$  SD was 8.23  $\pm$  2.125. this was statistically significant when compared with baseline visit where p value < 0.0001.

After 6 weeks: The mean score  $\pm$  SD was 4.72  $\pm$  2.693, and this also statistically significant when compared with baseline first visit where p value < 0.0001.

2) According to the grade of response in relation to the duration in each group: **Table 3.**

Group A:

After 2 weeks from treatment: Twenty two (66.67%) lesions showed mild response while 11 (33.33%) had moderate response, and no any lesion showed marked or complete response in this stage.

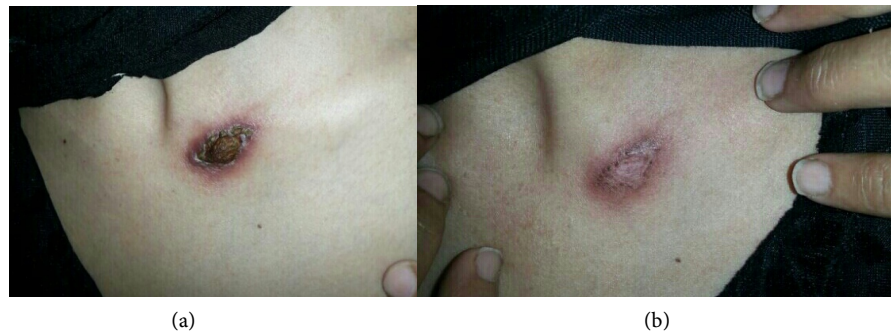After 4 weeks: Fifteen (45.45%) lesions showed marked response, while 3 (9.09%) lesions still had mild response.

After 6 weeks: Ten (30.30%) lesions had marked response and 18 (45.45%) lesions showed complete response, so the clinical cure rate was 84.84%, where both marked and complete cure considered as a cure.

Five (15.15%) lesions still had moderate response were showed marked to complete response in 8th week.

Regarding the side effects, no serious local or systemic side effects were reported apart from mild burning sensation occurring in 10% patients and were tolerable; localized edema at site of lesions occurred in 70% of treated lesions that subsided within 2 - 3 days that not need to cessation of therapy. post-inflammatory hyper pigmentation was noted in all treated lesions that also subside





**Figure 2.** Forty years old female with cutaneous leishmaniasis on the chest (a): before treatment, (b): after 4 weeks treatment with 25% topical podophylline solution.

**Table 3.** The grade of response in relation to duration of treatment in each group after 6 weeks.

Grade of response	Group A	Group B
	No. of lesions %	No. of lesions %
Mild	0	0
Moderate	5 (15.15%)	9 (20.93%)
Marked	10 (30.30%)	15 (34.88%)
Complete clearance	18 (54.54%)	19 (44.19%)
Clinical cure (marked + complete)	<b>28 (84.84%)</b>	<b>34 (79.07%)</b>
Total = 76	33	43

$\chi^2 = 0.869$ , P value = 0.648.

with time (**Figure 2**).

In all clinical cured lesions, there was no or minimum scarring at the site of lesions.

Group B:

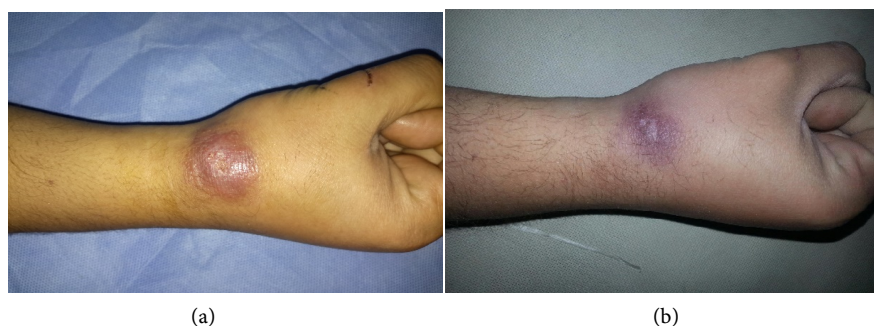After 2 weeks: thirty (69.77%) lesions showed mild response, while 13 (30.23) lesions had moderate response, and no any lesions showed marked or complete response in this stage.

After 4 weeks: twenty (46.51%) lesions showed moderate response and 18 (41.86%) lesions had marked response, while 5 (11.63%) lesions, still had mild response.

After 6 weeks: fifteen (34.88%) showed marked response and 19 (44.19%) had complete response, so clinical cure rate was 79.07%, where both marked and complete response considered as a cure. (**Figure 3**) showed thirty five years old male with cutaneous leishmaniasis on the right wrist. A: Before treatment, B: After 4 weeks treatment by 40% *Loranthus europaeus* ointment.

Nine (20.93%) lesions still had moderate response were showed marked to complete cure after 8th week.

No any local or systemic side effects had been reported during the treatment and follow up period, post-inflammatory hyperpigmentation was noted in all treated lesions that subside with time. In all clinical cured lesions there was no or minimum scarring at site of lesions.



**Figure 3.** Thirty five years old male with cutaneous leishmaniasis on the right wrist. (a): Before treatment, (b): After 4 weeks treatment by 40% *Loranthus europaeus* ointment.

There were no significant difference in the grades of responses in relation to the durations in the treatment between group A and group B, were:

- After 2 weeks the  $\chi^2 = 0.083$  P value = 0.773.
- After 4 weeks the  $\chi^2 = 0.174$  P value = 0.917.
- After 6 weeks the  $\chi^2 = 0.869$  P value = 0.648.

P value  $\geq 0.05$  considered non-significant.

3) Regarding the difference in response between ulcerative and non-ulcerative lesions in each group after 6 weeks:

This study revealed that there were no significance difference in the response between ulcerated lesions and dry lesions in both therapies were the  $\chi^2 = 0.793$  P value = 0.673 in group A and  $\chi^2 = 2.135$  P value = 0.344 in group B.

At the end of study, untreated ten lesions that lefts as control did not showed any signs of healing.

## 5. Discussion

Cutaneous leishmaniasis (CL) is a worldwide public health problem and it is caused by different *Leishmania* species [3].

Iraq is considered as an endemic country since decades, and in the last few years the incidence of the disease is markedly increase and thousands of victims exposed to this disfiguring disease due to floods that occur during rainfall season, and due to war, huge displacement of people and live in outdoors in bad conditions and poor housing made the sand fly easy access to humans.

Over years different modalities in treatment of CL are used, many factors like the infectious species, geographical region and the immune status of the patients affect the efficacy of the treatments [1].

Many modalities of therapies can be used in the treatment of CL like Systemic treatment with pentavalent antimonial compounds [4], antifungal [6] [7] dapsone [8], and oral zinc sulfate [9]. Orintralesionally given like pentavalent antimony compounds [10], hypertonic saline [11], 2% zinc sulfate solution [12] and metronidazole [13]. Or topically applied such as paromomycin [14], microwave therapy [15] and 50% TCA, physical treatment like cryotherapy [16] in addition to alternative medicine [3] [21] [22].

Topical 25% podophyllin solution was used recently in the treatment of CL

and gave 85% cure rate with minimum side effects.

Although presence of these modalities each treatment could have failure rate, side effects, expensive, or not available, therefore the scientist always seeking for new treatments.

Herbal therapies used for long time ago, and many trials done in treatment of CL as alternative medicine. [21] [22] As *Loranthus europaeus* is a well-known medical plant in Iraq folk medicine for long time ago, for treating boils and abscesses and because it contain many bioactive substance.

In present work topical 40% *Loranthus europaeus* ointment used to treatment of acute cutaneous leishmaniasis and when compared it with topical 25% podophyllin solution, it gave very closed cure rate (79.07%), (86%) respectively, with no any noticeable local and systemic side effects .

To our knowledge this study considered as a first report to use this plant in treatment of CL.

When topical 40% *Loranthus europaeus* ointment was compared with other local therapies like topical paromomycin the cure rate was higher cure rate reach to 79.07% and no any side effects was reported, while Topical paromomycin reported cure rate of (41.1%) in twice daily applications of the 15% paromomycin ointment on CL in the 4 weeks regimen, with reported side effects like itching, burning, edema, redness and pain. In addition, this drug was costly and unavailable and it is biochemical mechanisms are totally unknown [14].

Intralesional treatment with sodium stibogluconate, gave high cure rate reaching to 94% with one or more injection weekly, this drug is expensive, not always available. Intralesional 2% zinc sulfate solution at 10 days intervals, the cure rate reached to 97.8% usually with one or 2 injections, 7% hypertonic sodium chloride which was given intralesionally every 7 - 10 days interval for 6 weeks, with cure rate reach to 96%. All above intralesional modalities are considered painful and harmful to the patients [10] [11] [12].

Cryotherapy had been used in the treatment of CL, with 52.2% cure rate when used alone and 85% when used as combination therapy with intralesional meglumine antimonite with many side effects especially post-inflammatory hypopigmentation, in addition to that, it was a painful method. [16] 50% TCA also reported to be used in treatment of CL, with cure rate 65% when used alone, and reported recurrence of the lesions in 10% of cases [15].

When topical 40% *Loranthus europaeus* ointment was compared with 25% podophyllin solution, it was more safe as well as no any local or systemic side effects were recorded, although podophyllin is safe as shown in the pervious and present work [22] but, still caution should be taken when it is used to treat a large numbers of lesions, especially in infants in order to avoid systemic absorption and it is contraindicated in pregnant women were it is classified as category X [18].

The exact mechanism of action of topical 40% *L. europaeus* as antileishmanial not well-known, but according to the many studies that showed it is contain many active ingredients like: Flavonoids (kaempferol, quercetin and rutin) [36]

[37], alkaloids [38], glycosides, polysaccharide, triterpenoid [39] and monoterpenoids [40] and phenolic acids (caffeic and gallic acid) [41] and others, many of these active ingredients had been extracted and investigated from other plants in many *in vitro* studies and showed antileishmanial activity, such as: Alkaloid that are able to intercalate DNA or interfere with the metabolism of aromatic amino acids in parasite. [42] As the iron (Fe) are essential for organism growth and replication inside macrophage, a chelator effect of the quercetin had been evaluated in interference of parasite's iron metabolism and showed leishmanicidal action, in addition quercetin can induce the production of reactive oxygen species (ROS), that leading to mitochondrial dysfunction and ultimately causing parasite death [43] [44] [45].

The leishmanicidal activity of caffeic acid may attribute to the interaction with iron and it could cause change in the structure of cytoplasmic proteins that inhibit cell division. [46] *LE* also contain polysaccharide and Aldehyde that showed action in an accelerate wound healing [40], this might contribute to rapid ulcer healing of CL and decrease scar formation which is the main target in CL treatment, and also the antimicrobial effect that prevent secondary bacterial infection [30].

Accordingly, further studies are highly recommended *in vivo* and *in vitro* studies to assess farther mechanism of action.

In conclusion, topical 40% *Loranthus europaeus* ointment is a new effective therapy for treatment of cutaneous *leishmaniasis* and as effective as 25% podophyllin solution with no any noticeable local and systemic side effects.

## References

- [1] WHO (2014) Regional Publication, Eastern Mediterranean Series. Manul for Case Management of Cutaneous Leishmaniasis in the WHO Eastern Mediterranean Region. WHO, Cairo.
- [2] Sharquie, K.E., Noaimi, A.A., Al-Najar, S.A. and Al-Heany, A.R. (2014) Cutaneous Leishmaniasis: Comparative Techniques for Dignosis. *Journal of Dental and Medical Science (IOSR-JDMS)*, **13**, 33-37.
- [3] Gonzalez, U., Pinart, M. and Revereiz, L. (2008) Intervention for Old World Cutaneous Leishmaniasis. *Cochrane Database of Systemic Reviews*, Art. No. CD005067. <https://doi.org/10.1002/14651858.Cd005067.pub3>
- [4] Lianet, M. (2009) Current Treatment of Leishmaniasis: A Review. *The Open Antimicrobial Agents Journal*, **1**, 9-19.
- [5] Crof, S.L. and Coombs, G.H. (2003) Leishmaniasis-Current Chemotherapy and Recent Advances in the Search for Novel Drugs. *Trends in Parasite*, **19**, 502-508.
- [6] Alrajhi, A.A., Ibrahim, E.A., De Vol, E.B., Khairat, M. and Faris, R.M. (2002) Flucanazole for the Treatment of Cutaneous Leishmaniasis Caused by *Leishmania major*. *New England Journal of Medicine*, **346**, 891-895. <https://doi.org/10.1056/NEJMoa011882>
- [7] Salmanpour, R., Handjani, F. and Noughpisheh, M.K. (2001) Comparative Study of the Efficacy of Oral Ketoconazole with Intralesional Meglumine Antimoniate (Glucantime) for the Treatment of Cutaneous Leishmaniasis. *The Journal of Dermatological Treatment*, **12**, 159-162. <https://doi.org/10.1080/09546630152607899>

- [8] Al-Mutaii, N., Alshiltawy, M., El Khalawany, M., Joshi, A., Eassa, B. and Manchanda, Y. (2009) Treatment of Old World Cutaneous Leishmaniasis with Dapsone, Itraconazole, Cryotherapy, and Imiquimod, Alone and in Combination. *International Journal of Dermatology*, **48**, 862-869. <https://doi.org/10.1111/j.1365-4632.2008.04010.x>
- [9] Sharquie, K.E., Najm, R.A., Farjou, I.B. and Al-Timimi, D.J. (2001) Oral Zinc Sulfate in the Treatment of Acute Cutaneous Leishmaniasis. *Clinical and Experimental Dermatology*, **26**, 21-26. <https://doi.org/10.1046/j.1365-2230.2001.00752.x>
- [10] Sharquie, K.E. and Al-Talib, K. (1988) Intralesional Therapy of Cutaneous Leishmaniasis with Sodium Stibogluconate Antimony. *British Journal of Dermatology*, **119**, 53-57. <https://doi.org/10.1111/j.1365-2133.1988.tb07100.x>
- [11] Sharquie, K.E. (1995) A New Intra-Lesional Therapy of Cutaneous Leishmaniasis with Hypertonic Sodium Chloride Solution. *The Journal of Dermatology*, **22**, 732-737. <https://doi.org/10.1111/j.1346-8138.1995.tb03911.x>
- [12] Sharquie, K.E., Najem, R.A. and Farjou, I.B. (1997) A Comparative Control Trial of Intralesional Administrated Zinc Sulfate, Hypertonic Saline Chloride and Pentavalent Antimony Compound against Acute Cutaneous Leishmaniasis. *Clinical and Experimental Dermatology*, **22**, 169-173. <https://doi.org/10.1111/j.1365-2230.1997.tb01054.x>
- [13] Sharquie, K.E., Al-Waize, M. and Al-Asser, M. (2004) Therapy of Cutaneous Leishmaniasis with Intralesional Metronidazole. *Saudi Medical Journal*, **10**, 1512-1513.
- [14] Asilian, A., Jalayer, T., Nilforooshzadeh, M., Ghassemi, R.L., Peto, R., *et al.* (2003) Treatment of Cutaneous Leishmaniasis with Aminosidine (Paromomycin) Ointment: Double-Blind, Randomized Trial in the Islamic Republic of Iran. *Bulletin of the World Health Organization*, **81**, 353-359.
- [15] Sharquie, K.E., Al-Mashhadani, S., Noaimi, A.A. and Al-Zoubaidy, W.B. (2015) Microwave Therapy: New Treatment for Cutaneous Leishmaniasis. *Our Dermatology Online*, **6**, 125-129.
- [16] Nilforoushzadeh, M. and Jaffary, F. (2006) Comparative Effect of Topical TCA and Intralesional Meglumine Antimoniate in Treatment of Cutaneous Leishmaniasis. *International Journal of Pharmaceutics*, **2**, 633-636.
- [17] Asilian, A., Sadeghinia, A., Faghihi, G. and Momeni, A. (2004) Comparative Study of the Efficacy of Combined Cryotherapy and Intralesional Meglumine Antimoniate vs. Cryotherapy and Intralesional Meglumine Antimoniate Alone for the Treatment of Cutaneous Leishmaniasis. *International Journal of Dermatology*, **43**, 281-283. <https://doi.org/10.1111/j.1365-4632.2004.02002.x>
- [18] Habib, T.P. (2016) Sexually Transmitted Viral Infection. In: *Clinical Dermatology*, Chapter 11, 6th Edition, Mosby Inc., Toronto, 418-447.
- [19] James, W.D., Berger, T.G. and Eleston, D.M., Eds. (2016) Chap. 19. Viral Diseases. In: *Andrews' Disease of the Skin, Clinical Dermatology*, 12th Edition, WB Saunders Company, Canada, 359-417.
- [20] Sharquie, K.E., Noaimi, A.A. and Al-Jenab, W.K. (2013) Efficacy and Safety of Topical Podophyllin 5% Ointment in Patients with Mild Plaque-Type Psoriasis. *The Iraqi Postgraduate Medical Journal*, **12**, 251-258.
- [21] Sharquie, K.E., Noaimi, A.A. and AL-Zoubaidy, M.S. (2015) Treatment of Basal Cell Carcinoma by Topical 25% Podophyllin Solution. *Journal of Cosmetics, Dermatological Sciences and Applications*, **5**, 189-197. <https://doi.org/10.4236/jcdsa.2015.53023>
- [22] Sharquie, K.E., Noaimi, A.A. and AL-Ghazzi, A.G. (2015) Treatment of Cutaneous

- Leishmaniasis by Topical 25% Podophyllin Solution (Single, Blinded, Therapeutic, Controlled Study). *Journal of Dermatology & Dermatologic Surgery*, **19**, 108-113. <https://doi.org/10.1016/j.jdds.2014.10.001>
- [23] Fatima, F.F., Khalid, F.A., Nazar, N., *et al.* (2005) *In Vitro* Assessment of Anti-Cutaneous Leishmaniasis Activity of Some Sudanese Plants. *Turkiye Parazitoloji Dergisi*, **29**, 3-6.
- [24] Zerehaz, F., Salmanpour, R., Handjani, F., Aedhali, S., Panjehshahin, M.R., *et al.* (1990) A Double Blind Randomized Clinical Trial of a Topical Herbal Extract (ZHE) vs. Systemic Meglumine Antimoniate for the Treatment of Cutaneous Leishmaniasis in Iran. *International Journal of Dermatology*, **38**, 610-612. <https://doi.org/10.1046/j.1365-4362.1999.00727.x>
- [25] Mishra, B.B., Kale, R.R., Prasad, V., Tiwari, V.K. and Singh, R.K. (2011) Scope of Natural Product in Fighting against Leishmaniasis. In: *Opportunity, Challenge and Scope of Natural Products in Medicinal Chemistry*, 121-154.
- [26] Chan-Bacab, M.J. and Peña-Rodríguez, L.M. (2001) Plant Natural Product with Leishmanicidal Activity. *Natural Product Reports*, **18**, 675-688.
- [27] [www.bgflora.net/families/Loranthus\\_europaeus-en.html](http://www.bgflora.net/families/Loranthus_europaeus-en.html)
- [28] [http://www.bgflora.net/families/loranthaceae/loranthus/loranthus\\_europaeus/loranthus\\_europaeus\\_en.html](http://www.bgflora.net/families/loranthaceae/loranthus/loranthus_europaeus/loranthus_europaeus_en.html)
- [29] Guarino, C. (2008) Ethnobotanical Study of the Sannio Area, Campania, Southern Italy. *Ethnobotany Research and Applications*, **6**, 255-317. <https://doi.org/10.17348/era.6.0.255-317>
- [30] Jwad, A.H., Al-Rubae, M.A. and AL-Diab, J.M. (2006) Effects of *Loranthus europaeus* Seeds on Pyogenic Inflammation in Rabbits. *Journal of Missan Researches*, **2**, 4
- [31] Ahmed, S.A., Al-Shehbaz, I.A. and Al-Mashhadani, A.N. (2013) Vascular Plants of Hawraman Region in Kurdistan Iraq. 165-315.
- [32] [https://translate.google.iq/translate?hl=ar&sl=it&tl=en&u=https%3A%2F%2Fit.m.wikipedia.org%2Fwiki%2FLoranthus\\_europaeus&sandbox=1](https://translate.google.iq/translate?hl=ar&sl=it&tl=en&u=https%3A%2F%2Fit.m.wikipedia.org%2Fwiki%2FLoranthus_europaeus&sandbox=1)
- [33] Watson, L. and Dallwitz, M.J. (1991) The Families of Angiosperms: Automated Descriptions, with Interactive Identification and Information Retrieval. *Australian Systematic Botany*, **4**, 681-695. <https://doi.org/10.1071/SB9910681>
- [34] <http://www.plantsystematics.org/taxpage/0/genus/loranthus.html>
- [35] Lakatos, F., Mirtchev, S. and Mehemeti, A. (2014) Hand Book of Major Forest Pests in Southeast Europe. Food and Agriculture Organization of the United Nation Pristina, 71-100.
- [36] Shavvon, R.S., Mehrvarz, S.S. and Golmohammadi, N. (2012) Evidence from Micromorphology and Gross Morphology of the Genus *Loranthus* (Loranthaceae) in Iran. *Turkish Journal of Botany*, **36**, 655-666.
- [37] Harvala, E., Exner, J. and Becker, H. (1984) Flavonoids of *Loranthus europaeus*. *Journal of Natural Products*, **47**, 1054-1055. <https://doi.org/10.1021/np50036a034>
- [38] Hamiad, M.N., Numan, I.T. and Hassan, A.F. (2013) Evaluation of Anti-Inflammatory Effect of Ethyl Acetate and Methanol Extracts of *Loranthus europaeus* in Experimental Models of Acute Inflammation in Rats. *International Journal of Pharmaceutical Sciences Review and Research*, **23**, 170-174.
- [39] Nuaman, I.T. (2012) Effects of *Loranthus europaeus* Ethenylacetate and Chloroform Extract on the Growth of Rhabdomyosarcoma and Rat Embryo Fibroblast Cell Line. *International Journal of Pharmacy and Pharmaceutical Science*, **4**, 234-237.

- [40] Jawad, A.D., Al-Rubaei, M.A. and Al-Diab, J.M. (2007) Oil Extract of *Loranthus europaeus* Seed Promotes Wounds Healing. *Basrah Journal of Veterinary Research*, **6**.
- [41] Al Fartosy, A.J. and Al-Rikaby, A.K. (2007) Antioxidant Action of Monoterpene from *Loranthus europaeus* L. Seeds. *Al Basra Journal for Agricultural Science*, No. 20.
- [42] Katsarou, A., Rhizopouliou, S. and Kefalas, P. (2012) Antioxidant Potential of the Aerial Tissues of the Mistletoe *Loranthus europaeus* Jacq. *Records of Natural Products*, **6**, 349-379.
- [43] Gill, L.S. and Hawksworth, F.G. (1961) The Mistletoes: A Literature Review. In: *Technical Bulletin*, Technical Bulletin No. 1242, U.S. Department of Agriculture, 2-24.
- [44] Wright, C.W. and Phillipson, J.D. (1990) Natural Product and Development of Selective Antiprotozoal Drugs. *Phytotherapy Research*, **4**, 127-139.  
<https://doi.org/10.1002/ptr.2650040402>
- [45] Huynh, C., Sacks, D.L. and Andrews, N.W. (2006) A *Leishmania amazonensis* ZIP Family Iron Transporter Is Essential for Parasite Replication within Macrophage Phagolysosomes. *Journal of Experimental Medicine*, **203**, 2363-2375.  
<https://doi.org/10.1084/jem.20060559>
- [46] Leopoldi, M., Russo, N., Chiodo, S. and Toscano, M. (2006) Iron Chelation by the Powerful Antioxidant Flavonoid Quercetin. *Journal of Agricultural and Food Chemistry*, **54**, 6343-6351. <https://doi.org/10.1021/jf060986h>
- [47] Sen, G., Mukhopadhyay, S., Ray, M. and Biswas, T. (2008) Quercetin Interferes with Iron Metabolism in *Leishmania donovani* and Target Ribonucleotide Reductase to Exert Leishmanicidal Activity. *Journal of Antimicrobial Chemotherapy*, **61**, 1066-1075.
- [48] Miura, Y.H., Tomita, I., Watanabe, T., Hirayama, T. and Fukui, S. (1998) Active Oxygens Generation by Flavonoids. *Biological and Pharmaceutical Bulletin*, **21**, 93-96. <https://doi.org/10.1248/bpb.21.93>
- [49] Fonseca-Silva, F., Inacio, J.D.F., Canto-Cavalheiro, M.M. and Almeida-Amaral, E.E. (2011) Reactive Oxygen Species Production and Mitochondrial Dysfunction Contribute to Quercetin Induced Death in *Leishmania amazonensis*. *PLoS ONE*, **6**, e14666.
- [50] AlShammary, M.N., Abdul Mageed, R.H., Mohamad, B.I. (2012) Effect of Phenolic Compound on the Viability of *Leishmania tropica* Promastigotes: A Comparative *In Vitro* Study. *Al-Qadisyiah Medical Journal*, **8**, 84-94.
- [51] Cholkova, M., Christov, M.V., Dimitrova, D. and Evtativa, R. (2002) Flavonoids and Terpenoides Isolated from *Loranthus europaeus* with Stimulatory Effect on Lymphocyte Proliferation. *Experimental Pathology and Parasitology*, **91**, 45-48.
- [52] Zargaran, A., Zarshenas, M.M., Karimi, A., Yarmohammadi, H. and Borhani-Haghighi, A. (2013) Management of Stroke as Described by Ibn Sina (Avicenna) in Canon Medicine. *International Journal of Cardiology*, **169**, 233-237.
- [53] Ubaid, J.A., Ahmed, S.H. and Alsaady, K.M. (2012) The Activity of Hot Watery and alcoholic Extract of Seeds of *Loranthus europaeus* in Treatment of Burns. *International Journal for Science and Technology*, **7**, 115-121.
- [54] Hassan, A.F., Numan, I.T. and Al-Sammarræ, K.W. (2011) Hematopoietic Toxicity of *Loranthus europaeus* Chloroform Extract: *In-Vitro* Study. *Pharmacie Globale. International Journal of Comprehensive Pharmacy*, **7**, 1-4.
- [55] Hassan, A.F., Numan, I.T. and Al-Sammarræ, K.W. (2011) Genotoxic Study of

Different Extract of *Loranthus europaeus* Fruits on Bone Marrow and Spleen Cells of Mice: *In Vivo* Study.

- [56] Sharquie, K.E., Noaimi, A.A. and Al-Salam, W.S. (2016) Treatment of Acute Cutaneous Leishmaniasis by Oral Zinc Sulfate and Oral Ketocanazole Singly and in Combination. *Journal of Cosmetics, Dermatological Science and Applications*, **6**, 105-115. <https://doi.org/10.4236/jcdsa.2016.63014>



Scientific Research Publishing

**Submit or recommend next manuscript to SCIRP and we will provide best service for you:**

Accepting pre-submission inquiries through Email, Facebook, LinkedIn, Twitter, etc.

A wide selection of journals (inclusive of 9 subjects, more than 200 journals)

Providing 24-hour high-quality service

User-friendly online submission system

Fair and swift peer-review system

Efficient typesetting and proofreading procedure

Display of the result of downloads and visits, as well as the number of cited articles

Maximum dissemination of your research work

Submit your manuscript at: <http://papersubmission.scirp.org/>

Or contact [jcdsa@scirp.org](mailto:jcdsa@scirp.org)