

Non-Excisional Face and Neck Tightening Using a Novel Subdermal Radiofrequency Thermo-Coagulative Device

D. H. Ahn¹, R. S. Mulholland², Diane Duncan³, Malcolm Paul⁴

¹Daeyoung Plastic Surgery Practice, Seoul, South Korea; ²Private Plastic Surgery Practice, Toronto, Canada; ³Private Plastic Surgery Practice, Plastic Surgical Associates P. C., Fort Collins, USA; ⁴Department of Surgery, Aesthetic and Plastic Institute, University of California, Irvine, USA.

E-mail: mulhollandmd@spamedica.com

Received September 14th, 2011; revised October 18th, 2011; accepted November 2nd, 2011.

ABSTRACT

42 patients with broad age and ethnic demographics were treated with a novel, non-excisional, minimally invasive device to coagulate a very thin layer of sub-dermal septo-fascial fat, denature the deep reticular dermis and tighten the skin and sub-dermal matrix of connective tissue. The detailed treatment protocol and results are presented. Patients were observed for up to 6 months following the procedure. No major side effects were observed. The aesthetic outcome of this non-excisional procedure includes improvement of the position and shape of the cheek, lower lid-cheek junction, jawline and neck. The overall aesthetic results deliver a noticeable and impressive tightening of the soft-tissue and may be compared with a conservative, small excisional procedure. The authors propose this versatile device and treatment as a non-excisional, moderate facial rejuvenation procedure on its own, or as an adjunct to open procedures performed simultaneously, or as a simplified treatment for secondary skin laxity in combination with a lift procedure.

Keywords: Radio-Frequency, Liposuction, Tightening

1. Introduction

The aging baby boomers are a formidable demographic force. There is a person turning 60 years old every 10 seconds, and it is estimated that over one-fourth of the total U.S. population in 2010 was between ages 42 and 60 years [1]. This represents over 100 million potential patients with skin laxity of the head, neck and body. Skin tightening procedures are one of the fastest growing market segments, accounting for 56.9 million in device sales and 668,100 patient treatments [2]. Excisional facial surgery such as a face lift may provide a dramatic improvement, but concerns over the excisional nature of this “real surgery” and visible scarring significantly limit the popularity of the procedure, especially for Asians and other dark skin populations, who have a higher risk of post inflammatory hyper-pigmentation, wound hypertrophy and visibility of the scars. Non-invasive procedures, such as trans-epidermal radiofrequency, infrared tightening, or recently high frequency focused ultrasound, skin tightening devices have a greater acceptance, but,

the aesthetic outcome is relatively modest in comparison to excisional plastic surgery [3-6].

Radio-Frequency Assisted Liposuction (RFAL) was introduced 3 years ago for body contouring and tissue tightening [7]. This minimally invasive procedure has shown significant contraction capability when deployed in liposuction and lipo-contouring procedures [7-13]. RFAL technology harnesses the adipose tissue and septo-fascial fibrous structure of the subcutaneous space for thermal tightening and remodeling of subcutaneous tissue. It can be adapted without fat aspiration for facial and body skin tightening with a significantly lower risk of side effects compared to excisional surgery and with more significant outcomes than non-invasive procedures. This paper will review our experience with a minimally invasive, non-aspiration, non-excisional procedure employing radiofrequency energy in sub-dermal space for tightening of lax facial, cervical skin and body skin.

2. Materials and Methods

Forty-two patients with face and neck laxity presented

for treatment. 6 male and 36 female patients with age range from 28 - 70 years old and skin types I to V participated in the study.

The applicator is a bipolar, solid probe radiofrequency device. The Teflon coated internal electrode is passed directly under the skin in the hypodermal-subcutaneous fat space (**Figure 1**). The internal and external electrodes are connected at the hand-grip. The FaceTite hand piece is powered by the BodyTite platform (Invisix, Yokneam, Israel).

The RF energy is emitted from the tip of the internal electrode from the small, uncoated region, behind the bullet shaped plastic dissector at located the front. The RF energy from the internal electrode causes a coagulative necrosis of the sub-dermal fat, the lower 30% of the reticular dermis and the fibrous structures in the immediate vicinity of the tip of the FaceTite internal electrode. The RF energy then passes in a non-ablative fashion from the cannula up through the more superficial dermis up to the external electrode on the epidermal surface. The internal electrode moves slowly through the superficial sub-dermal fat, in tandem with external electrode sliding over the skin surface. Manual pressure on the spring-loaded connection between the internal and external electrodes controls the distance between them. Inside the external electrode are thermal sensors that constantly measure the epidermal temperature and “cut off” the RF energy when temperature exceeds the predetermined “safe” level. The system also measures and controls tissue impedance, delivering RF energy only when there is full contact of the external electrode with the skin. Further, as the subdermal temperature rises, the impedance will fall and if the fall is too precipitous, the system will shut off the RF energy before there is a burn. This exquisitely precise thermal and impedance control and automated RF “cut-off” allows sub-dermal treatment in the superficial fat without excessive risk of a deleterious thermal injury. The hand piece is attached directly to the platform and the treating physician can set the parameters of RF energy and “cut off” temperature as well as high and low internal tissue impedance to limit epidermal heating.

The majority of FaceTite procedures were conducted under local tumescent anesthesia and oral sedation, while some of the patients preferred IV sedation. All patients underwent subcutaneous infiltrative tumescent anesthesia

with a mixture of 1 bottle of 1% lidocaine in 500 ml of Ringers lactate and 1 ml of epinephrine 1:1000. Approximately 150 cc of infiltrate was used on the face and another 100 - 200 cc if the neck was treated. Prior to the super-wet tumescent anesthesia, Supra-orbital, Infra-orbital, Zygomatic-Facial and -Temporal, and Mental nerve blocks were performed with 10 cc of 1% xylocaine. Several patients also had the FaceTite procedure performed on lax body skin deploying exactly the same technique and parameters as used on the face.

In addition to reducing pain and bleeding, the tumescent anesthesia distends hypodermal adipose tissue, exposing a greater surface area of adipose tissue to the RF energy, increases thickness of sub-dermal space for safer maneuvering of the cannula between the dermis and the SMAS and makes skin surface of treatment area smoother for better contact with external electrode.

The face and neck area to be treated were divided into anatomical zones of approximately 10 × 10 cm or smaller, facilitating easy access from the same incision port operating cannula in the same direction. **Table 1** shows the average amount of tumescent and **Figure 2** shows a face with the typical FaceTite treatment zones. The thermal treatment for each zone is completed before moving on to the next area. The FaceTite hand piece is passed through the soft tissue to be tightened. The typical

Table 1. Typical amount of tumescent infiltration applied per zone.

Area	Amount of tumescent liquid, cc
Nasolabial Folds	30
Lower Face	40
Cheeks	50
Forehead	10
Neck	100



Figure 1. The FaceTite hand piece.

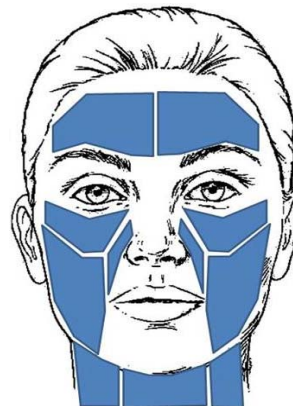

Figure 2. Face zones for FaceTite treatment.

treatment depth of the internal electrode on the face is 3 - 4 mm into the sub-dermal fat, or at the same level as you would elevate a subcutaneous skin flap during a rhytidectomy. It is very important that the operating surgeon not pass the internal electrode too deeply in the sub-dermal fat or there is the risk of the loss of facial fat and resulting depression, or injury to the facial nerve. The depth of treatment can be easily determined by passing the internal electrode under the skin and advancing it and before applying the RF energy, palpating the amount of sub-dermal tissue on top of the internal electrode. As there is containment of RF energy and generated heat between the two electrodes and no heat passing below the internal electrode, the deeper facial fat and facial nerve structures remain safe from a demyelinating neuropraxia, as long as the treating physician stays in the correct planes.

There are two treatment endpoint techniques performed sequentially in each zone: 1) the first pass is done with a "stamping" technique where the hand piece is held in one spot until there is an audible or palpable "popping sound". The average treatment time before the RF produces the "popping" sound, depending upon the fat and skin thickness, is 1 - 2 seconds and should not be longer than 3 seconds. This popping sound represents the RF coagulative necrosis of the adipose tissue immediately under the dermis. The internal electrode is passed without RF energy to the most distal aspect of each zone, the stamping technique is initiated and then the applicator is moved more proximally with 30% - 50% overlap of the external electrode with each new stamping location. In this fashion an entire line is treated and then the next line is initiated until the whole zone has been treated with the stamping technique. Once all the skin in the treatment zone has been treated with the "stamping" technique. 2) The FaceTite applicator is then passed slowly and continuously back and forth through the zone and already tunneled and "stamped" tissue until the epidermal temperature of 38°C - 42°C is achieved.

The hand piece is then moved to the next zone of treatment until all the lax skin has been treated. Achieving these two end points is critical to achieving the desired tightening effect. The FaceTite access ports are the brow pre-tracheal hair-line, commissures for the cheek, crow's feet for the lower lid, sub-lobular for the jaw-line and sub-mental for the neck (**Figure 3**). The lower supra-clavicular neck can be accessed via a low horizontal neck crease.

RF power settings depend on the anatomical area and skin thickness. The FaceTite is a superficial treatment device and more conservative power settings and lower cut-off temperatures are deployed than with RFAL. Typical treatment parameters for different anatomical area are shown in **Table 2** below.

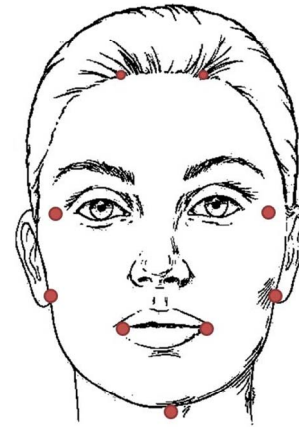


Figure 3. Optional access incision ports.

Table 2. Treatment parameters by zone.

Area	RF power, W	Cut-off temperature	Total amount of RF energy
Neck	12 - 15 W	38°C - 40°C	6 - 10 kJ
Nasolabial folds	10 - 12 W	38°C - 40°C	2 - 3 kJ
Lower face	10 - 12 W	38°C - 40°C	2 - 3 kJ
Cheeks	10 - 12 W	38°C - 40°C	2.5 - 3.5 kJ
Forehead and lower lids	10 W	38°C - 40°C	1 - 2 kJ

There is no aspiration used on the face. If FaceTite is performed in conjunction with RFAL on the neck, the RFAL is performed first and typical aspiration volume is 10 - 15 cc. After the procedure a compression wrap was applied over the jowls and neck area for 5 days. Significant post-operative swelling and bruising lasted for 5 - 7 days, at which point patients were presentable. Oral pain management was prescribed for the first two days after the surgery.

Three millimeter punch biopsies were taken from three patients to observe the thermal effect created by RF in different tissue layers.

A follow-up visit was scheduled 1 week after the treatment to observe the early clinical effects. Standard photographs were taken prior the treatment and 1, 3 and 6 months following the procedure. Patient satisfaction scores were recorded according to a standardized linear analog 5 point scale:

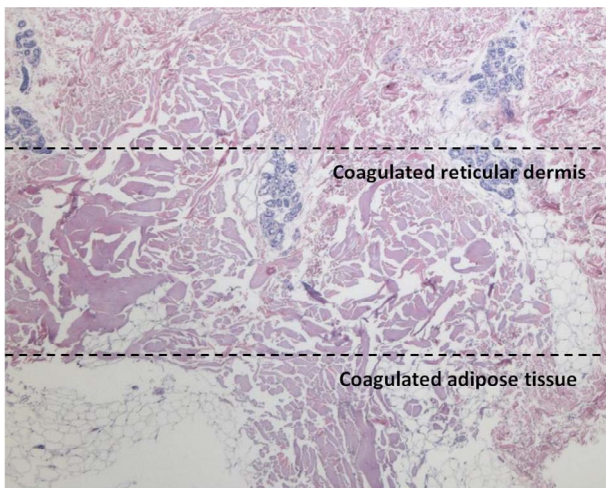
- Very satisfied (5)
- Somewhat satisfied (4)
- Neither satisfied nor dissatisfied (3)
- Somewhat dissatisfied (2)
- Very dissatisfied (1)

3. Results

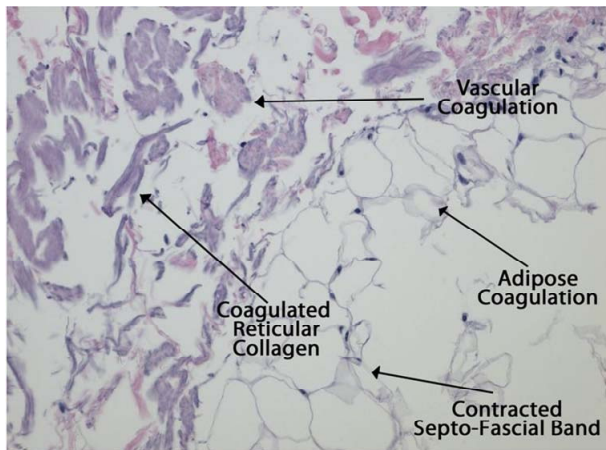
The histological images of treated tissue are presented in

Figures 4(a) and 4(b). There is a localized coagulative necrosis of the subcutaneous fat (lacunas and coagulated membranes are observed in sub-dermal space). The deep reticular dermis in the dermis-fat junction exhibited a clear, thermally induced collagen and fibrous tissue coagulation, as well as a non-coagulative thermal restructuring of the adjacent reticular dermis. **Figures 4(a) and 4(b)** also show the coagulative necrosis of the reticular dermal collagen fibers and sub-dermal coagulation of the adipocytes, small blood vessels as well as shrinkage of the fibrous septa.

Significant tightening of the brow and lower lid fat and malar pads was observed in all patients after resolution of the edema, beginning at 3 - 4 weeks following the treatment and the improvements continued over the next 6



(a)



(b)

Figure 4. (a) Controlled, localized coagulative necrosis of the reticular dermal collagen fibers, the sub-dermal adipocytes and fibrous septa; (b) Localized coagulative thermal necrosis of the hypodermal adipose tissue and deep reticular dermis.

months (**Figure 5**). Cheek, jaw line and neck enhancement and tightening were clinically apparent in all patients (**Figures 5-9**). **Figure 7** shows improvement in nasolabial folds at 3 months following the treatment. Patients experienced only mild discomfort post operatively, but edema and swelling was present for 5 - 7 days limiting social engagements for 1 full week. There were no burns or major complications and all patients were happy with the degree of tightening achieved with their FaceTite procedure. Skin type 4 and 5 patients experienced no post-inflammatory hyper-pigmentation and the small access scars were well hidden. The average overall patient score on the 5 point linear analog scale for aesthetic outcome was 4.6.

The FaceTite treatment was able to provide clinically significant tightening and lifting of the brow, lower lid, cheek, neck and body skin. The FaceTite procedure was also performed on several patients where there was lax body skin in combination with liposuction, with a similar skin tightening effect (**Figure 10**).

In an ongoing Vectra 3D study of RFAL contraction

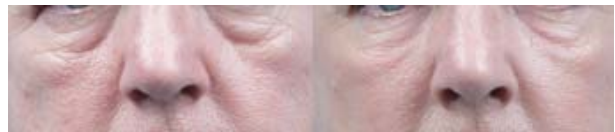

Figure 5. FaceTite of the brow, lower lids and cheeks. Left—before the treatment and right—6 months following the treatment. Photo courtesy S. Mulholland, MD.

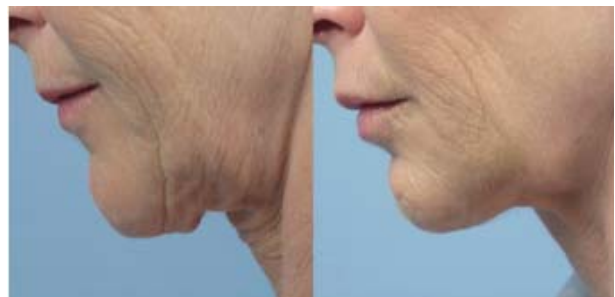

Figure 6. FaceTite of the cheek, jaw line and submentum. Left—before the treatment and right—6 months following the treatment. Photo courtesy S. Mulholland, MD.

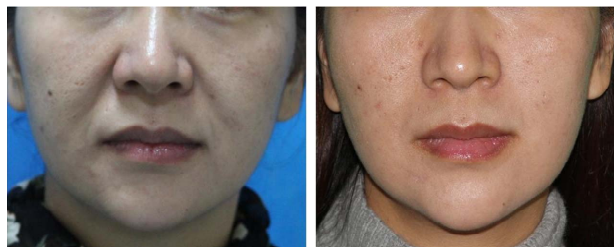


Figure 7. Full face treatment on Asian skin before (left) and after 3 months (right). Photo courtesy D. Ahn, MD.

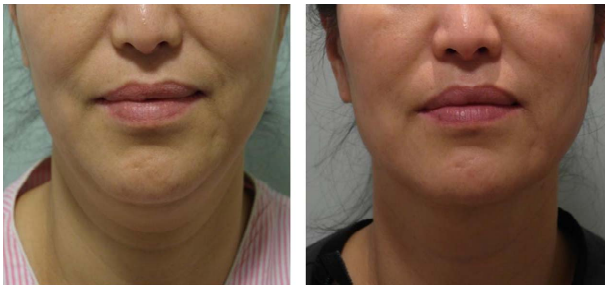

Figure 8. Full face and neck treatment on Asian skin before (left) and after 3 month (right). Photo courtesy D. Ahn, MD.

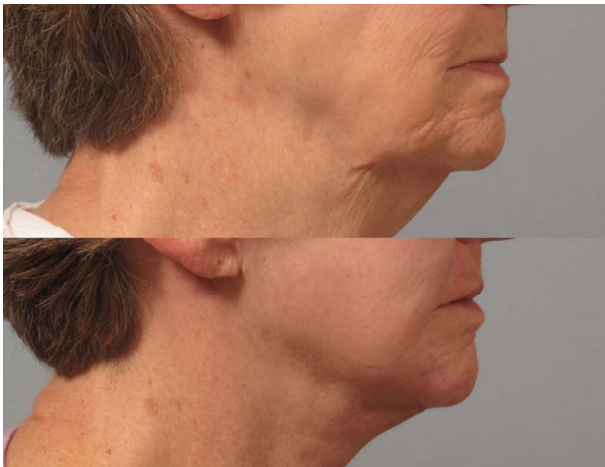

Figure 9. Face and neck treatment on an older patient for treatment in combination with a mini neck-lift. Above photo is before treatment and below photo is after 2 months. Photo courtesy D. Duncan, MD.

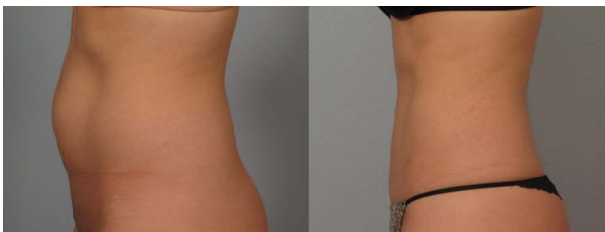


Figure 10. Female patient before treatment (right) requested results similar to a tummy tuck without scars. FaceTite was used for skin tightening and smoothing. RFAL followed by aspiration and a diastasis repair was performed and photographed after 2 months (left). No skin was excised. Photo courtesy D. Duncan, MD.

over lax abdominal skin, the range of skin contraction for RFAL was 13.4% to 56.6% at 6 weeks post-treatment, and 19.3% to 58.2% at one year [14]. Similar Vectra 3D studies for laser-assisted lipolysis showed a range of 3 month reduction at 9.1% to 17.3% [15,16] and for non-thermal suction-assisted lipoplasty 6% - 11% [14].

The applicator has skin thermal controls that are exquisitely auto regulated and ensure optimized thermal

safety with the proper training and deployment. Histology reveals a true localized, controlled coagulative necrosis of the sub-dermal fat layer and the deep reticular dermis with immediate tightening, followed by a secondary remodeling, neocollagenesis, neoelastosis and contraction over 6 months. To some degree, the non-ablative, sub-necrotic coagulation of the papillary dermis also contributes to the overall tightening effect. There was also a coagulative effect on hypodermal small blood vessels, which did not result in any instances of thermal necrosis, but substantially reduced the expected post-operative incidence of ecchymosis one would normally experience in a non-thermal surgical procedure.

4. Discussion and Conclusions

There is an obvious clinical need for a powerful, efficacious and safe skin tightening device like FaceTite, which also has potentially valuable applications as a stand alone skin tightening procedure, or in the pre-dissection of facelift flaps, the management of the central face zones with lateral lifting techniques, as well as minor anterior neck compartment re-do surgery for recurrent cervical laxity. The FaceTite may be combined synchronously with fractional resurfacing for an “inside out” and “outside in” thermal stimulation of the papillary and reticular dermis, as well as the hypodermal superficial adipose layer. The FaceTite was able to harness the contraction potential of the sub-dermal adipose-dermal interface through an audible and visible coagulative necrosis and the lower reticular dermis and very superficial adipose tissue. The thermal injury did tighten skin, did not disrupt the fasciocutaneous blood supply and was able to be performed well in lighter and darker skin types. It is shown that the bipolar radiofrequency sub-dermal coagulation results in an immediate tightening and then a strong deep dermal and sub-dermal neo-collagenesis and neo-elastosis with enhanced postoperative skin contour and elasticity. The sub-dermal RF coagulation does not improve superficial skin quality, dyschromia or texture and it is safe to combine the FaceTite procedure with intense pulses light and deep fractional skin resurfacing using CO₂ laser or fractional Radiofrequency skin resurfacing treatment.

REFERENCES

- [1] “Selected Characteristics of Baby Boomers 42 to 60 years Old in 2006,” US Census Bureau, Suitland, 16 November 2009.
- [2] “Skin Tightening: Softening Demand in a Weak Economy,” Medical Insight Inc., May 2008.
- [3] R. Fitzpatrick, R. Geronemus, D. Goldberg, M. Kaminer, S. Kilmer and J. Ruiz-Esparza, “Multicenter Study of Noninvasive Radiofrequency for Periorbital Tissue Tight-

- ening,” *Lasers in Surgery and Medicine*, Vol. 33, No. 4, 2003, pp. 232-242. [doi:10.1002/lsm.10225](https://doi.org/10.1002/lsm.10225)
- [4] H. J. Laubach, I. R. Makin, P. G. Barthe, M. H. Slayton and D. Manstein, “Intense Focused Ultrasound: Evaluation of a New Treatment Modality for Precise Microcoagulation within the Skin,” *Dermatologic Surgery*, Vol. 34, No. 5, 2008, pp. 727-734. [doi:10.1111/j.1524-4725.2008.34196.x](https://doi.org/10.1111/j.1524-4725.2008.34196.x)
- [5] N. Sadick, “Tissue Tightening Technologies: Fact or Fiction,” *Aesthetic Surgery Journal*, Vol. 28, No. 2, 2008, pp. 180-188. [doi:10.1016/j.asj.2007.12.009](https://doi.org/10.1016/j.asj.2007.12.009)
- [6] R. S. Mulholland, “Radio Frequency for Non-Invasive and Minimally Invasive Skin Tightening,” *Clinics in Plastic Surgery*, Vol. 38, No. 3, 2011, pp. 437-448. [doi:10.1016/j.cps.2011.05.003](https://doi.org/10.1016/j.cps.2011.05.003)
- [7] M. Paul and R. S. Mulholland, “A New Approach for Adipose Tissue Treatment and Body Contouring Using Radiofrequency Assisted Liposuction,” *Aesthetic Plastic Surgery*, Vol. 33, No. 5, 2009, pp. 687-694.
- [8] G. Blugerman, D. Schavelzon and M. Paul, “A Safety and Feasibility Study of a Novel Radiofrequency-Assisted Liposuction Technique,” *Plastic and Reconstructive Surgery*, Vol. 125, No. 3, 2010, pp. 998-1006. [doi:10.1097/PRS.0b013e3181ce1820](https://doi.org/10.1097/PRS.0b013e3181ce1820)
- [9] M. Paul, G. Blugerman, M. Kreindel and R. S. Mulholland, “Three-Dimensional Radiofrequency Tissue Tightening: A Proposed Mechanism and Applications for Body Contouring,” *Aesthetic Plastic Surgery*, Vol. 35, No. 1, 2010, pp. 87-95.
- [10] M. Kreindel and R. S. Mulholland, “Radiofrequency Energy,” *Body Language*, Vol. 23-24, 2009.
- [11] R. S. Mulholland, “An In-Depth Examination of Radiofrequency Assisted Liposuction (RFAL),” *Journal of Cosmetic Surgery & Medicine*, Vol. 4, 2009, pp. 14-18.
- [12] M. D. Paul, “Radiofrequency Assisted Liposuction Comes of Age: An Emerging Technology Offers an Exciting New Vista in Non-Excisional Body Contouring,” *Plastic Surgery Practice*, Vol. 2, 2009, pp. 18-19.
- [13] M. Paul, G. Blugerman, M. Kreindel and R. S. Mulholland, “Three-Dimensional Radiofrequency Tissue Tightening: A Proposed Mechanism and Applications for Body Contouring,” *Aesthetic Plastic Surgery*, Vol. 35, No. 1, 2011, pp. 87-95. [doi:10.1007/s00266-010-9564-0](https://doi.org/10.1007/s00266-010-9564-0)
- [14] D. Duncan, “Achieving Excellence in Upper Arm Contouring,” *International Master Course on Aging Skin*, 2011.
- [15] B. Dibernardo, “Evaluation of Skin Tightening with Smartlipo MPX,” *Cynosure*, 2008.
- [16] G. H. Sasaki, “Quantification of Human Abdominal Tissue Tightening and Contraction after Component Treatments with 1064-nm/1320-nm Laser-Assisted Lipolysis,” *Aesthetic Surgery Journal*, Vol. 30, No. 2, 2010, pp. 239-245. [doi:10.1177/1090820X10369373](https://doi.org/10.1177/1090820X10369373)