

In vivo relationship between the clinical epicondylar axis and the anterior pelvic plane in normal subjects

Norio Imai^{1*}, Tomoyuki Ito¹, Yasuhito Takahashi¹, Yoji Horigome¹, Ken Suda¹, Dai Miyasaka¹, Izumi Minato², Naoto Endo¹

¹Department of Orthopedic Surgery, Niigata University Dental and Medical Hospital, Niigata, Japan

²Department of Orthopedic Surgery, Niigata Rinko Hospital, Niigata, Japan

Email: *imainorio2001@yahoo.co.jp

Received 15 June 2013; revised 21 July 2013; accepted 5 August 2013

Copyright © 2013 Norio Imai *et al.* This is an open access article distributed under the Creative Commons Attribution License, which permits unrestricted use, distribution, and reproduction in any medium, provided the original work is properly cited.

ABSTRACT

Background: Several researchers consider the clinical epicondylar axis (CEA) as the functional flexion-extension axis of the knee. The anterior pelvic plane (APP) is commonly used as an anatomical reference plane of the pelvis. However, no study has investigated the relationship of the APP with the CEA and PCA. In this study, we aimed to investigate the relationship of the APP with the CEA and posterior condylar axis (PCA) in the standing and supine positions. **Methods:** We recruited 77 healthy Japanese subjects for this study, and carried out measurements using the Hip CAS[®] system, a 3D system used for the assessment of lower extremity alignment. **Results:** The mean femoral neck anteversion was 16.33°. There was an approximate discrepancy of 6° between the male and the female in anatomy (15.73° and 21.15° in the male and female subjects, respectively). The mean condylar twist angle (CTA) was 6.86° and the mean APP-PCA value in the standing position was -6.88°. The mean APP-CEA value in the standing position was 0.02°, and the discrepancy between males and females was only 0.21° (0.09° and -0.13° for the male and female subjects, respectively). This meant that Xp axis of APP and CEA were almost parallel. On the other hand, the mean APP-CEA value in the supine position was 7.07° (male subjects = 9.48°; female subjects = 5.62°). Here, the CEA was approximately parallel to the horizontal axis of the APP, which was compatible with the neutral position of the knee and hip joint, and anatomically and kinesiology justified in normal subjects. **Conclusion:** CEA was approximately parallel to the horizontal axis of the APP. These results are compatible with regard to the neutral position of the knee and hip joints, and anatomi-

cally and kinesiology justified in normal subjects. Moreover, CEA is a potential reference axis for the insertion of the femoral component in THA.

Keywords: Anterior Pelvic Plane; Posterior Condylar Axis; Clinical Epicondylar Axis; Hip CAS System

1. INTRODUCTION

Several studies have reported that clinical epicondylar axis (CEA), which is a line connecting the medial and lateral epicondylar prominence, is externally rotated by approximately 6° from the posterior condylar axis (PCA) [1-3]. Further, the CEA is considered to be the functional flexion-extension axis of the knee [1,2].

The anterior pelvic plane (APP) or the Lewinnek plane is defined by bilateral anterior superior iliac spines and the superior margin of the pubis symphysis. This plane is commonly used as an anatomical reference plane of the pelvis [4], particularly when performing computer-assisted prosthetic hip surgery [4-7]. However, no study has investigated the relationship of the APP with the CEA and PCA. Therefore, in this study, we investigated the relationship between APP and CEA and between APP and PCA in normal subjects in standing and supine positions.

2. MATERIALS AND METHODS

2.1. Subjects

For this study, we recruited 77 healthy Japanese volunteers without low back pain and knee pain and without any abnormalities on X-ray examination. There were 26 male and 51 female participants, and their details are depicted in **Table 1**. The Institutional Research Board at Niigata University Medical and Dental Hospital approved the study and informed consent was obtained

*Corresponding author.

Table 1. Details of the patients.

	Male (n = 26)	Female (n = 51)
Years	51.8 ± 10.6 (35 - 76)	54.2 ± 11.2 (35 - 80)
Body height (cm)	167.3 ± 6.3 (156 - 180)	152.8 ± 5.8 (145 - 173)
Body weight (kg)	63.7 ± 9.5 (44 - 86)	52.1 ± 7.4 (38 - 72)
BMI	22.7 ± 2.5 (17 - 26.7)	22.3 ± 2.8 (16.6 - 29.7)

from this patient.

Radiographic data were collected in standing position, where each subject adopted a comfortable position with the knees fully extended and the toes positioned in a comfortable position with shoulder width, and the supine position, where subjects lay supine with the knees fully extended and the toes positioned in a comfortable position with shoulder width and their hands on the stomach.

2.2. Hip CAS System and Measurements

The use of the Hip CAS[®], a 3D system used for the assessment of lower extremity alignment, has been described previously by several researchers [8-10]. We measured the pelvic flexion angle defined by the angle between the Yp axis of the pelvic coordinate system and the CT table in the supine position and that between the Yp axis of the pelvic coordinate system and the plane perpendicular to the floor in the standing position. The anterior orientation of the Yp axis was defined as flexion (positive angle), the posterior orientation was defined as extension (negative angle), and the neutral position (0°) was defined when this axis was perpendicular to the CT table or the floor.

Femoral neck anteversion (FNA), PCA, and CEA were measured in the tabletop coordination system [11]. For this purpose, the three-dimensional model was positioned with the table plane coincident with the posterior condyles and the most prominent posterior point of the greater trochanter.

The femoral neck axis in this study was as defined by Sugano *et al.* [12], which was measured by describing 3 circles on the femoral neck just below the femoral head tangent to the anterior and posterior margin of the femoral neck. The definitions of the 3 circles are as follows: first, a circle was described at almost the neck-shaft junction. Next, the line from center of this circle to the proximal end of femoral neck was approximately divided into 3 parts. Two more circles were described on approximately 1/3 and 2/3 points, respectively. The femoral neck axis was defined by the line connecting the centers of these 3 circles (**Figure 1**). FNA was defined as the angle connecting the femoral neck axis and the PCA (**Figure 2**).

Further, the condylar twist angle (CTA) was measured

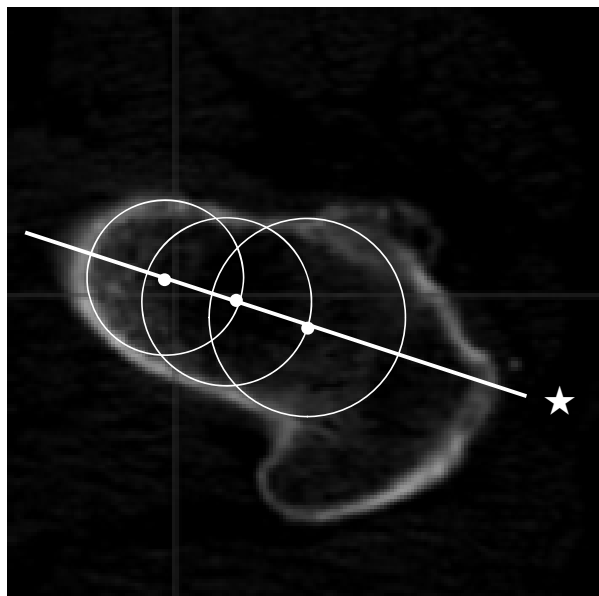


Figure 1. Femoral neck axis. The femoral neck axis (☆) was defined as the line connecting the centers of the 3 circles described into the femoral neck.

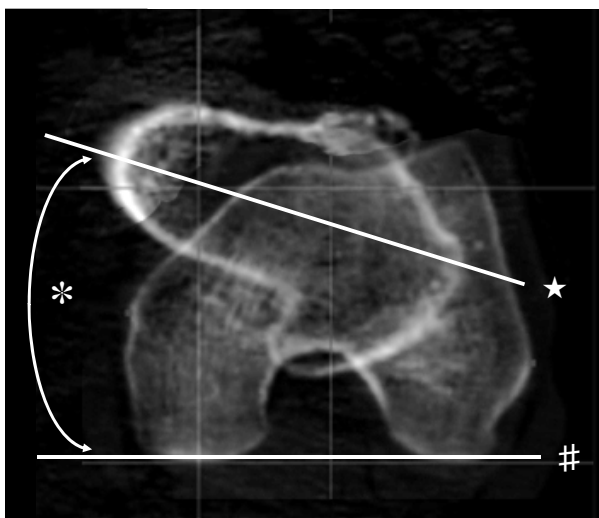


Figure 2. Measurement of FNA. FNA (*) is the angle between the femoral neck axis (☆) and the PCA (#).

as the angle between the PCA and CEA (positive external rotation) (**Figure 3**). The CEA was determined and the CTA was also measured in the tabletop plane.

Lastly, CEA relative to APP (APP-CEA) and PCA relative to APP (APP-PCA) were measured. APP-CEA was the angle that connected the CEA projected on the XYp plane and Xp axis. APP-PCA was the angle that connected the PCA projected on the XYp plane and Xp axis (**Figure 4**).

2.3. Reliability

All the images were measured by 2 investigators (N.I.

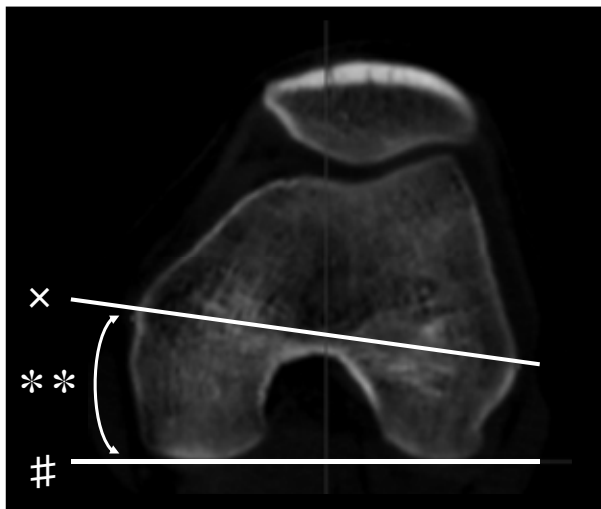


Figure 3. Measurement of CTA. CTA (***) is the angle between the CEA (x) and the PCA (#). This figure shows a stack of two planes, one is just below the femoral head and the other is the plane of distal femur.

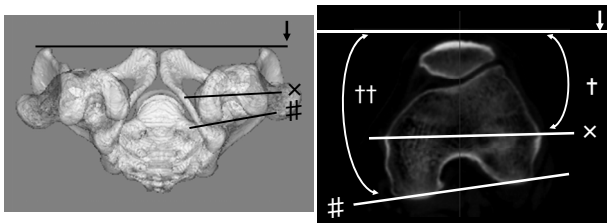


Figure 4. Measurement of APP-PCA and APP-CEA. APP-CEA (†) and APP-PCA (††) were defined as the angle connecting the CEA (x) and PCA (#) lines projected on the XY plane of APP and Xp axis (↓), respectively.

and Y.T.), and the final readings were arrived at by consensus. One investigator (N.I.) assessed the intraobserver variations. The angular measurements of all the inspection items were repeated 10 times every 2 days in 25 randomly selected subjects. Interobserver variations were assessed by the above mentioned investigators, who repeated the 3 angular measurements.

2.4. Statistical Analysis

SPSS statistical software (SPSS, Inc., Chicago, IL) was used for the statistical analysis. Intraobserver reliability was calculated using interclass correlation and interobserver reliability was calculated using Pearson's coefficients. Data were analyzed using Student's t test. A p value of <0.05 was considered statistically significant.

3. RESULTS

The mean value of APP in 77 subjects was $-2.08 \pm 5.55^\circ$ (mean \pm SD) in standing position and $4.18 \pm 6.37^\circ$ in supine position (**Table 2**). There was a significant dif-

Table 2. Measurements.

	Total (n = 77)	Male (n = 26)	Female (n = 51)
APP (standing position)	-2.08 ± 5.55 (-17.2 – 6.7)	-0.97 ± 4.73 (-13.1 – 6.7)	-2.66 ± 5.81 (-17.2 – 6.4)
APP (supine position)	4.18 ± 6.37 (-8.8 – 18.7)	5.10 ± 6.77 (-8.0 – 15.0)	3.71 ± 5.93 (-8.8 – 18.7)
FNA	19.33 ± 8.47 (-4.7 – 37.4)	15.73 ± 9.29 (-4.7 – 29.6)	21.15 ± 7.46 (1.1 – 37.4)
CTA	6.86 ± 1.34 (3.9 – 9.5)	6.26 ± 1.17 (3.9 – 8.3)	7.16 ± 1.35 (4.1 – 9.5)
APP-PCA (standing position)	-6.88 ± 4.24 (-15.0 – 6.9)	-6.17 ± 3.50 (-12.4 – 6.96)	-7.24 ± 4.60 (-15 – 5.0)
APP-PCA (supine position)	0.22 ± 7.15 (-10.8 – 18.8)	3.22 ± 6.86 (-8 – 18.8)	-1.54 ± 6.67 (-10.8 – 17.5)
APP-CEA (standing position)	-0.02 ± 3.93 (-7.7 – 11.4)	0.09 ± 3.45 (-5.45 – 9.62)	-0.13 ± 4.21 (-7.7 – 11.4)
APP-CEA (supine position)	7.07 ± 6.78 (-4.8 – 24.9)	9.48 ± 6.26 (-0.9 – 24.9)	5.62 ± 6.62 (-4.8 – 17.5)

APP: anterior pelvic plane, FNA: femoral neck anteversion, CTA: condylar twist angle, the angle between clinical epicondylar axis and posterior condylar axis, APP-PCA: posterior condylar axis relative to anterior pelvic plane, APP-CEA: clinical condylar axis relative to anterior pelvic plane.

ference between the APP values in standing and supine position ($p < 0.001$). The mean femoral neck anteversion was $19.33^\circ \pm 8.47^\circ$ and there was an approximate discrepancy of 6° in the anatomy of male and female subjects (15.73° in the male and 21.15° in the female subjects, $p = 0.013$) (**Table 2**). The total CTA was $6.86^\circ \pm 1.34^\circ$ and the mean angle was 6.26° and 7.16° in male and female subjects, respectively (**Table 2**). A discrepancy of 0.9° was observed between the male and the female subjects ($p = 0.003$).

APP-PCA, which is the angle that connected the PCA projected on the XYp plane and Xp axis, was measured for each of the subjects as shown in **Figure 3**. The mean APP-PCA value was $-6.88^\circ \pm 4.24^\circ$ in standing position and $-0.22^\circ \pm 7.15^\circ$ in supine position. The mean angle was -6.17° and -7.24° in the male and female subjects, respectively, in the standing position ($p = 0.258$), and 3.22° and -1.54° , respectively, in the supine position ($p = 0.007$) (**Table 2**).

The mean APP-CEA value in the standing position was 0.02° (male subjects = 0.09° ; female subjects = -0.13°) (**Table 2**). The observed discrepancy was only 0.21° ($p = 0.853$). Moreover, since these values were close to zero, it meant Xp axis of APP and CEA were almost parallel and there was no significant difference between male and female subjects. On the other hand, mean APP-CEA value in supine position was 7.07° , with 9.48° and 5.62° being the values observed in the male and female subjects, respectively ($p = 0.023$) (**Table 2**). Further, a significant difference was observed between the standing and supine position ($p < 0.001$).

All measurements exhibited good reproducibility showing high interclass correlation and Pearson's coefficients. The maximum intraobserver difference between measurements was 3.3° , and the largest standard deviation was 1.68° (intraclass correlation: 0.959), which was observed in the FNA measurement. The maximum interobserver difference between measurements was 3.4° , and the largest standard deviation was 1.73° ($r = 0.996$ by the Pearson's correlation test; $p < 0.001$), which was also observed in the FNA measurement.

4. DISCUSSION

In this study, we have tried to elucidate the relationship between the clinical epicondylar axis and the anterior pelvic plane in normal healthy subjects. Previously, Aka-gi *et al.* have demonstrated that the anteroposterior axis of the distal femur, which is defined by a line through the deepest part of the patellar groove anteriorly and the center of the intercondylar notch posteriorly, was almost at right angles to the clinical epicondylar axis, and the relationship between these axes was constant [13]. Churchill *et al.* [1] and James *et al.* [14] argued that anatomically, the CEA was related to the transverse flexion axis of knee rotation and was perpendicular to the mechanical axis of the lower extremity. Furthermore, these investigators reported that CTA was almost 6° in both men and women [1,13,14]. These values are similar to our result, which was 6.26° and 7.16° in male and female subjects who did not show any abnormality in the knee joint on X-ray examination, while femoral neck anteversion demonstrated an approximate discrepancy of 6° in the anatomy of male and female subjects.

Moreover, with regard to FNA, Sugano *et al.* [12] reported that average FNA was 16.9° in male and 22.6° in female suffered from idiopathic osteonecrosis of femoral head or rheumatoid arthritis without deformity of femoral head of Japanese patients. Argenson *et al.* [15] demonstrated that average FNA was 22.9° in Caucasian patients of primary osteoarthritis. In this current study, we used only Japanese healthy subjects. Our data were similar to these reports, therefore, the results in our study, 15.73° in the male and 21.15° in the female subjects, were considered as appropriate.

The anterior pelvic plane is determined by 3 reference points: the 2 anterosuperior iliac spines and the anterior surface of the pubic symphysis. In 1922, Robinson *et al.* first described the anterior pelvic plane as the pelvic frontal plane [16]. In 1978, Lewinnek *et al.* used a special positional jig for conventional radiographs that defined the anterior pelvic plane to measure the inclination and anteversion of the cup [4]. Jaramaz *et al.* [6] used the anterior pelvic plane to determine computer-assisted cup placement in THA. Pelvic position is not static; rather, it is dynamic during gait and other daily activities, and

some researchers have measured these different positions [5,16]. Pelvic flexion has been reported to range from -2° to -4° in the standing position, which is similar to our observation of -2.08° . This meant that it was neither perpendicular to the floor in the standing position, nor parallel to the coronal plane [17-19]. Wan *et al.* identified that only 9% of 619 hips studied had no anteroposterior tilt in the supine position [20]. However, it is known that the pelvis is almost symmetrical in the sagittal plane and it moves in symmetry in flexion and extension relative to the sagittal plane [21]; in internal and external rotation, it moves symmetrically relative to the horizontal plane [22,23]; and in abduction and adduction, it moves symmetrically relative to frontal plane [22,23] in normal gait. Previous studies have also shown that the second metatarsal bone axis was externally rotated to the median line when normal objects stepped forward in normal gait [24,25]. Moreover, the mean angle between the line perpendicular to the transepicondylar axis and the second metatarsus bone axis was shown to externally rotate by approximately 5° [13]. Thus, it was considered that the second metatarsus bone axis in the standing position was parallel to that in normal gait. Therefore, the horizontal axis of the APP is considered one of the functional axes of the pelvis and hip joint.

CEA and APP were considered functional axis of knee and hip joints, respectively. Though they are adjacent joints, there are no other studies that consider the relationship of these axes. In this current study, we found that CEA and APP functional axes of knee and hip joint were almost parallel, but unrelated. This new concept seems to agree with the reports about CEA [1,13,14] and APP [22-25]. Further, it may be important to integrate these two functional axes with regard to the kinesiology of lower extremity.

Moreover, Yoshioka *et al.* identified the interspecimen variability of the posterior condylar axis in comparison with CEA and concluded that the relation of the posterior axis and the mechanical and anatomical axis is less reliable and this may lead to inaccuracies, particularly in the case of severe deformity at the distal end of the knee due to osteoarthritis or rheumatoid arthritis [26]. Thus, in such cases, CEA may be used as a reference axis for the measurement of femoral neck anteversion and implant insertion or planning of the femoral component in total hip arthroplasty (THA), for which currently the PCA is referred. Our data suggest that CEA could be used as a reference axis of the femoral component even in the case of no severe deformity at the distal end of the knee.

In this study, CEA was approximately parallel to the horizontal axis of the APP. These results are compatible with regard to the neutral position of the knee and hip joints, and anatomically and kinesiologically justified in normal subjects. Moreover, CEA is a potential reference

axis for the insertion of the femoral component in THA.

REFERENCES

- [1] Churchill, D.L., Incavo, S.J., Johnson, C.C. and Beynon, B.D. (1998) The transepicondylar axis approximates the optimal flexion axis of the knee. *Clinical Orthopaedics and Related Research*, **56**, 111-118. [doi:10.1097/00003086-199811000-00016](https://doi.org/10.1097/00003086-199811000-00016)
- [2] Johal, P., Williams, A., Wragg, P., Hunt, D. and Gedroyc, W. (2005) Tibio-femoral movement in the living knee. A study of weight bearing and non-weight bearing knee kinematics using "interventional" MRI. *Journal of Biomechanics*, **38**, 269-276. [doi:10.1016/j.jbiomech.2004.02.008](https://doi.org/10.1016/j.jbiomech.2004.02.008)
- [3] Aglietti, P., Sensi, L., Cuomo, P. and Ciardullo, A. (2008) Rotational position of femoral and tibial components in TKA using the femoral transepicondylar axis. *Clinical Orthopaedics and Related Research*, **466**, 2751-2755. [doi:10.1007/s11999-008-0452-8](https://doi.org/10.1007/s11999-008-0452-8)
- [4] Lewinnek, G.E., Lewis, J.L., Tarr, R., Compere, C.L. and Zimmerman, J.R. (1978) Dislocations after total hip-replacement arthroplasties. *The Journal of Bone & Joint Surgery*, **60**, 217-220.
- [5] Nishihara, S., Sugano, N., Nishii, T., Ohzono, K. and Yoshikawa, H. (2003) Measurements of pelvic flexion angle using three-dimensional computed tomography. *Clinical Orthopaedics and Related Research*, **41**, 140-151. [doi:10.1097/01.blo.0000069891.31220.fd](https://doi.org/10.1097/01.blo.0000069891.31220.fd)
- [6] Jaramaz, B., DiGioia, A.M. 3rd, Blackwell, M. and Nikou, C. (1998) Computer assisted measurement of cup placement in total hip replacement. *Clinical Orthopaedics and Related Research*, **354**, 70-81. [doi:10.1097/00003086-199809000-00010](https://doi.org/10.1097/00003086-199809000-00010)
- [7] Philippot, R., Wegrzyn, J., Farizon, F. and Fessy, M.H. (2009) Pelvic balance in sagittal and Lewinnek reference planes in the standing, supine and sitting positions. *Orthopaedics & Traumatology: Surgery & Research*, **95**, 70-76.
- [8] Sato, T., Koga, Y. and Omori, G. (2004) Three-dimensional lower extremity alignment assessment system: Application to evaluation of component position after total knee arthroplasty. *The Journal of Arthroplasty*, **19**, 620-628. [doi:10.1016/j.arth.2003.12.063](https://doi.org/10.1016/j.arth.2003.12.063)
- [9] Kobayashi, K., Sakamoto, M., Tanabe, Y., Ariumi, A., Sato, T., Omori, G. and Koga, Y. (2009) Automated image registration for assessing three-dimensional alignment of entire lower extremity and implant position using bi-plane radiography. *Journal of Biomechanics*, **42**, 2818-2822. [doi:10.1016/j.jbiomech.2009.08.022](https://doi.org/10.1016/j.jbiomech.2009.08.022)
- [10] Ariumi, A., Sato, T., Kobayashi, K., Koga, Y., Omori, G., Minato, I. and Endo N. (2010) Three-dimensional lower extremity alignment in the weight-bearing standing position in healthy elderly subjects. *Journal of Orthopaedic Science*, **15**, 64-70. [doi:10.1007/s00776-009-1414-z](https://doi.org/10.1007/s00776-009-1414-z)
- [11] Kingsley, P.C. and Olmsted, K.L. (1948) A study to determine the angle of anteversion of the neck of the femur. *The Journal of Bone & Joint Surgery*, **30**, 745-751.
- [12] Sugano, N., Noble, P.C. and Kamaric, E. (1998) A comparison of alternative methods of measuring femoral anteversion. *Journal of Computer Assisted Tomography*, **22**, 610-614. [doi:10.1097/00004728-199807000-00019](https://doi.org/10.1097/00004728-199807000-00019)
- [13] Akagi, M., Mori, S., Nishimura, S., Asano, T. and Hamanishi, C. (2005) Variability of extraarticular tibial rotation references for total knee arthroplasty. *Clinical Orthopaedics and Related Research*, **436**, 172-176. [doi:10.1097/01.blo.0000160027.52481.32](https://doi.org/10.1097/01.blo.0000160027.52481.32)
- [14] Stiehl, J.B. and Abbott, B.D. (1995) Morphology of the transepicondylar axis and its application in primary and revision total knee arthroplasty. *The Journal of Arthroplasty*, **10**, 785-789. [doi:10.1016/S0883-5403\(05\)80075-0](https://doi.org/10.1016/S0883-5403(05)80075-0)
- [15] Argenson, J.N., Flecher, X., Parratte, S. and Aubaniac, J. (2007) Anatomy of the dysplastic hip and consequences for total hip arthroplasty. *Clinical Orthopaedics and Related Research*, **465**, 40-45.
- [16] Babisch, J.W., Layher, F. and Amiot, L.P. (2008) The rationale for tilt-adjusted acetabular cup navigation. *The Journal of Bone & Joint Surgery*, **90**, 357-365. [doi:10.2106/JBJS.F.00628](https://doi.org/10.2106/JBJS.F.00628)
- [17] Pinoit, Y., May, O., Girard, J., Laffargue, P., Ala, Eddine, T. and Migaud, H. (2007) Low accuracy of the anterior pelvic plane to guide the position of the cup with imageless computer assistance: Variation of position in 106 patients. *Revue de Chirurgie Orthopédique et Réparatrice de l'Appareil Moteur*, **93**, 455-460. [doi:10.1016/S0035-1040\(07\)90327-X](https://doi.org/10.1016/S0035-1040(07)90327-X)
- [18] Wolf, A., Digioia, A.M. 3rd, Mor, A.B. and Jaramaz, B. (2005) A kinematic model for calculating cup alignment error during total hip arthroplasty. *Journal of Biomechanics*, **38**, 2257-2265. [doi:10.1016/S0035-1040\(07\)90327-X](https://doi.org/10.1016/S0035-1040(07)90327-X)
- [19] Blendea, S., Eckman, K., Jaramaz, B., Levison, T.J. and Digioia, A.M. 3rd (2005) Measurements of acetabular cup position and pelvic spatial orientation after total hip arthroplasty using computed tomography/radiography matching. *Computer Aided Surgery*, **10**, 37-43.
- [20] Wan, Z., Malik, A., Jaramaz, B., Chao, L. and Dorr, L.D. (2009) Imaging and navigation measurement of acetabular component position in THA. *Clinical Orthopaedics and Related Research*, **467**, 32-42. [doi:10.1007/s11999-008-0597-5](https://doi.org/10.1007/s11999-008-0597-5)
- [21] Whittington, B., Silder, A., Heiderscheit, B. and Thelen, D.G. (2008) The contribution of passive-elastic mechanisms to lower extremity joint kinetics during human walking. *Gait & Posture*, **27**, 628-634. [doi:10.1007/s11999-008-0597-5](https://doi.org/10.1007/s11999-008-0597-5)
- [22] Chumanov, E.S., Wall-Scheffler, C. and Heiderscheit, B.C. (2008) Gender differences in walking and running on level and inclined surfaces. *Clinical Biomechanics*, **23**, 1260-1268. [doi:10.1016/j.clinbiomech.2008.07.011](https://doi.org/10.1016/j.clinbiomech.2008.07.011)
- [23] Schache, A.G. and Baker, R. (2007) On the expression of joint moments during gait. *Gait & Posture*, **25**, 440-452. [doi:10.1016/j.gaitpost.2006.05.018](https://doi.org/10.1016/j.gaitpost.2006.05.018)
- [24] Chan, C.W. and Rudins, A. (1994) Foot biomechanics during walking and running. *Mayo Clinic Proceedings*, **69**, 448-461. [doi:10.1016/S0025-6196\(12\)61642-5](https://doi.org/10.1016/S0025-6196(12)61642-5)

- [25] Guy, G. (2010) Kinesiology of walking. In: Neumann, D.A., Ed., *Kinesiology of the Musculoskeletal System*, 2nd Edition, Mosby Elsevier, Inc., St. Louis, 627-681.
- [26] Yoshioka, Y., Siu, D.W., Scudamore, R.A. and Cooke, T.D. (1989) Tibial anatomy and functional axes. *Journal of Orthopaedic Research*, **7**, 132-137.
[doi:10.1002/jor.1100070118](https://doi.org/10.1002/jor.1100070118)