

Spinal Decompression with 360° Instrumented Fusion for Unstable Tuberculous Quadriplegia in a Young Adult—A Case Report

A. Abiodun Adeleke^{1,2*}, E. O. Komolafe³, O. A. Dada³, O. F. Owagbemi³

¹Department of Orthopaedics and Traumatology, Obafemi Awolowo University Teaching Hospitals Complex, Ile-Ife, Nigeria

²Department of Anatomy and Cell Biology, Faculty of Basic Medical Sciences, Obafemi Awolowo University, Ile-Ife, Nigeria

³Neurosurgery Unit, Department of Surgery, Obafemi Awolowo University Teaching Hospitals Complex, Ile-Ife, Nigeria

Email: *aaabiodun76@yahoo.com

Received 11 June 2015; accepted 18 August 2015; published 21 August 2015

Copyright © 2015 by authors and Scientific Research Publishing Inc.

This work is licensed under the Creative Commons Attribution International License (CC BY).

<http://creativecommons.org/licenses/by/4.0/>



Open Access

Abstract

Background: Tuberculosis of the spine is common in Nigeria. It commonly causes neurological deficit especially when the lesions are higher up in the spine. **Objective:** To report a case of a young man who had C4 quadriplegia from tuberculous destruction of C3 to C5 vertebral bodies and their intervening discs, aretropharyngeal prevertebral abscess and associated segmental kyphosis. He had received prior antituberculous therapy with no improvement. **Results:** He recovered completely neurologically when he had adequate decompression and 360° instrumented fusion done in a 3-stage surgery that involved drainage and debridement of the retropharyngeal prevertebral abscess, anterior corpectomy of C3 and C4 with fusion using a titanium mesh cage, and posterior fusion of C3 to C6 using titanium rods and lateral mass screws. Surgical treatment was supported with skull traction and antituberculous therapy. **Conclusion:** This case shows that complete neurologic recovery is feasible in spinal quadriplegia that fails to respond to antituberculous therapy when adequate decompression and fusion are done.

Keywords

Spinal, Tuberculosis, Decompression, Fusion, Recovery

*Corresponding author.

1. Introduction

Tuberculosis of the spine has been recognized since as far back as 100-300 BC when Hippocrates first described the disease [1]. Also known as Pott's disease [2] and tuberculous spondylitis, the incidence of the condition varies throughout the world [3], being common in Nigeria [4]. The cervical spine is less affected than the thoracic, thoracolumbar and lumbar spine [1] [5]. Neurological deficits are a common complication of the disease with the frequency increasing with higher lesions [1] [3] [6]. Decompressive surgery along with antituberculous therapy is the best mode of treatment for the disease [7], though patients with no or minimal neurological deficit are known to have been managed non-surgically [8]. This report highlighted the case of a young man who had tuberculous quadriplegia.

2. Case Report

A 27-year-old male unemployed university graduate was referred from a State Specialist Hospital. He presented to the neurologist with insidious dull aching non-radiating progressive neck pain associated with low grade fever and night sweats of 18 months, and progressive weakness and paraesthesia in all limbs. He had become quadriplegic 6 months before presentation. He had no sphincteric or erectile dysfunction, nor did he have cough or history of ingestion of unpasteurized milk. He had antituberculous therapy and conservative treatment in various hospitals but his condition continued to deteriorate. He also had no past medical, drug, family and social history of note, and no additional symptoms on systemic review.

He looked chronically ill, was anicteric, acyanosed, and had neither digital clubbing nor peripheral lymph node enlargement. His vital signs were normal. He had reduced muscle bulk globally, spastic quadriplegia, a T1 sensory level and tenderness at the cervical spine. His other body regions were essentially normal.

His full blood count, electrolytes, urea and creatinine were within normal limits. His erythrocyte sedimentation rate was 40 mm/hr using the Westergren method. Plain cervical spine X-ray (**Figure 1**) showed destruction of C3 to C5 vertebral bodies and their intervening discs as well as segmental kyphosis. A Magnetic Resonance Imaging scan of his cervical spine (**Figure 2**) further showed a retropharyngeal prevertebral abscess.

A working diagnosis of C4 quadriplegia secondary to an extradural cervical cord compression from Pott's

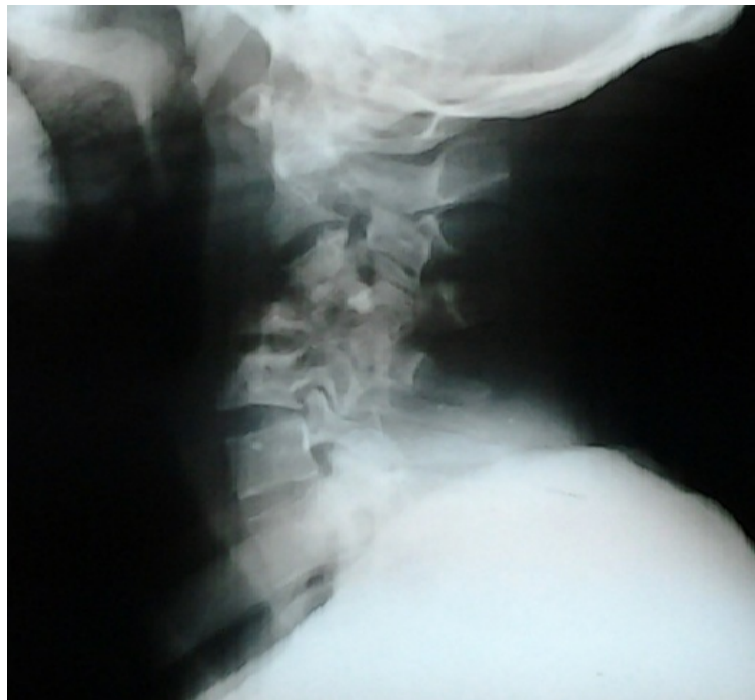

Figure 1. Plain cervical spine X-ray of the patient showing collapsed vertebral bodies of C3 to C5 with destruction of their intervening discs, and segmental kyphosis.

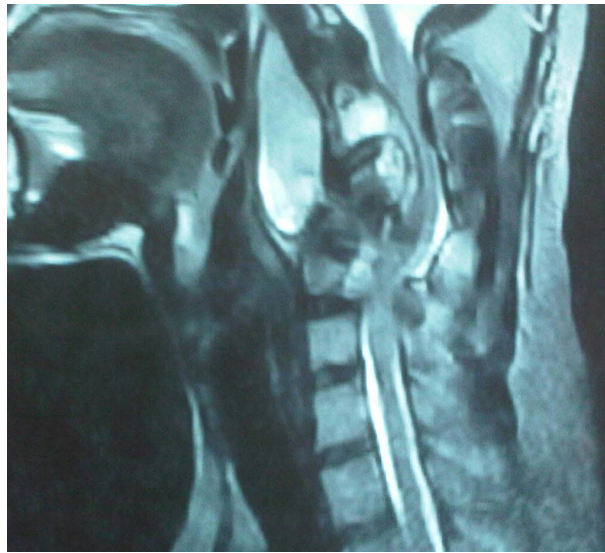


Figure 2. Magnetic Resonance Imaging scan of the patient's cervical spine showing a retropharyngeal prevertebral collection, C3 to C5 vertebral body destruction and local kyphosis.

disease was made. He was continued on antituberculous therapy along with a rigid cervical collar by the neurologist. A spine surgery consultation was then requested. He was initially placed on skull traction using Gardner Wells tongs and had other supportive care with some improvement of the power in all his limbs.

He was managed with a 3-stage surgery that involved drainage and debridement of the retropharyngeal prevertebral abscess as the 1st stage and anterior corpectomy of C3 and C4 with fusion using a titanium mesh cage as the 2nd stage (**Figure 3**). Spine stability was maintained between the 1st and 2nd stages using skull traction. Following this, he recovered completely neurologically, and a 3rd stage procedure—posterior instrumented fusion of C3 to C6 using titanium rods and lateral mass screws—was done, completing a 360° fusion (**Figures 4-6**). **Figure 7** shows the patient and displays his surgical scars. He also continued the antituberculous therapy for 12 months and is being followed up at the surgical outpatient department. No organisms were detected in specimens taken. Histopathology report showed tissue with extensive area of necrosis and islands of diffuse granuloma composed of epithelial cells with cuff of lymphocytes and plasma cell. The patient has remained well with neurological recovery sustained and is displayed in **Figure 8**, playing a football.

3. Discussion

Tuberculosis is the most common granulomatous spine infection worldwide [3] and was described by Sir Percivall Pott (after whom Pott's disease is named) in 1779 as a cause of paraplegia [2]. The disease mostly affects adults [9] but may also affect children and adolescents [10]. It has also been reported in a 3-month-old child [11]. Haematogenous spread from primarily infected organs is the most common route of spread to the spine [12], though spread may also be from contiguous skeletal lesions and may be a direct extension from visceral lesions [3]. The vertebral body is more commonly affected than the posterior elements [7] [13], leading to kyphosis if there is bone collapse. This affection of the anterior elements is usually an extension of the abscess beneath the anterior longitudinal ligament and periosteum [12]. Spinal tuberculosis is the commonest cause of kyphosis in many parts of the world and this kyphosis tends to be the rule rather than the exception [1] [14]. The posterior elements of the spine may also be affected [15] and isolated spinous process and laminae involvement have been reported [16].

Back pain and neurological deficits are common features of the disease [6] [9] [14] [15]. Involvement of the cervical spine results in quadriparesis or quadriplegia whereas, thoracic and thoracolumbar spine disease result in paraparesis or paraplegia [1]. Hemiparesis resulting from cervical spine involvement has also been reported [17]. Other clinical features include spine deformities, fever, weight loss and night sweats [9] [18] [19].

Imaging of the spine is an essential part of investigation in Pott's disease. Possible findings include destruct

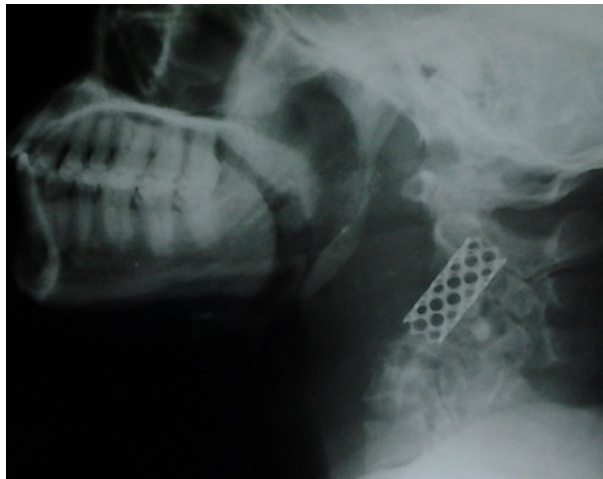

Figure 3. Plain cervical spine X-ray following the 2nd stage.

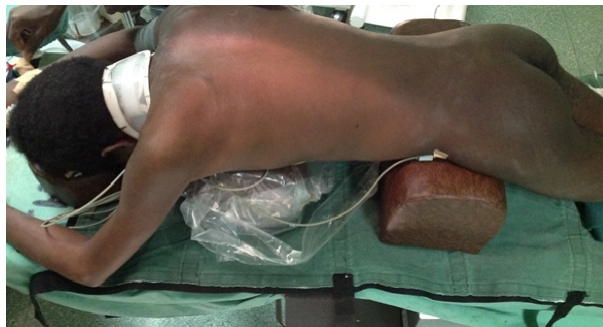

Figure 4. Patient positioned prone for posterior surgery.

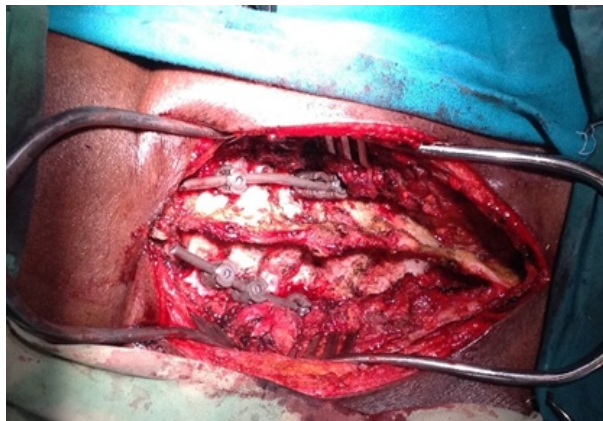


Figure 5. Intraoperative photo of the 3rd stage.

tive lesions of the spine and paraspinous collections [9] [20]. Retropharyngeal collections are common in patients with cervical spine disease [3]. Other imaging findings include thecal sac compression and spinal deformities [21] [22].

Treatment is aimed at eradicating the infection, treating clinically significant spinal cord compression, and preventing or treating deformity or instability of the spine with chemotherapy being an integral aspect of this [3]. Surgical treatment of spine tuberculosis has evolved over the years [1] and has a role in patients with neurological deficit, spine deformities and instability, large paraspinous collections, and also where chemotherapy fails [2] [3]. This role is more significant in cervical spine affection. Immobilization in skeletal traction should be done

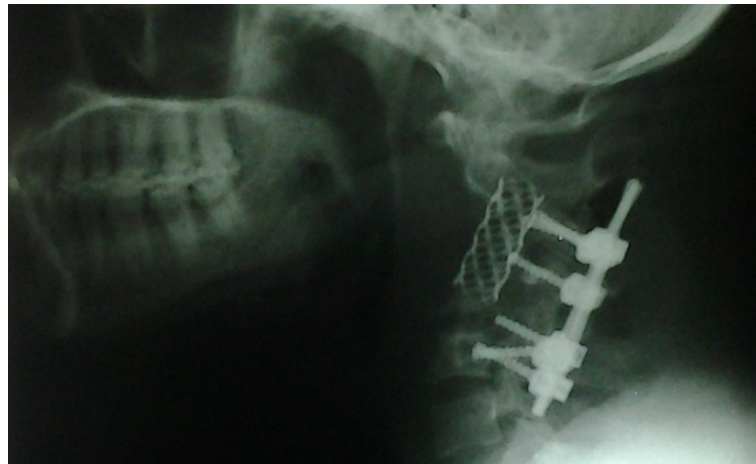
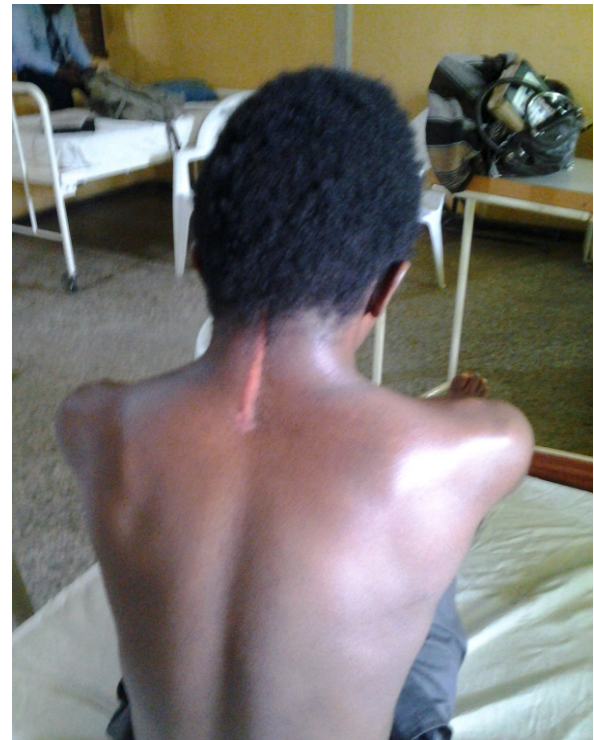
Figure 6. Plain cervical spine X-ray taken after the 3rd stage.



(a)



(b)

Figure 7. (a) Postop anterior cervical fusion; (b) Postop posterior cervical surgery.

for patients with fractures, kyphosis, or spinal instability to realign the spine and thus decompress and protect the cord before surgery [3]. Radical debridement and reconstruction of the spine is has been shown to be an effective surgical treatment [23]-[27]. Kalafong procedure which combines anterior debridement with decompression of the spinal cord (Hodgson and Stock [23]), osteotomy and/or soft tissue release, and a vascular rib pedicle bone graft (Rose, Owen and Sanderson [28]; Bradford [29]) improves bony fusion following surgical management [30].

4. Conclusion

Tuberculosis of the spine could be severely disabling as was the case in our patient. This case shows that complete



Figure 8. Patient playing a football.

neurologic recovery is feasible in spinal quadriplegia that fails to respond to antituberculous therapy when adequate decompression and fusion are done. Since tuberculous spondylitis is common in Nigeria, effort should always be made towards adequate treatment, aiming for an outcome as rewarding as our patient's.

References

- [1] Tuli, S.M. (2011) Tuberculosis of the Spine: A Historical Perspective and Evolution of Treatment. In: Rajasekaran, S., Ed., *Spinal Infections and Trauma*, Jaypee Brothers Medical Publishers (P) Ltd., New Delhi, 55-63.
- [2] Pott, P. (2002) The Classic The Chirurgical Works of Percivall Pott, F.R.S., Surgeon to St. Bartholomew's Hospital, a New Edition, with His Last Corrections. *Clinical Orthopaedics and Related Research*, **398**, 4-10. <http://dx.doi.org/10.1097/00003086-200205000-00002>
- [3] Kim, C.W., Currier, B.L., Heller, J.G. and Eismont, F.J. (2012) Cervical Spinal Infections. In: Benzel, E.C., Ed., *The Cervical Spine*, 5th Edition, Lippincott Williams and Wilkins, Philadelphia, 796-802.
- [4] Solagberu, B.A. and Ayorinde, R.O. (2001) Tuberculosis of the Spine in Ilorin, Nigeria. *East African Medical Journal*, **78**, 197-199. <http://dx.doi.org/10.4314/eamj.v78i4.9062>
- [5] Lifeso, R.M., Weaver, P. and Harder, E.H. (1985) Tuberculous Spondylitis in Adults. *The Journal of Bone and Joint Surgery*, **67**, 1405-1413.
- [6] Owolabi, L.F., Nagoda, M.M., Samaila, A.A. and Aliyu, I. (2010) Spinal Tuberculosis in Adults: A Study of 87 Cases in Northwestern Nigeria. *Neurology Asia*, **15**, 239-244.
- [7] Turgut, M. (2001) Spinal Tuberculosis (Pott's Disease): Its Clinical Presentation, Surgical Management, and Outcome. A Survey Study on 694 Patients. *Neurosurgical Review*, **24**, 8-13. <http://dx.doi.org/10.1007/PL00011973>

- [8] Patil, S.S., Mohite, S., Varma, R., Bhojraj, S.Y. and Nene, A.M. (2014) Non-Surgical Management of Cord Compression in Tuberculosis. *Asian Spine Journal*, **8**, 315-321. <http://dx.doi.org/10.4184/asj.2014.8.3.315>
- [9] Akinyoola, A.L., Adegbehingbe, O. and Ashaley, C. (2006) Tuberculosis of the Spine in Nigeria: Has Anything Changed? *The Internet Journal of Third World Medicine*, **4**.
- [10] Odey, F., Umoh, U., Meremikwu, M. and Udosen, A. (2006) Potts Disease in Children and Adolescents in Calabar, Nigeria. *The Internet Journal of Infectious Diseases*, **6**.
- [11] Akinyoola, A.L. and Adejuyigbe, E.A. (2005) Perinatal Tuberculosis with Spinal Involvement: A Case Report and Review of the Literature. *Nigerian Journal of Paediatrics*, **32**, 52-54.
- [12] Nagad, P. and Nene, A. (2011) Spinal Tuberculosis—Microbiology and Pathology. In: Rajasekaran, S., Ed., *Spinal Infections and Trauma*, Jaypee Brothers Medical Publishers (P) Ltd., New Delhi, 64-72.
- [13] Nussbaum, E.S., Rockswold, G.L., Bergman, T.A., Erickson, D.L. and Seljeskog, E.L. (1995) Spinal Tuberculosis: A Diagnostic and Management Challenge. *Journal of Neurosurgery*, **83**, 243-247. <http://dx.doi.org/10.3171/jns.1995.83.2.0243>
- [14] Jain, A.K. (2010) Tuberculosis of the Spine. *Journal of Bone and Joint Surgery—British Volume*, **92-B**, 905-913. <http://dx.doi.org/10.1302/0301-620X.92B7.24668>
- [15] Ingahalikar, V.T. (2011) Clinical Features and Physical Assessment of Tuberculosis of Spine. In: Rajasekaran, S., Ed., *Spinal Infections and Trauma*, Jaypee Brothers Medical Publishers (P) Ltd., New Delhi, 73-82.
- [16] Wang, L., Liu, L., Song, Y., Pei, F. and Liu, H. (2014) Cervical Tuberculosis Associated with Cervical Pain and Neurologic Deficit: A Case Report and Literature Review. *The Spine Journal*, **14**, 13-18. <http://dx.doi.org/10.1016/j.spinee.2013.10.055>
- [17] Mbata, G.C., Ofondu, E., Ajuonuma, B., Asodike, V.C. and Chukwumam, D. (2012) Tuberculosis of the Spine (Pott's Disease) Presenting as Hemiparesis. *African Journal of Respiratory Medicine*, **8**, 18-20.
- [18] Ikem, I.C., Bamgboye, E.A. and Olasinde, A.A. (2001) Spinal Tuberculosis: A 15 Year Review at OAUTHC Ile-Ife. *The Nigerian Postgraduate Medical Journal*, **8**, 22-25.
- [19] Njoku, C.H., Makusidi, M.A. and Ezunu, E.O. (2007) Experiences in Management of Pott's Paraplegia and Paraparesis in Medical Wards of Usmanu Danfodiyo University Teaching Hospital, Sokoto, Nigeria. *Annals of African Medicine*, **6**, 22-25. <http://dx.doi.org/10.4103/1596-3519.55735>
- [20] De Backer, A.I., Mortelé, K.J., Vanschoubroeck, I.J., Deeren, D., Vanhoenacker, F.M., De Keulenaer, B.L., *et al.* (2005) Tuberculosis of the Spine: CT and MR Imaging Features. *JBR-BTR*, **88**, 92-97.
- [21] Ogunseyinde, A.O., Obajimi, M.O., Ige, O.M., Alonge, T. and Fatunde, O.J. (2004) Computed Tomographic Evaluation of TB Spine in Ibadan. *West African Journal of Medicine*, **23**, 228-231. <http://dx.doi.org/10.4314/wajm.v23i3.28127>
- [22] Shanley, D.J. (1995) Tuberculosis of the Spine: Imaging Features. *American Journal of Roentgenology*, **164**, 659-664.
- [23] Hodgson, A.R. and Stock, F.E. (1956) Anterior Spinal Fusion a Preliminary Communication on the Radical Treatment of Pott's Disease and Pott's Paraplegia. *British Journal of Surgery*, **44**, 266-275. <http://dx.doi.org/10.1002/bjs.18004418508>
- [24] Hodgson, A.R., Stock, F.E., Fang, H.S.Y. and Ong, G.B. (1960) Anterior Spinal Fusion the Operative Approach and Pathological Findings in 412 Patients with Pott's Disease of the Spine. *British Journal of Surgery*, **48**, 172-178. <http://dx.doi.org/10.1002/bjs.18004820819>
- [25] Bailey, H.L., Gabriel, M., Hodgson, A.R. and Shin, J.S. (1972) Tuberculosis of the Spine in Children: Operative Findings and Results in One Hundred Consecutive Patients Treated by Removal of the Lesion and Anterior Grafting. *Journal of Bone & Joint Surgery, American Volume*, **54**, 1633-1657.
- [26] Kemp, H.B.S., Jackson, J.W., Jeremiah, J.D. and Cook, J. (1973) Anterior Fusion of the Spine for Infective Lesions in Adults. *Journal of Bone & Joint Surgery, British Volume*, **55-B**, 715-734.
- [27] Medical Research Council Working Party on Tuberculosis of the Spine (1982) A 10-Year Assessment of Controlled Trial Comparing Debridement and Anterior Spinal Fusion in the Management of Tuberculosis of the Spine in Patients on Standard Chemotherapy in Hong Kong. *Journal of Bone & Joint Surgery, British Volume*, **64-B**, 393-398.
- [28] Rose, G.K., Owen, R. and Sanderson, J.M. (1975) Transposition of Rib with Blood Supply for the Stabilization of a Spinal Kyphosis. *Journal of Bone & Joint Surgery, British Volume*, **57-B**, 112.
- [29] Bradford, D.S. (1980) Anterior Vascular Pedicle Bone Grafting for the Treatment of Kyphosis. *Spine*, **5**, 318-323. <http://dx.doi.org/10.1097/00007632-198007000-00005>
- [30] Louw, J.A. (1990) Spinal Tuberculosis with Neurological Deficit. Treatment with Anterior Vascularised Rib Grafts, Posterior Osteotomies and Fusion. *Journal of Bone & Joint Surgery, British Volume*, **72**, 686-693.