

Visual Disorders Outcome after Endoscopic Endonasal Trans-Sphenoidal Surgery of Pituitary Macroadenomas

Wissame El Bakkouri^{1*}, Picard Hervé², Brice Dzidzinyo³, Abdellaoui Anis¹,
Boyeldieu Louise¹, Corré Alain¹, Vignal Catherine³, Boucenna Malika⁴, Ayache Denis¹

¹ENT Department, Fondation Ophtalmologique Adolphe de Rothschild, Paris, France

²Clinical Research Unit, Fondation Ophtalmologique Adolphe de Rothschild, Paris, France

³OPH Department, Fondation Ophtalmologique Adolphe de Rothschild, Paris, France

⁴Radiological Department, Fondation Ophtalmologique Adolphe de Rothschild, Paris, France

Email: *welbakkouri@fo-rothschild.fr

Received 21 March 2016; accepted 14 May 2016; published 17 May 2016

Copyright © 2016 by authors and Scientific Research Publishing Inc.

This work is licensed under the Creative Commons Attribution International License (CC BY).

<http://creativecommons.org/licenses/by/4.0/>



Open Access

Abstract

Objective: Describe the outcome of visual disorders after endonasal transsphenoidal (EET) surgery of pituitary macroadenomas with preoperative chiasmal compression. **Patients and Methods:** From 2009 to 2013, 225 patients underwent EET surgery for sellar tumor. Among them, 168 suffered from visual disorders induced by chiasmatic compression, of which 88 met the inclusion criteria for this study. Average duration of follow up was 1.8 yrs \pm 0.4 yrs. All patients had sellar MRI before surgery and yearly postoperatively, visual acuity (VA) and/or visual field (VF) measurements before, 3 months after surgery and yearly postoperatively. **Results:** All tumors were macroadenomas with a mean preoperative MRI-estimated volume of 10.0 {plus minus} 9.07 cm³. Preoperative VA was impaired with an average of 0.43 \pm 0.13 LogMAR (left eye) and 0.36 \pm 0.14 LogMAR (right eye) and VF was disturbed in 99% \pm 2% of the cases with the most frequent disorder being bitemporal hemianopsia (38 patients). Post-operatively, the mean residual MRI-estimated tumor volume was 3.15 \pm 3.71 cm³. Mean tumor volume reduction was 62% \pm 9% (p < 0.001). Optic chiasmal compression resolved in 72% \pm 10% of the cases. Visual function improved in 86% \pm 7% of cases (p < 0.001). **Conclusion:** Endoscopic endonasal management of pituitary gland neoplasms is effective to reduce tumor volume. This technique achieved significant visual improvement in the majority of cases presenting with chiasmal compression syndrome.

Keywords

Pituitary, Macroadenoma, Visual Disorder, Chiasm Compression, Endoscopy, Transsphenoidal

*Corresponding author.

How to cite this paper: El Bakkouri, W., Hervé, P., Dzidzinyo, B., Anis, A., Louise, B., Alain, C., Catherine, V., Malika, B. and Denis, A. (2016) Visual Disorders Outcome after Endoscopic Endonasal Trans-Sphenoidal Surgery of Pituitary Macroadenomas. *International Journal of Otolaryngology and Head & Neck Surgery*, 5, 134-140.
<http://dx.doi.org/10.4236/ijohns.2016.53023>

1. Introduction

Pituitary adenomas accounts for about 10% of intracranial tumors among which 14% to 28% are non-functioning adenomas [1]-[3]. Such cases spontaneously grow up yielding to typical visual disorders related to optic chiasmal compression. Nowadays, the incidence of optic chiasmal compression is observed with MRI in 9% of the pituitary macroadenomas [4]. More rarely, involvement of the cavernous sinus leads to oculomotor symptoms. Such complications justify surgery to avoid visual degradation and to stop tumor growth progression. Endoscopic endonasal transsphenoidal (EET) surgery proved to be an effective procedure for such cases [2] [5] [6].

The aim of this retrospective study was to analyze visual outcome after EET surgery for pituitary macroadenomas.

2. Patients and Methods

From 2009 to 2013, 225 patients underwent surgical resection of pituitary tumors via endoscopic endonasal trans-sphenoidal approach. From this cohort, we retrospectively collected cases with visual impairment due to optic chiasmal compression by pituitary macroadenoma. Inclusion criteria were: 1) preoperative visual impairment (defined by visual loss and/or campimetric deficit and/or other symptoms like a diplopia); 2) pre and post operative MRI and visual status available; 3) histologically proven pituitary adenoma; 4) minimum of 3 months follow-up after surgery. Among 225 patients, 168 presented visual impairment from chiasm compression, and 88 cases met criteria for inclusion.

39 patients were females and 49 males (sex ratio 1.26). Mean age at surgery was 54.53 ± 3.01 years. All tumors were macroadenomas ($n = 76$; diameter ≥ 10 mm) or giant adenomas ($n = 12$; diameter ≥ 40 mm). The majority of tumors were gonadotropic ($n = 72$ patients). Baseline characteristics are summarized in **Table 1**.

All the patients had a preoperative MRI evaluation of the size of the pituitary adenoma and a CT scan to preoperatively study nasal fossa, sinus and skull base anatomy and for surgical navigation guidance. Tumor volume has been approximated based on MRI measurements, using an ellipsoid model (volume = $4/3 \times \pi \times 1/2 d_1 \times 1/2 d_2 \times 1/2 d_3$) where d_1 , d_2 and d_3 are the maximum tumor diameter in the orthogonal spatial axes [7].

All the patients had a visual evaluation including measurement of visual acuity (VA) and/or visual field (VF)

Table 1. Pre operative patients characteristics.

		Number of patients (n)
Sex	Men	49
	Women	39
Mean age	54.53 yrs \pm 3.01 yrs	
Histological type of the tumor	Gonadotropic	72
	Prolactinoma	4
	Corticotrophic	7
	Multi	3
	Somatotropic	1
	Thyreotropic	1
Extrasellar extension	Suprasellar component	77 Yes/8 No
	Laterosellar component	5 Yes/80 No
	Inferior extension	14 Yes/71 No
Onset of the visual acuity impairment	Acute (pituitary apoplexy)	4
	Rapid	28
	Progressive	41
Number of surgical interventions	One	88
	Two	14
	More than two	1
Radiotherapy or radiosurgery	2	

by Goldman or Humphrey perimeter. VA impairment was expressed in LogMAR (LogMAR 0 corresponding to a perfect vision and LogMAR 2.3 to a very low vision).

All the patients underwent EET removal of the tumor with neuronavigation guidance. The surgery was carried out by a team comprising a neurosurgeon and an ENT surgeon, both experienced in “four hands” EE surgery. The surgical goals were to achieve maximum decompression of the optic chiasm, to remove as much as possible of the tumoral volume and to provide tissue for histological analysis.

Two major criteria were assessed: diminution of the MRI-estimated tumor volume, and visual outcome measured by VA and/or VF at the last follow-up visit.

The mean postoperative follow up was of 1.8 ± 0.4 years.

Statistical Analysis

Data were retrieved from the patient’s hospital files, encoded in a Microsoft Excel spreadsheet and analyzed using the R statistical package. Means were compared before/after surgery using paired Student’s test and proportions were compared using Mc Nemar test with Yates correction, with alpha 5%. Confidence intervals are 95%.

3. Results

3.1. Tumor Volume

Preoperative tumor volume was $10.0 \pm 9.07 \text{ cm}^3$. Postoperatively, the mean residual MRI-estimated tumor volume was $3.15 \pm 3.71 \text{ mm}^3$ ($p < 0.001$).

Reduction of the tumor was superior to 70% of its initial volume in 50% of the cases ($n = 44$); resection was near-complete (more than 90% reduction of the tumoral volume) in 23.8% of the cases ($n = 21$) (Figure 1 and Figure 2).

3.2. Visual Function

Prior to surgery, 4.5% of the patients ($n = 4$) presented a pituitary apoplexy and were not tested because of the surgical emergency of the case. Among the whole cohort, 6.8% of the patients ($n = 6$) had diplopia despite no visual defect or VF abnormality.

The mean preoperative VA impairment was 0.43 ± 0.13 LogMAR for the left eye and 0.36 ± 0.14 LogMAR

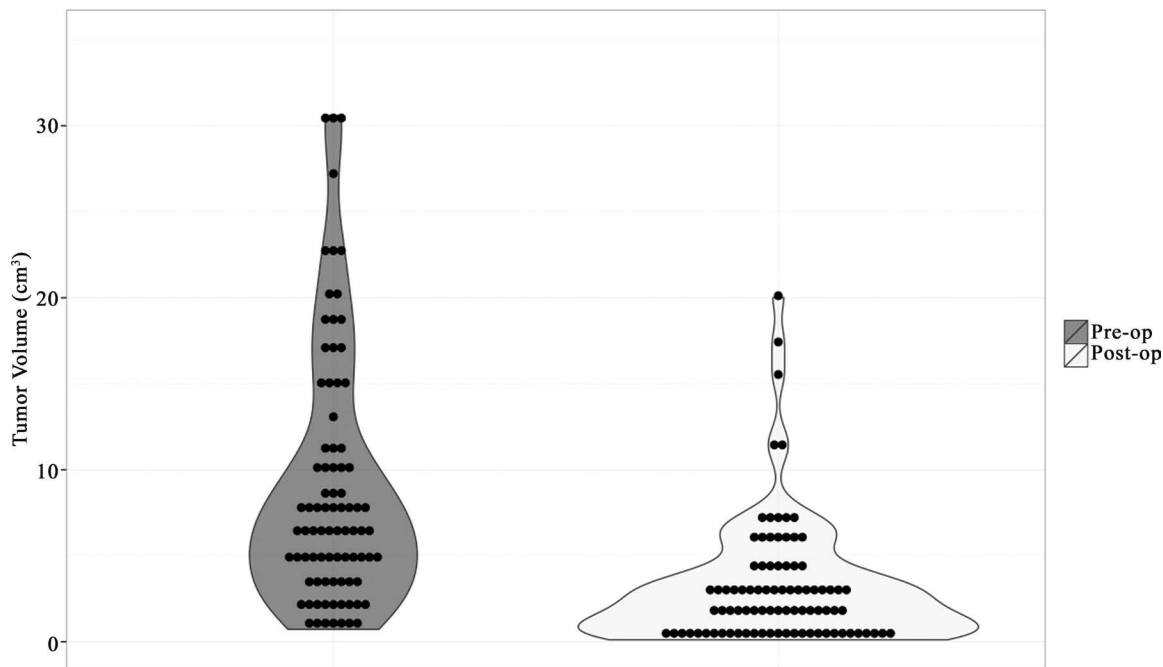


Figure 1. Reduction of the tumor volume after surgical intervention.

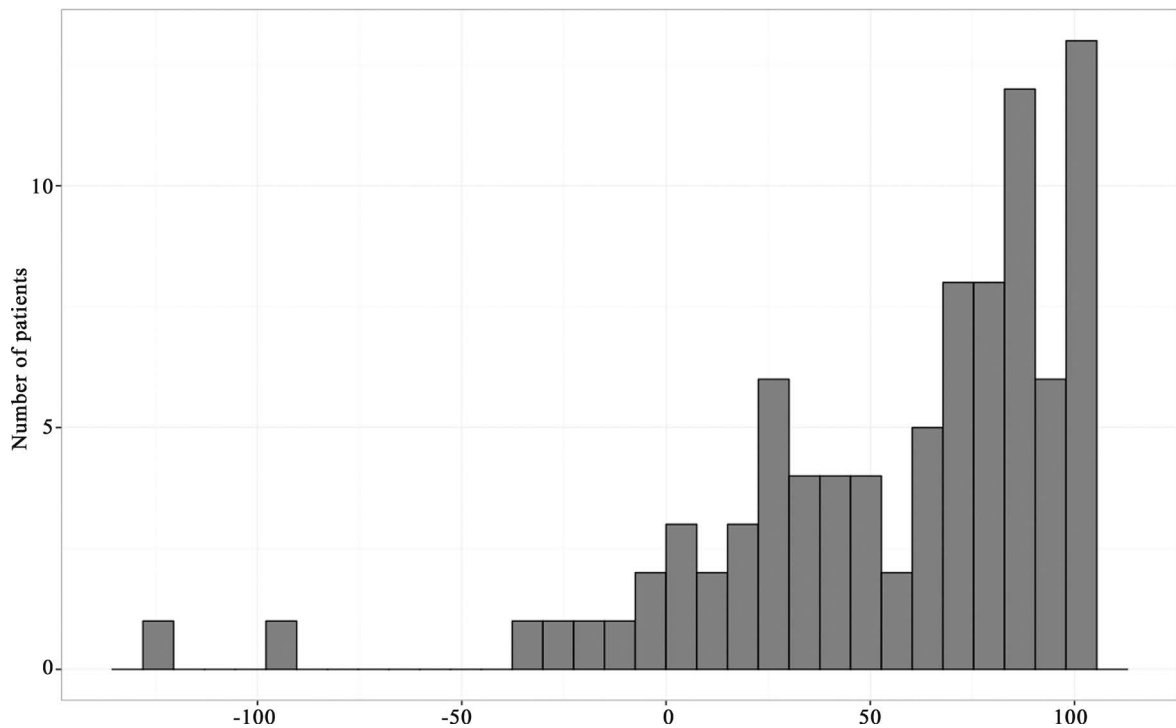


Figure 2. % reduction of tumor volume after surgery.

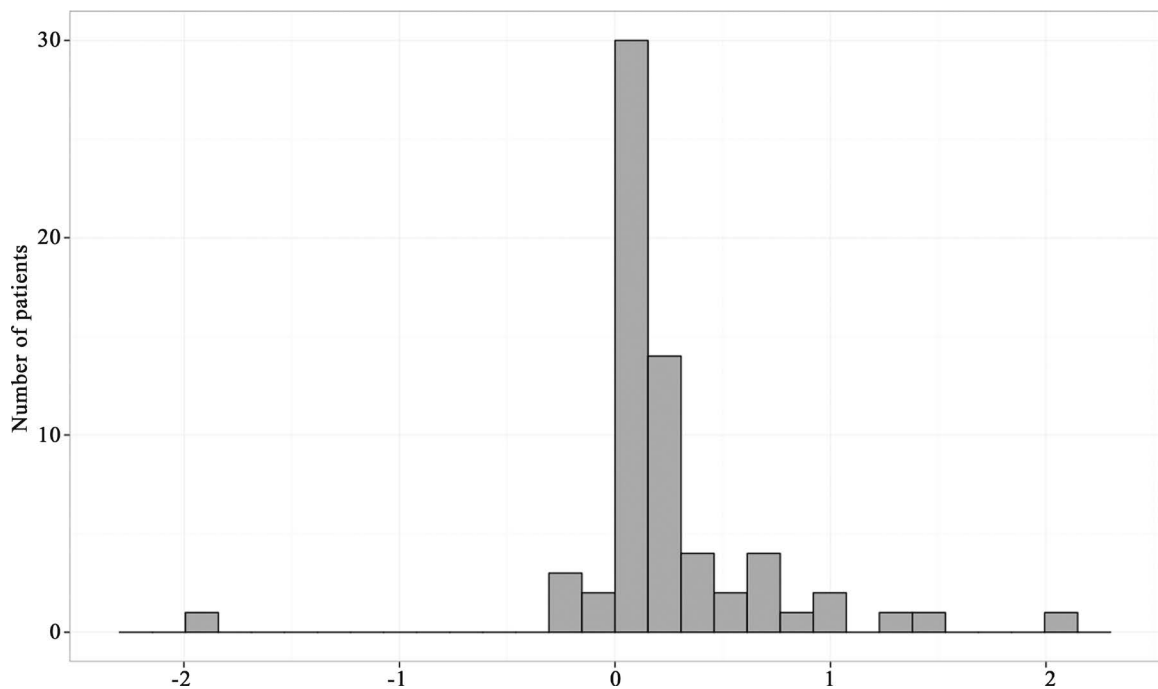


Figure 3. Visual acuity gain (LogMAR) after surgery for the left eye (mean gain was 0.24 ± 0.13 LogMAR).

for the right eye.

The mean postoperative VA impairment was of 0.16 ± 0.1 LogMAR for the left eye and of 0.16 ± 0.11 LogMAR for the right eye (Figure 3 and Figure 4). Mean VA impairment after surgery was 0.24 ± 0.13 LogMAR for the left eye and 0.24 ± 0.12 LogMAR for the right eye. The difference before/after surgery was significant ($p < 0.01$).

If comparing pre and postoperative VA, data were available for 63 patients. There was a clinically significant improvement of the VA (average VA of both eyes improving by 0.2 LogMAR or more) in 47% of the cases (n = 30/63).

Preoperatively, 81 patients had a VF evaluation among whom 46.9% (n = 38) had a bitemporal hemianopsia and 1.2% (n = 1) had no VF cut (Table 2).

Assessment of VF 3 months after surgery was performed in 78 patients. It showed complete recovery in 15 cases, partial recovery in 27 cases and no improvement in 36 cases (Table 3).

4. Discussion

EET surgery is a widely accepted procedure for the resection of micro, macro and giant pituitary adenoma [1] [5] [8]-[10]. It allows total resection in almost 20% of the cases in macroadenomas and giant adenom Apr;

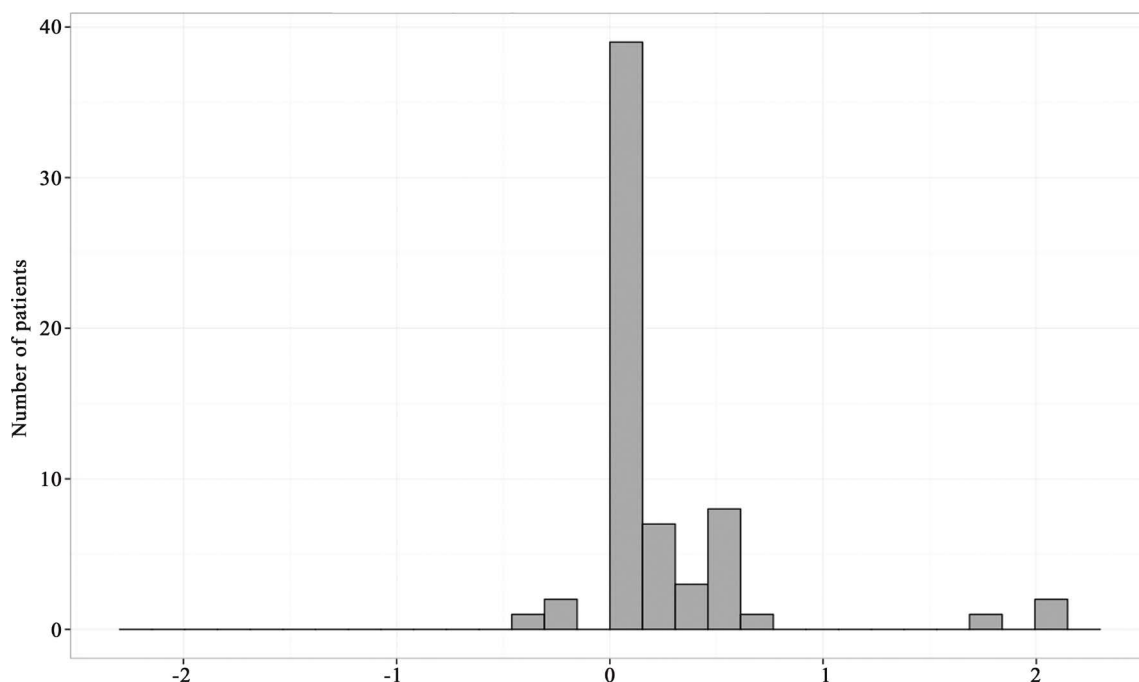


Figure 4. Visual acuity gain (LogMAR) after surgery for the right eye (mean gain was 0.24 ± 0.12 LogMAR).

Table 2. Pre operative visual field (VF) abnormalities.

VF impairment	Frequency	Number of patients
Bitemporal hemianopsia	46.9%	38
Lateral homonymous hemianopsia	4.9%	4
Other VF cut	30.9%	25
Unilateral hemianopsia	16%	13
No VF abnormality	1.2%	1
TOTAL	100%	81

Table 3. Post operative visual field abnormalities.

VF impairment	Frequency	Number of patients
Bitemporal hemianopsia	20.5%	16
Lateral homonymous hemianopsia	3.8%	3
Other VF cut	52.6%	41
Unilateral hemianopsia	3.8%	3
No VF abnormality	19.2%	15
TOTAL	100%	78

158(4): 677-683 as [2] [11]. Other series conclude to total resection achieved in 38% to 66% of the cases, even for giant adenomas involving the cavernous sinus [1] [3] [12]-[14]. Such encouraging results are explained by an improved panoramic visualization with EET, particularly for structures like the optic-carotid recess and the diaphragm sella. In case of visual impairment, EET is also indicated and yields good results [3]. In our article, reduction of the tumor was superior to 70% of its initial volume in 50% of the cases. There was a clinically significant improvement of the VA in 47% of the cases (n = 30/63). We observed 17% of complete recovery of the VA and 19.23% of complete recovery of the VF (n = 15/78).

4.1. Visual Tests

Between 2009 and 2013, 225 patients underwent EET resection of a sellar tumor at our institution. Among them 168 (74.6%) presented visual disorders, in agreement with results reported in the literature with rates ranging from 31% to 89% [1] [4] [6] [15]-[17]. In our series, 88 patients met inclusion criteria. Other patients were not eligible for various reasons (early lost of follow-up, unavailable MRI or visual examination data, other histological type of tumor).

The functional results were better for VF (total recovery in 19.2% of the cases and partial recovery in 35%) than for VA (total recovery in 17% and improvement in 30% of the cases). This was noted in a series of Juraska *et al.* [2]. On the other hand, Peter *et al.* [4] found better outcomes concerning VF than VA.

Cohen *et al.* [18] found an inverse correlation between the duration of visual symptoms and final outcome for both VF and VA.

4.2. MRI

In the literature, many authors recommended calculating tumor volume rather than diameters because it is a significant predictor of imaging outcome on long-term follow-up [13]. Hoffstetter *et al.* suggested a volume of $\geq 10 \text{ cm}^3$ as a modern definition of pituitary macroadenomas [19]. However, as noted by Egger *et al.* simple methods as geometric models like the ellipsoidal model provide a rough approximation of the tumor volume [7].

In our retrospective study, tumor volume was estimated using an ellipsoid model. We believe that with this model, volumes may be underestimated but the results were consistent with those found in the literature [20]. For Juraska *et al.* [2], volumetric analysis provides a more accurate measurement of the extent of the resection than ellipsoidal volume calculation. In our series, we approximated the tumoral volume by calculating ellipsoidal volumes because native MRI was not always at the radiologist disposal to calculate volume using dedicated software.

Postoperatively, the residual tumor volume was $3.15 \pm 3.71 \text{ cm}^3$ ($p < 0.01$). As might be expected, the rate of residual tumor is higher in macro-adenoma (and giant adenoma), particularly in suprasellar and cavernous sinus spreading [2] [13]. Juraska *et al.* reported complete resection in 24.2% in their series of 76 giant and large macro-adenomas [2]. In our series, 23.8% of the patients had total or near total resection.

4.3. Limits of the Study

This is a retrospective study so we couldn't study the medical chart of the 225 operated on between 2009 and 2013 because of insufficient data. We decided to focus on pituitary adenomas excluding all other histological type of pituitary tumors because we don't know the evolution of all types of tumors.

5. Conclusion

Visual disorders are common complications of pituitary adenoma natural growth. In this series, we found that endoscopic endonasal transsphenoidal resection of macroadenoma with chiasm compression syndrome was reliable in improving visual impairment.

Conflict of Interest

The authors have no personal financial or institutional interest in any of the drugs, materials or devices described in this article.

References

- [1] Torales, J., Halperin, I., Hanzu, F., Mora, M., Alobod, I., De Notaris, M., *et al.* (2014) Endoscopic Endonasal Surgery for Pituitary Tumors. Results in a Series of 121 Patients Operated at the Same Center and by the Same Neurosurgeon. *Endocrinología y Nutrición (English Edition)*, **61**, 410-416. <http://dx.doi.org/10.1016/j.endoen.2014.07.002>
- [2] Juraschka, K., Khan, O.H., Godoy, B.L., Monsalves, E., Kilian, A., Kriscsek, B., *et al.* (2014) Endoscopic Endonasal Transsphenoidal Approach to Large and Giant Pituitary Adenomas: Institutional Experience and Predictors of Extent of Resection. *Journal of Neurosurgery*, **121**, 75-83. <http://dx.doi.org/10.3171/2014.3.JNS131679>
- [3] Gómez, R.C. (2014) Non-Functioning Pituitary Tumors: 2012 Update. *Endocrinología y Nutrición (English Edition)*, **61**, 160-170. <http://dx.doi.org/10.1016/j.endoen.2014.02.011>
- [4] Peter, M. and De Tribolet, N. (1995) Visual Outcome after Transsphenoidal Surgery for Pituitary Adenomas. *British Journal of Neurosurgery*, **9**, 151-157. <http://dx.doi.org/10.1080/02688699550041485>
- [5] Ammirati, M., Wei, L. and Ciric, I. (2013) Short-Term Outcome of Endoscopic versus Microscopic Pituitary Adenoma Surgery: A Systematic Review and Meta-Analysis. *Journal of Neurology, Neurosurgery & Psychiatry*, **84**, 843-849. <http://dx.doi.org/10.1136/jnnp-2012-303194>
- [6] Chone, C.T., Sampaio, M.H., Sakano, E., Paschoal, J.R., Garnes, H.M., Queiroz, L., *et al.* (2014) Endoscopic Endonasal Transsphenoidal resection of pituitary Adenomas: Preliminary Evaluation of Consecutive Cases. *Brazilian Journal of Otorhinolaryngology*, **80**, 146-151. <http://dx.doi.org/10.5935/1808-8694.20140030>
- [7] Davies, B.M., Carr, E., Soh, C. and Gnanalingham, K.K. (2016) Assessing Size of Pituitary Adenomas: A Comparison of Qualitative and Quantitative Methods on MR. *Acta Neurochirurgica (Wien)*, **158**, 677-683.
- [8] Cusimano, M.D., Kan, P., Nassiri, F., Anderson, J., Goguen, J., Vanek, I., *et al.* (2012) Outcomes of Surgically Treated Giant Pituitary Tumours. *Canadian Journal of Neurological Sciences*, **39**, 446-457. <http://dx.doi.org/10.1017/S0317167100013950>
- [9] Koutourousiou, M., Gardner, P.A., Fernandez-Miranda, J.C., Paluzzi, A., Wang, E.W. and Snyderman, C.H. (2013) Endoscopic Endonasal Surgery for Giant Pituitary Adenomas: Advantages and Limitations. *Journal of Neurosurgery*, **118**, 621-631. <http://dx.doi.org/10.3171/2012.11.JNS121190>
- [10] Yang, I., Wang, M.B. and Bergsneider, M. (2010) Making the Transition from Microsurgery to Endoscopic Transsphenoidal Pituitary Neurosurgery. *Neurosurgery Clinics of North America*, **21**, 643-651.
- [11] Komotar, R.J., Starke, R.M., Raper, D.M.S., Anand, V.K. and Schwartz, T.H. (2012) Endoscopic Endonasal Compared with Microscopic Transsphenoidal and Open Transcranial Resection of Giant Pituitary Adenomas. *Pituitary*, **15**, 150-159. <http://dx.doi.org/10.1007/s11102-011-0359-3>
- [12] Roelfsema, F., Biermasz, N.R. and Pereira, A.M. (2012) Clinical Factors Involved in the Recurrence of Pituitary Adenomas after Surgical Remission: A Structured Review and Meta-Analysis. *Pituitary*, **15**, 71-83. <http://dx.doi.org/10.1007/s11102-011-0347-7>
- [13] Gopalan, R., Schlesinger, D., Vance, M.L., Laws, E. and Sheehan, J. (2011) Long-Term Outcomes after Gamma Knife Radiosurgery for Patients with a Nonfunctioning Pituitary Adenoma. *Neurosurgery*, **69**, 284-293. <http://dx.doi.org/10.1227/NEU.0b013e31821bc44e>
- [14] Berkman, S., Schläpfer, S., Nimsky, C., Fahlbusch, R. and Buchfelder, M. (2014) Follow-Up and Long-Term Outcome of Nonfunctioning Pituitary Adenoma Operated by Transsphenoidal Surgery with Intraoperative High-Field Magnetic Resonance Imaging. *Acta Neurochirurgica (Wien)*, **156**, 2233-2243. <http://dx.doi.org/10.1007/s00701-014-2210-x>
- [15] Paluzzi, A., Fernandez-Miranda, J.C., Tonya Stefkó, S., Challinor, S., Snyderman, C.H. and Gardner, P.A. (2014) Endoscopic Endonasal Approach for Pituitary Adenomas: A Series of 555 Patients. *Pituitary*, **17**, 307-319. <http://dx.doi.org/10.1007/s11102-013-0502-4>
- [16] Robenshtok, E., Benbassat, C.A., Hirsch, D., Tzvetov, G., Cohen, Z.R., Iraqi, H.M., *et al.* (2014) Clinical Course and Outcome of Nonfunctioning Pituitary Adenomas in the Elderly Compared with Younger Age Groups. *Endocrine Practice*, **20**, 159-164.
- [17] Murad-Kejbou, S. and Eggenberger, E. (2009) Pituitary Apoplexy: Evaluation, Management, and Prognosis. *Current Opinion in Ophthalmology*, **20**, 456-461. <http://dx.doi.org/10.1097/ICU.0b013e3283319061>
- [18] Cohen, A.R., Cooper, P.R., Kupersmith, M.J., Flamm, E.S. and Ransohoff, J. (1985) Visual Recovery after Transsphenoidal Removal of Pituitary Adenomas. *Neurosurgery*, **17**, 446-452. <http://dx.doi.org/10.1227/00006123-198509000-00008>
- [19] Hofstetter, C.P., Nanaszko, M.J., Mubita, L.L., Tsiouris, J., Anand, V.K. and Schwartz, T.H. (2012) Volumetric Classification of Pituitary Macroadenomas Predicts Outcome and Morbidity Following Endoscopic Endonasal Transsphenoidal Surgery. *Pituitary*, **15**, 450-463. <http://dx.doi.org/10.1007/s11102-011-0350-z>
- [20] Egger, J., Kapur, T., Nimsky, C. and Kikinis, R. (2012) Pituitary Adenoma Volumetry with 3D Slicer. *PLoS One*, **7**, e51788. <http://dx.doi.org/10.1371/journal.pone.0051788>