

# Vascular Loops and Neuro-Otologic Symptoms: Is There Any Correlation?

Amaya Roldán-Fidalgo\*, Antonio Rodríguez-Valiente, Francisco Martín González, Mayte Pinilla,  
Almudena Trinidad, Beatriz Brea Álvarez

Department of Otorhinolaryngology and Neuroradiology, Puerta de Hierro University Hospital, Madrid, Spain  
Email: \*amayarf@gmail.com, arova777@gmail.com, madrigall11@gmail.com, pinillamayte@gmail.com, atrinid@yahoo.es,  
beatrizbreaalvarez@yahoo.es

Received September 25, 2013; revised October 20, 2013; accepted November 2, 2013

Copyright © 2013 Amaya Roldán-Fidalgo *et al.* This is an open access article distributed under the Creative Commons Attribution License, which permits unrestricted use, distribution, and reproduction in any medium, provided the original work is properly cited.

## ABSTRACT

**Objective:** To determine the relationship between vascular loops in the internal auditory canal and otologic symptoms. **Methods:** We performed a retrospective study, with a systematic review of the literature and analyzed the magnetic resonances imaging (MRI) of 91 patients attended in the ENT department since April to June 2013, in order to correlate radiological findings with otologic symptoms. **Results:** Vascular loops were seen in the internal auditory canal of patients without clinical symptoms; however an association was found between the presence of vascular compression of the eighth nerve displayed on MRI and the presence of sensorineural hearing loss and tinnitus. No association was found between vertigo and vascular loops. **Conclusion:** The presence of vascular loops in the internal auditory canal may be an incidental finding in MRIs of patients without clinical symptoms. However, in patients with tinnitus or sensorineural hearing loss that is unexplained by other clinical pathologies, these may be correlated with the existence of vascular loops which compress the eighth cranial nerve or contact the bone wall of the internal auditory canal. Further studies involving a larger number of patients are required to accurately evaluate the association between these symptoms and vascular loops.

**Keywords:** Vascular Loop; Arterial Loop; Internal Auditory Canal; Tinnitus; Deafness; Vertigo

## 1. Introduction

The presence of vascular loops in the internal auditory canal (IAC), formed by the anterior inferior cerebellar artery (AICA), is a common finding in the systematic study of MRIs [1,2]. Controversial results have been reported in the literature about the relationship between vascular compression of the vestibular nerve trunks and neuro-otologic symptoms, and some authors have suggested that compression of the nerve might be the origin of otherwise unexplained as hearing loss, tinnitus, neurological symptoms and vertigo [3-10].

In order to determinate the relationship between vascular loops and otologic symptoms, we performed a retrospective study in patients attended in the ENT department.

## 2. Materials and Methods

We performed a retrospective study with a systematic

\*Corresponding author.

review of the literature and we studied the MRIs of 91 patients attended in our ENT department over a three months period (April to June 2013), looking for the presence of vascular loops in the internal auditory canal. In patients with vascular loops in the MRI we collected data related to neuro-otologic symptoms (hearing loss, tinnitus, vertigo and hemifacial spasm) from their medical history. All patients had been performed a complete otoneurological examination with otoscopy, audiometry and videonystagmography.

## 3. Results

A total of 91 MRIs of patients attended in our ENT department were analyzed, 20 MRIs displayed vascular loops in the IAC.

We collected data from the medical history of the 20 patients with vascular loop in the MRI, related to neuro-otologic symptoms. We found 12 patients with otologic symptoms, three patients with IAC vascular loops in the

asymptomatic ear, and five patients without clinical symptoms.

Out of 12 patients with otologic symptoms, a vascular compression of the eighth cranial nerve on MRI (**Figure 1(a)**) was presented in six patients, four patient reported sensorineural hearing loss, and two patients continuous tinnitus. A vascular loop in contact with the bone wall of the internal auditory canal (**Figure 1(b)**) was presented in six patients; all of them reported the presence of tinnitus resistant to standard medical treatment (**Table 1**). None of the patients had vertigo or hemifacial spasm.

### 4. Discussion

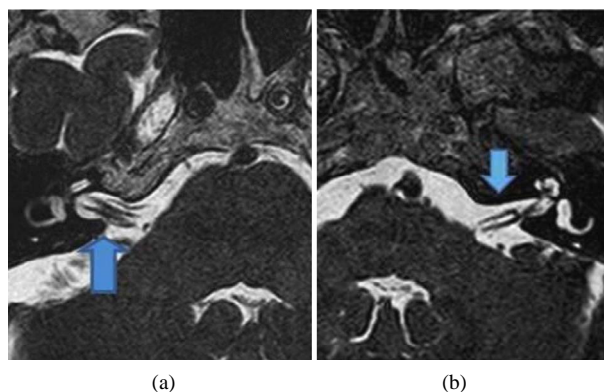
There is an apparent discrepancy between the frequent finding of vascular loops penetrating the internal auditory canal in anatomic studies (12% by post-mortem dissections [2], 7% by computed tomography cisternography [11], 14% - 34% by magnetic resonance imaging (MRI) [12,13] in the normal population), and the infrequency of ear symptoms associated with the presence of the loops. Some explanations of this discrepancy include the development of symptoms when the artery elongates (congenital or acquired), hardens (arteriosclerosis), or becomes fixed to the nerve (arachnoid adhesions) and compresses it [14]. The space available for the facial, vestibulocochlear nerve and AICA loop in the internal auditory meatus is minimum [15], creating an anatomic susceptibility of the nerve to vascular compression dysfunction.

Auditory symptoms may be due to a complex interaction between the seventh or eighth cranial nerve and the vascular loop, in which the loop compresses the nerve and the nerve compromises circulation to the inner ear. The findings of a cochlear type of hearing loss, excellent speech discrimination and normal caloric test results should raise the suspicion of a vascular loop [16]. A loop in contact with the vascular wall might cause pulsatile tinnitus by direct transmission of pulsations to the cochlea via the internal auditory canal (bone conduction mechanism) [17-21]. The compression of facial nerve is frequently, and cause hemifacial spasm [22]. The compression of the auditory and vestibular nerve trunks by vascular loops might cause sensorineural hearing loss, tinnitus and vertigo [2-4].

In the present study none of the 91 patients with vascular loop in the IAC presented vertigo or hemifacial spasm.

The presence of pulsatile tinnitus (50%) and sensorineural hearing loss (33%) were the conditions most frequently encountered among the patient group studied (**Table 1**).

De Riddet *et al.* [18] and Nowe *et al.* [23] found that subjects with pulsatile tinnitus were 80 times more likely to have a contacting vascular loop than patients with non-



**Figure 1. (a) Vascular loop adjacent to the eighth cranial nerve, in a patient with sensorineural hearing loss in the right ear; (b) MRI with a vascular loop in contact with the internal auditory canal in a patient with pulsatile synchronous tinnitus.**

**Table 1. Distribution of otologic symptoms in the patients with vascular loop in the magnetic resonance imaging.**

VASCULAR LOOP IN THE INTERNAL AUDITORY CANAL	SYMPTOMS		
	Sensorineural hearing loss	Continuous tinnitus	Pulsatile tinnitus
Compression of the eight nerve	4	2	-
Contact the bone wall	-	-	6

pulsatile tinnitus.

Chadha and Weiner [1] suggested that the presence of unilateral hearing loss were twice more likely to have vascular loops in the symptomatic ear than in the asymptomatic ear.

In selected cases, when a vascular loop is found to be in contact with the affected cranial nerve, and no other cause is identified, it would seem reasonable to consider invasive neurosurgical micro-vascular decompression with mixed results [1,24-26]. Shredded Teflon is place in the internal auditory canal between the cochlea and the intrameatal vascular loop [1]. The objective is to create a sound barrier between the walls of the internal auditory canal and the loop, and between the loop and the cochlea, without causing too much compression on the cochlear nerve. None patients attended in our ENT department required neurosurgical micro-vascular decompression due to medical control of symptoms.

### 5. Conclusions

In patients without associated with neuro-otologic symptoms, the presence of vascular loops in the internal auditory canal may be an incidental finding in MRIs, however, in patients with pulsatile or continuous tinnitus, or sensorineural hearing loss, vertigo, which is unexplained by other clinical pathologies, it may be correlated with the existence of vascular loops which compress the eighth

cranial nerve, or facial nerve in case of hemifacial spasm, or contact the bone wall of the internal auditory canal.

As a result of the limited number of cases and small amount of literature found, further multicentre studies involving a larger number of patients would be advisable to correlate otologic symptoms with the presence of vascular loops in the internal auditory canal and thereby accurately evaluate the association between these symptoms and vascular loops.

## REFERENCES

- [1] N. K. Chadha and G. M. Weiner, "Vascular Loops Causing Otological Symptoms," *Clinical Otolaryngology and Allied Sciences*, Vol. 33, No. 5, 2008, pp. 5-11. <http://dx.doi.org/10.1111/j.1749-4486.2007.01597.x>
- [2] C. Reisser and H. F. Schuknecht, "The Anterior Inferior Cerebellar Artery in the Internal Auditory Canal," *Laryngoscope*, Vol. 101, No. 7, 1991, pp. 761-766. <http://dx.doi.org/10.1288/00005537-199107000-00012>
- [3] J. Kanzaki and E. Koyoma, "Vascular Loops in the Internal Auditory Canal as Possible Cause of Meniere's Disease," *Auris Nasus Larynx*, Vol. 13, No. 2, 1986, pp. S105-S111.
- [4] J. Kanzaki and K. Ogawa, "Internal Auditory Canal Vascular Loops and Sensorineural Hearing Loss," *Acta Oto-Laryngologica*, Vol. 447, 1988, pp. 88-93. <http://dx.doi.org/10.3109/00016488809102862>
- [5] L. M. Odkvist, K. A. Thuomas and M. Niklasson, "Macrovascular Causes Underlying Otoneurological Disturbances," *Acta Oto-Laryngologica*, Vol. 115, No. 2, 1995, pp. 145-148. <http://dx.doi.org/10.3109/00016489509139278>
- [6] N. Galvez-Jimenez, M. R. Hanson and M. Desai, "Unusual Causes of Hemifacial Spasm," *Seminars in Neurology*, Vol. 21, No. 1, 2001, pp. 75-83. <http://dx.doi.org/10.1055/s-2001-13122>
- [7] J. Magnan, F. Caces, P. Locatelli and A. Chays, "Hemifacial Spasm: Endoscopic Vascular Decompression," *Otolaryngology-Head and Neck Surgery*, Vol. 117, No. 4, 1997, pp. 308-314.
- [8] J. A. Herzog, S. Bailey and J. Meyer, "Vascular Loops of the Internal Auditory Canal: A Diagnostic Dilemma," *American Journal of Otolaryngology*, Vol. 18, No. 1, 1997, pp. 26-31.
- [9] R. R. Tash, E. L. Kier and D. Chyatte, "Hemifacial Spasm Caused by a Tortuous Vertebral Artery: MR Demonstration," *Journal of Computer Assisted Tomography*, Vol. 12, No. 3, 1988, pp. 492-494. <http://dx.doi.org/10.1097/00004728-198805010-00027>
- [10] P. J. Jannetta, "Neurovascular Compression in Cranial Nerve and Systemic Disease," *Annals of Surgery*, Vol. 192, No. 4, 1980, pp. 518-525. <http://dx.doi.org/10.1097/0000658-198010000-00010>
- [11] J. De Carpentier, N. Lynch, A. Fisher, et al., "MR Imaged Neurovascular Relationships at the Cerebellopontine Angle," *Clinical Otolaryngology*, Vol. 21, No. 4, 1996, pp. 312-316. <http://dx.doi.org/10.1111/j.1365-2273.1996.tb01077.x>
- [12] J. Kanzaki and K. Ogawa, "Internal Auditory Canal Vascular Loops and Sensorineural Hearing Loss," *Acta Oto-Laryngologica*, Vol. 105, No. 447, 1988, pp. 88-93. <http://dx.doi.org/10.3109/00016488809102862>
- [13] A. Sirikci, Y. Bayazit, E. Ozer, et al., "Magnetic Resonance Imaging Based Classification of Anatomic Relationship between the Cochleovestibular Nerve and Anterior Inferior Cerebellar Artery in Patients with Non-Specific Neuro-Otologic Symptoms," *Surgical and Radiologic Anatomy*, Vol. 27, No. 6, 2005, pp. 531-535. <http://dx.doi.org/10.1007/s00276-005-0015-6>
- [14] E. L. Applebaum and G. Valvasorri, "Internal Auditory Canal Vascular Loops: Audiometric and Vestibular System Findings," *American Journal of Otolaryngology*, 1985, pp. 110-113.
- [15] R. M. Irving and S. Chavda, "Re: Vascular Loops Causing Otological Symptoms: A Systematic Review and Meta-Analysis," *Clinical Otolaryngology*, Vol. 33, No. 5, 2008, pp. 498; Author Reply 499.
- [16] E. L. Applebaum and G. E. Valvassori, "Auditory and Vestibular System Findings in Patients with Vascular Loops in the Internal Auditory Canal," *Annals of Otolaryngology, Rhinology and Laryngology*, Vol. 112, 1984, pp. 63-70.
- [17] L. Jane, M. D. Weissman, E. Barry, et al., "Imaging of Tinnitus: A Review," *Radiology*, Vol. 216, No. 2, 2000, pp. 342-349.
- [18] D. De Ridder, L. De Ridder, V. Nowe, et al., "Pulsatile Tinnitus and the Intrameatal Vascular Loop: Why Do We Not Hear Our Carotids?" *Neurosurgery*, Vol. 57, No. 6, 2005, pp. 1213-1217. <http://dx.doi.org/10.1227/01.NEU.0000186035.73828.34>
- [19] B. F. McCabe and L. A. Harker, "Vascular Loop as a Cause of Vertigo," *Annals of Otolaryngology, Rhinology and Laryngology*, Vol. 92, No. 6, 1983, pp. 542-543.
- [20] A. Sismanis, "Pulsatile Tinnitus: A 15-Year Experience," *American Journal of Otolaryngology*, Vol. 19, 1998, pp. 472-477.
- [21] E. L. Applebaum and G. E. Valvassori, "Auditory and Vestibular System Findings in Patients with Vascular Loops in the Internal Auditory Canal," *Annals of Otolaryngology, Rhinology and Laryngology*, Vol. 112, 1984, pp. 63-70.
- [22] A. L. McDermott, S. N. Dutt, R. M. Irving, et al., "Anterior Inferior Cerebellar Artery Syndrome: Fact or Fiction," *Clinical Otolaryngology*, Vol. 28, No. 2, 2003, pp. 75-80. <http://dx.doi.org/10.1046/j.1365-2273.2003.00662.x>
- [23] V. Nowe, D. De Ridder, P. H. Van de Heyning, et al., "Does the Location of a Vascular Loop in the Cerebellopontine Angle Explain Pulsatile and Non-Pulsatile Tinnitus?" *European Radiology*, Vol. 14, 2004, pp. 2282-2289. <http://dx.doi.org/10.1007/s00330-004-2450-x>
- [24] P. J. Jannetta, "Neurovascular Cross-Compression in Patients with Hyperactive Dysfunction Symptoms of the Eighth Cranial Nerve," *Surgical Forum*, Vol. 26, 1975, pp. 467-468.
- [25] G. B. Brookes, "Vascular-Decompression Surgery for Severe Tinnitus," *American Journal of Otolaryngology*, Vol. 17, No. 4, 1996, pp. 569-576.
- [26] T. Okamura, Y. Kurokawa, N. Ikeda, et al., "Microvascular Decompression for Cochlear Symptoms," *Journal of Neurosurgery*, Vol. 93, No. 3, 2000, pp. 421-426. <http://dx.doi.org/10.3171/jns.2000.93.3.0421>