

Role of Thoracic Sonographic Scan in Diagnosis of Pneumothorax

Kawa A. Mahmood¹, Aram Baram^{1,2*}, Fahmi H. Kakamad^{1,2}, Kosar K. Ahmed³

¹Department of Surgery, Faculty of Medical Sciences, School of Medicine, University of Sulaimani, Sulaymaniyah, Iraqi Kurdistan

²Department of Thoracic and Cardiovascular Surgery, Sulaimani Teaching Hospital, Sulaymaniyah, Iraqi Kurdistan

³Sulaimani DOH, Sulaimani Teaching Hospital, Sulaymaniyah, Iraq Kurdistan

Email: kawaaya06@yahoo.com, aram.baram@gmail.com, drkakamad@gmail.com, radiologistkosar@gmail.com

Received 26 June 2015; accepted 25 August 2015; published 28 August 2015

Copyright © 2015 by authors and Scientific Research Publishing Inc.

This work is licensed under the Creative Commons Attribution International License (CC BY).

<http://creativecommons.org/licenses/by/4.0/>



Open Access

Abstract

Background: Pneumothorax is a common problem seen in patients with acute and chronic medical and traumatic conditions with wide range of clinical presentations ranging from subtle decrease in breath sounds to cardiopulmonary arrest caused by tension pneumothorax. Pneumothorax is traditionally diagnosed by chest radiography, ultrasound is fairly a new modality of diagnosis. Ultrasound is a rapid noninvasive bedside test that may reduce mortality from this pathology by early detection. There are certain sonographic criteria that can exclude or confirm pneumothorax; this work has been performed to analyze these criteria. **Patients and Methods:** The study was done in Sulaimani teaching hospital and Sulaimani emergency hospital from June 1st to 10th August 2013. We performed thoracic ultrasound on fifty three diagnosed cases of pneumothorax (by chest X-ray &/or thoracic computed tomography). The age of the patients ranged between (10 - 82 years), mean age (38 years), 35 males and 18 females. Lung sliding sign, lung point sign and A line signs were recorded and analyzed. **Results:** The sensitivity, specificity, positive predictive value and negative predictive values of absent lung sliding sign were: 100%, 94%, 94% and 100% respectively, for lung point sign were: 70%, 100%, 100% and 68% respectively, for A line sign were: 91%, 71%, 73% and 91% respectively, for absent lung sliding and lung point sign together were 70%, 100%, 100% & 68.9% respectively. **Conclusion:** We confirmed the conclusion of other studies which stated that presence of lung sliding excludes pneumothorax and identification of lung point in a case with absent lung sliding is diagnostic of pneumothorax.

*Corresponding author.

Keywords

Pneumothorax, Sonography, e-FAST, Lung Sliding Sign

1. Introduction

Pneumothorax is defined as the presence of air in the pleural space [1]. It has a range of presentations from a mild decrease in breath sounds to cardiopulmonary arrest [2]. The diagnosis of a pneumothorax is usually made with a combination of clinical signs and symptoms, which may be subtle, and plain chest radiography, but computed tomography (CT) remains the gold standard [3]-[5]. The use of thoracic ultrasound has gained slow acceptance due to the traditional teaching that the air-filled lungs are not ultrasound friendly. Over the past decade, bedside lung sonography has developed an established role in the diagnosis of thoracic diseases. Husain *et al.* concluded that thoracic ultrasound is useful machine to quickly confirm or exclude presence of pneumothorax in emergency setting. The Focused Assessment with Sonography in Trauma (FAST) examination has now been modified to include lung imaging and it has been renamed as the E-FAST examination, with “E” standing for extended [3].

The bedside sonographic diagnosis of pneumothorax can be performed with most ultrasound machines. A straight linear array high frequency probe (5 - 13 MHz) may be most helpful in analyzing superficial structures such as the pleura, while curvilinear array probe may be more suitable for deeper lung [6].

In a supine patient, air accumulates in the anterior region of the chest at the second to fourth intercostal spaces in the mid-clavicular line. It is the recommended initial area for investigation in a trauma [7] [8]. The landmarks of two ribs should be identified first with posterior shadowing behind them and the pleural line in between them. This is typically called “the bat sign” where the periosteum of the ribs represents the wings and the bright hyperechoic pleural line in between them represents the bats’ body [9] (Figure 1).

Between these two ribs, parietal and visceralplura are seen sliding across one another. Pleural sliding is the most important finding in normal aerated lung [10]. The use of M-mode, provides more evidence that the pleural line is sliding. It is beneficial in patients where sliding may be subtle, such as, in the elderly or in patients with poor pulmonary reserve, who are not taking large breaths. By using M-mode, two different patterns are displayed: The motionless portion above the pleural line creates horizontal “waves”, and the sliding below it creates a granular pattern, the ‘sand’, this resembles waves crashing in onto the sand and it is therefore called the “seashore sign” which is a feature of a normal lung [7] [11] [12].

In pneumothorax, M-mode only displays one pattern of parallel horizontal lines above and below the pleural line. This pattern resembles a “barcode” and is often called the “stratosphere sign” [11] [12] (Figure 2).

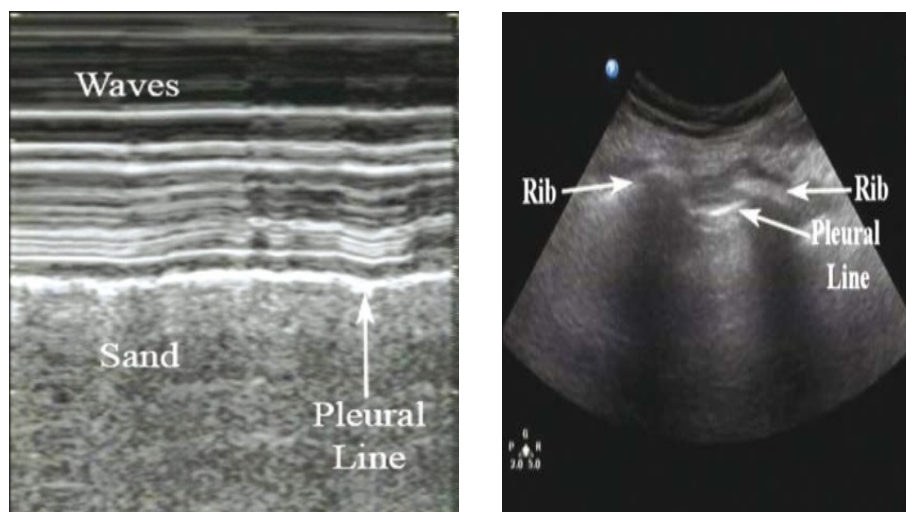


Figure 1. The bat sign (courtesy of Husain *et al.* J Emerg Trauma Shock. 2012).



Figure 2. “Stratosphere sign”: Parallel horizontal lines above and below the pleural line (courtesy of Husain LF *et al.* J Emerg Trauma Shock. 2012).

The negative predictive value for lung sliding is reported as 99.2% - 100% [5] [13] [14]. However, absence of lung sliding does not necessarily mean pneumothorax. Lung sliding is abolished in a variety of conditions including acute respiratory distress syndrome (ARDS), pulmonary fibrosis, large consolidations, pleural adhesions, atelectasis, and phrenic nerve paralysis [10] [15] [16]. Specificity ranges from 60% - 99% [5] [10] [13] [16].

“B-lines” or “comet-tail artifacts” are reverberation artifacts that appear as hyperechoic vertical lines that extend from the pleura to the edge of the screen without fading (**Figure 3**).

A few “B-lines” in dependent regions are expected in normal aerated lung [12]. Excessive “B-lines”, especially in the anterior lung, are abnormal and are usually indicative of interstitial edema [17] [18]. The negative predictive value for this artifact is high, reported at 98% - 100%, such that visualization of even one comet-tail essentially rules out the diagnosis of a pneumothorax. [5] [11] [19] “A-lines” are other important thoracic signs. These are also reverberation artifacts appearing as equally spaced repetitive horizontal hyperechoic lines reflecting off of the pleura (**Figure 4**). “A-lines” will be present in a patient with a pneumothorax [5].

The “lung-point sign” is due to sliding lung intermittently coming into contact with the chest wall during inspiration. This sign can further be delineated using M-mode where alternating “seashore” and “stratosphere” patterns are depicted over time (**Figure 5**).

The “lung-point sign” is 100% specific for pneumothorax [12] [20]. Although Lung point location can be a rough approximation of the volume of pneumothorax yet it is not a reliable tool [21] [22]. Although the specificity is high, the sensitivity of the “lung-point sign” is relatively low (reported at 66%) and is not seen in cases of total lung collapse [20].

The aim of this study is to analyze of ultrasound findings in patients with pneumothorax.

2. Patients and Methods

Fifty three patients were collected in single center from June 1 to August 10 2013. Inclusion criteria were a pneumothorax that is overt by CXR. Exclusion criteria were normal CXR and/or surgical emphysema in anterior chest wall.

Diagnosis of the cases were done by erect CXR (47 cases) and CT (6 cases) which was done when CXR was not conclusive or clinically indicated for further evaluation. The age of the patients ranged from (10 - 82 years), mean age 38 years, 34 were males and 19 were females. From 53 patients 106 hemithoraces were examined by US and divided into two groups: Control group (hemithorax with no pneumothorax) and pneumothorax group.

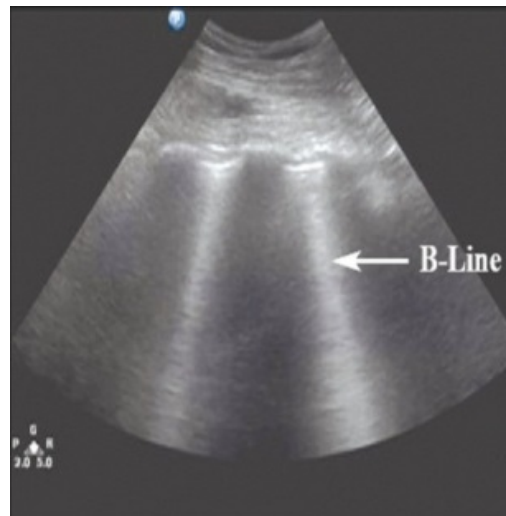


Figure 3. “B-lines” or “comet-tail artifacts” originating from pleural line, extending to the edge of the screen. (courtesy of Husain LF *et al.* J Emerg Trauma Shock. 2012).

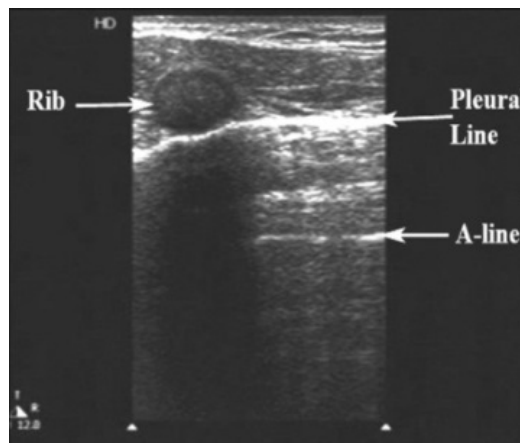


Figure 4. “A-lines”, a type of reverberation artifact, are horizontal, equally spaced lines. (courtesy of Husain LF *et al.* J Emerg Trauma Shock. 2012).

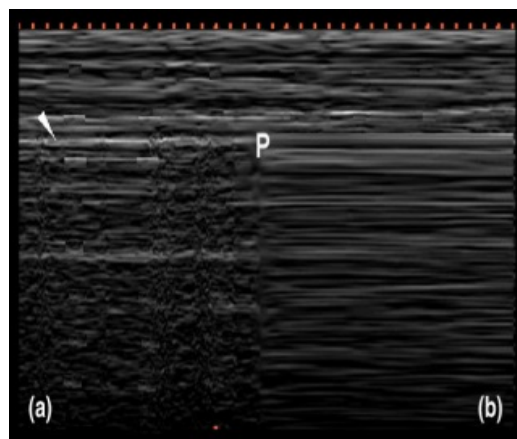


Figure 5. “Lung point sign” M-mode ultrasound (a) aerated lung showing seashore sign. (b) pneumothorax (stratosphere sign), (P) indicates point of transition. (courtesy of Husain LF *et al.* J Emerg Trauma Shock. 2012).

The patients were examined in the supine position with linear probe high frequency 5 MHz gray scale. The anterior chest wall was delineated by the sternum, the cupola, the anterior axillary line, and the clavulae. The anterior chest wall was divided into four zones. The lateral chest wall was delineated by the anterior and posterior axillary lines (**Figure 6**).

Each of those 6 zones were examined and lung sliding sign, lung point sign and A line sign were recorded. First dynamic movement of visceral pleura was observed by B-mode, then M-mode imaging was applied to objectify B-mode findings.

Data were converted into a Computerized data base structure. Static analysis were done using SPSS (Statistical Package of Social Sciences).

Formulas Used in Calculation

Sensitivity = Number of true positives/Number of diseased people Specificity = Number of true negatives/Number of non-diseased people PPV = Number of true positives/Number of positive test results NPV = number of true Negatives/Number of negative test results.

3. Results

Fifty three patients were enrolled in this study, mean age (38 years), 34 males (66%), 19 females (34%) (**Table 1** and **Table 2**). Causes were divided into 3 categories: trauma: 23 cases (43.3%), Iatrogenic 19 cases (35.8%) & spontaneous 11 cases (20.7%). Forty seven patients were diagnosed by CXR (88.6%), and 6 cases (11.3%) by CT scan. From those 53 cases, 2 patients had bilateral pneumothorax and 51 cases had unilateral pneumothorax. From 106 hemithorax, 55 were pneumothorax (51.8%) and 51 non pneumothorax (control) (47%) (**Table 3**).

4. Discussion

The ultrasound signs analyzed in the study were lung sliding sign, lung point sign and A line sign. The sensitivity, specificity, PPV and NPV of lung sliding sign in the diagnosis or exclusion of pneumothorax agreed with those reported in other studies as shown in **Table 4**.

Absent lung sliding was observed in all cases of pneumothorax and on 3 occasions in control group, from which 2 of them had fluid in the pleural cavity and one showed B line comet tail artifact due to interstitial edema from lung contusion. Hence this sign alone had sensitivity 100%, 94% specificity, 94% PPV and 100% NPV. Presence of lung sliding indicates normal lung (at the site of probe placement) and excludes pneumothorax [5] [14] [18] hence the high negative predictive value seen in the reviewed studies (**Table 4**). Lichtenstein DA *et al.* [5] reported results of sensitivity and specificity of absent LSS among 200 ICU patients to be 100% & 78% respectively and this was found in moderate agreement with results in this study, the explanation for this was

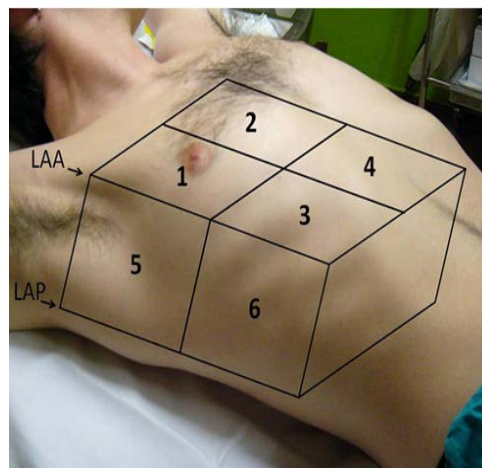


Figure 6. Systematic study of thoracic quadrants for pneumothorax diagnosis. The anterior (LAA) and posterior (LAP) axillary lines, midclavicularline, and a horizontal line passing through xiphisternum divided anterior hemithorax into six quadrants.

Table 1. Frequency of the signs in control and pneumothorax groups.

Group	Lung sliding sign positive	Lung point sign positive	A line sign positive
Control	48 (94.1%)	0 (0%)	20 (39.2%)
pneumothorax	0 (0%)	32 (58%)	53 (96%)

Table 2. True positive (TP), false positive (FP), true negative (TN) and false negative (FN) values of the sonographic signs.

Values	LSS	LPS	A line sign	LSS + LPS
TP	55	55	55	55
FP	3	0	20	0
TN	51	51	51	51
FN	0	23	2	23

Table 3. Sensitivity, specificity, positive predictive value (PPV) and negative predictive value (NPV) of sonographic signs.

Values	Absent LSS	Positive LPS	A line sign	Absent LSS + positive LPS
Sensitivity	100%	70.5%	96.4%	70%
Specificity	94.4%	100%	71.8%	100%
PPV	94.8%	100%	73%	100%
NPV	100%	68.9%	96%	68.9%

Table 4. Comparison of absent LSS findings with results reported in other studies.

Study	Sensitivity	Specificity	PPV	NPV
Dulchavsky <i>et al.</i> [16]	95%	100%		100%
Knudtson <i>et al.</i> [19]	92%	99.7%	92%	99.7%
Lichtenstein <i>et al.</i> [5]	100%	78%		
Sartori <i>et al.</i> [11]	87.5%	100%	100%	99.6%
Lichtenstein <i>et al.</i> [14]	95.3%	91.1%		100%
This study	100%	94%	94%	100%

found to be due to patient sample as in that study patients were all ICU patients who were critically ill and had abnormal lung parenchyma [5].

Lung point sign was never found in the control group & found in 32/55 pneumothoraces giving a specificity and PPV of 100%, this was in agreement with results reported by others [5].

Sensitivity of this sign was 70% which is found to be in agreement with results reported by Lichtenstein *et al.* [5], 66% & 79% respectively. LSS is sensitive but not specific for pneumothorax, LPS is specific for pneumothorax diagnosis. When the two signs combined, there was high degree of diagnostic accuracy among those who had the two signs in combination. A line sign had sensitivity, specificity, PPV and NPV of 91%, 71%, 73% and 91% respectively. Lichtenstein DA [5] reported sensitivity, specificity, PPV and NPV of 95%, 62%, 98% and 26% respectively among 200 ICU patients. this was found to be in fair agreement with results in this study. This may be due to patient sample as presence of B-lines in an ultrasound image due to unhealthy lung parenchyma degrade echoes forming A line artifact.

In this study it was found in both groups (control and pneumothorax) with higher frequency in pneumothorax group hence its presence alone does not indicate pneumothorax and it has to be correlated with other signs e.g. lung point to determine their significance.

Comet-tail artifacts are evoked only at the boundary between the visceral pleura and the aerated lung [22]. It follows that the presence of comet-tail artifacts excludes the diagnosis of pneumothorax. These artifacts are

sporadic in healthy lung and more numerous in diffuse parenchymal disease .in this study most of the control group showed a type of comet tails while none of pneumothorax showed comet tails and comet tails were considered with lung sliding therefore not analyzed statistically.

5. Conclusions

Ultrasound is a non invasivediagnostic tool for pneumothorax. Although lung sliding rules out pneumothora, absent lung sliding does not necessarily mean pneumothorax, but when present correlation with other signs should be made.

Focused Assessment with Sonography for Trauma should be extended to include the chest for pneumothorax diagnosis.

Acknowledgements

We would like to acknowledge all our personnel who assisted in serving our patients.

Conflict of Interest

The author declares that he has no competing interests.

Author's Contribution

Kawa. A. Mahmood: Study design, ultrasound scans, follow up.

Aram Baram: Surgeon performed the tube thoracostomies, study design, follow-up, data collection, statistical analysis.

Fahmi H. Kakamad: Study design, follow-up, data collection, statistical analysis.

Kosar K. Ahmad: Study design, follow-up, data collection, statistical analysis.

References

- [1] Noppen, M. and De Keukeleire, T. (2008) Pneumothorax. *Respiration*, **76**, 121-127. <http://dx.doi.org/10.1159/000135932>
- [2] Knudtson, J.L., Dort, J.M., Helmer, S.D. and Smith, R.S. (2004) Surgeon-Performed Ultrasound for Pneumothorax in the Trauma Suite. *Journal of Trauma*, **56**, 527-530. <http://dx.doi.org/10.1097/01.TA.0000114529.99353.22>
- [3] Husain, L.F. and Hagopian, L. (2012) Sonographic Diagnosis of Pneumothorax. *Journal of Emergencies, Trauma, and Shock*, **5**, 76-81. <http://dx.doi.org/10.4103/0974-2700.93116>
- [4] Monti, J.D., Younggren, B. and Blankenship, R. (2009) Ultrasound Detection of Pneumothorax with Minimally Trained Sonographers: A Preliminary Study. *Journal of Special Operations Medicine*, **9**, 43-46.
- [5] Lichtenstein, D.A., Meziere, G., Lascols, N., Biderman, P., Courret, J.P., Gepner, A., *et al.* (2005) Ultrasound Diagnosis of Occult Pneumothorax. *Critical Care Medicine*, **33**, 1231-1238. <http://dx.doi.org/10.1097/01.CCM.0000164542.86954.B4>
- [6] Tocino, I.M., Miller, M.H. and Fairfax, W.R. (1985) Distribution of Pneumothorax in the Supine and Semirecumbent Critically Ill Adult. *American Journal of Roentgenology*, **144**, 901-905. <http://dx.doi.org/10.2214/ajr.144.5.901>
- [7] Ball, C.G., Kirkpatrick, A.W., Laupland, K.B., Fox, D.L., Litvinchuk, S., Dyer, D.M., *et al.* (2005) Factors Related to the Failure of Radiographic Recognition of Occult Posttraumatic Pneumothoraces. *The American Journal of Surgery*, **189**, 541-546. <http://dx.doi.org/10.1016/j.amjsurg.2005.01.018>
- [8] Weissberg, D. and Refaely, Y. (2000) Pneumothorax: Experience with 1,199 Patients. *Chest*, **117**, 1279-1285. <http://dx.doi.org/10.1378/chest.117.5.1279>
- [9] De Luca, C., Valentino, M., Rimondi, M., Branchini, M., Baleni, M.C. and Barozzi, L. (2008) Use of Chest Sonography in Acute-Care Radiology. *Journal of Ultrasound*, **11**, 125-134. <http://dx.doi.org/10.1016/j.jus.2008.09.006>
- [10] Barillari, A. and Kiuru, S. (2010) Detection of Spontaneous Pneumothorax with Chest Ultrasound in the Emergency Department. *Internal and Emergency Medicine*, **5**, 253-255. <http://dx.doi.org/10.1007/s11739-010-0347-z>
- [11] Dulchavsky, S.A., Schwarz, K.L., Kirkpatrick, A.W., Billica, R.D., Williams, D.R., Diebel, L.N., *et al.* (2001) Prospective Evaluation of Thoracic Ultrasound in the Detection of Pneumothorax. *Journal of Trauma*, **50**, 201-205. <http://dx.doi.org/10.1097/00005373-200102000-00003>
- [12] Johnson, A. (2009) Emergency Department Diagnosis of Pneumothorax Using Goal-Directed Ultrasound. *Academic*

- Emergency Medicine*, **16**, 1379-1380. <http://dx.doi.org/10.1111/j.1553-2712.2009.00542.x>
- [13] Murphy, M., Nagdev, A. and Sisson, C. (2008) Lack of Lung Sliding on Ultrasound Does Not Always Indicate a Pneumothorax. *Resuscitation*, **77**, 270. <http://dx.doi.org/10.1016/j.resuscitation.2007.10.026>
- [14] Blaivas, M., Lyon, M. and Duggal, S. (2005) A Prospective Comparison of Supine Chest Radiography and Bedside Ultrasound for the Diagnosis of Traumatic Pneumothorax. *Academic Emergency Medicine*, **12**, 844-849. <http://dx.doi.org/10.1111/j.1553-2712.2005.tb00960.x>
- [15] Ball, C.G., Kirkpatrick, A.W. and Feliciano, D.V. (2009) The Occult Pneumothorax: What Have We Learned? *Canadian Journal of Surgery*, **52**, E173-E179.
- [16] Lichtenstein, D., Meziere, G., Biderman, P. and Gepner, A. (2000) The “Lung Point”: An Ultrasound Sign Specific to Pneumothorax. *Intensive Care Medicine*, **26**, 1434-1440. <http://dx.doi.org/10.1007/s001340000627>
- [17] Kirkpatrick, A.W., Sirois, M., Laupland, K.B., Liu, D., Rowan, K., Ball, C.G., *et al.* (2004) Hand-Held Thoracic Sonography for Detecting Post-Traumatic Pneumothoraces: The Extended Focused Assessment with Sonography for Trauma (EFAST). *Journal of Trauma*, **57**, 288-295. <http://dx.doi.org/10.1097/01.TA.0000133565.88871.E4>
- [18] Lichtenstein, D.A. and Menu, Y.A. (1995) Bedside Ultrasound Sign Ruling out Pneumothorax in the Critically III: Lung Sliding. *Chest*, **108**, 1345-1348. <http://dx.doi.org/10.1378/chest.108.5.1345>
- [19] Soldati, G., Testa, A., Sher, S., Pignataro, G., La Sala, M. and Silveri, N.G. (2008) Occult Traumatic Pneumothorax: Diagnostic Accuracy of Lung Ultrasonography in the Emergency Department. *Chest*, **133**, 204-211. <http://dx.doi.org/10.1378/chest.07-1595>
- [20] Gobien, R.P., Reines, H.D. and Schabel, S.I. (1982) Localized tension Pneumothorax: Unrecognized Form of Barotrauma in ARDS. *Radiology*, **142**, 15-19. <http://dx.doi.org/10.1148/radiology.142.1.7031759>
- [21] Rowan, K.R. and Kirkpatrick, A.W. (2002) Traumatic Pneumothorax Detection with Thoracic US: Correlation with Chest Radiography and CT—Initial Experience. *Radiology*, **225**, 210-214. <http://dx.doi.org/10.1148/radiol.2251011102>
- [22] Reissig, A. and Kroegel, C. (2000) *Transthoracic Sonography: Principles and Applications*. Thieme, New York.