

Tropical Coronary Artery Disease and Arrhythmogenic Potentials—The Changing Pattern towards Endomyocardial Fibrosis—An Analysis

Ramachandran Muthiah

Zion Hospital, Azhagiemandapam, Kanyakumari District, India

Email: cardioramachandran@yahoo.co.uk

How to cite this paper: Muthiah, R. (2018) Tropical Coronary Artery Disease and Arrhythmogenic Potentials—The Changing Pattern towards Endomyocardial Fibrosis—An Analysis. *Case Reports in Clinical Medicine*, 7, 397-429.
<https://doi.org/10.4236/crcm.2018.76036>

Received: May 17, 2018

Accepted: June 19, 2018

Published: June 22, 2018

Copyright © 2018 by author and Scientific Research Publishing Inc. This work is licensed under the Creative Commons Attribution International License (CC BY 4.0).

<http://creativecommons.org/licenses/by/4.0/>



Open Access

Abstract

Aim: To analyse the increasing burden of coronary artery disease (CAD) in tropical and subtropical belts of the Equator since it remains blurred and carries a grim prognosis. **Introduction:** Endomyocardial fibrosis [EMF] is a tropical febrile disorder, confined to peculiar and limited geographical areas. Plaque buildup in endocardium and coronary arteries, causing ischemic injury and arrhythmic episodes, is a vanishing mystery in its pathogenesis and emphasizing alternative routes for understanding and treatment of this enigmatic disease. **Case Report:** 15 cases in various age groups were reported with potential complications of coronary artery disease and arrhythmias, associated with endocardial lesions, the characteristic feature of endomyocardial fibrosis. **Conclusion:** The narrowing of coronary arteries as a result of thickening of the walls, spasm, inflammation, plaques and its rupture produce ischemic episodes which can occur slowly or suddenly in a devastating pattern with arrhythmogenic potentials. The important steps to prevent and decrease the risk of CAD is to reduce the chance of getting this disorder by epidemiological measures with an advice of blood thinning medications such as small daily dose aspirin, antibiotics in susceptible individuals and revascularization in established myocardial infarction.

Keywords

Endomyocardial Fibrosis, Endocardial Plaques, Egg-Cell Calcification (Endocardial), Arrhythmias, Ischemic Injury, Newer Therapeutic Strategies, RAS Vaccine

1. Introduction

Coronary artery disease (CAD) remains the most common etiology for high morbidity and mortality worldwide. The worldwide burden is set to reach 47 million affected individuals by the year 2020 as projected by World Health Organization (WHO) [1]. The understanding of pathophysiology of coronary artery disease had led to a decrease in the mortality towards the turn of the 20th century [2]. There has been a greater focus in research aimed at all aspects of CAD in the last decade. The INTERHEART-South Asia study identified that the risk factors like abdominal obesity, smoking, hypertension, diabetes, psychosocial factors and lack of physical activity are more in urban areas and contribute for 89% of acute myocardial infarction in Indians.

The rising incidence of CAD is a new phenomenon in developing countries. Several Western studies have demonstrated a significant role of various nutrients like fat, saturated fat and cholesterol in the causation of CAD [3] [4]. In contrast, the traditional Indian diet is low in fat content and, therefore cannot be the sole cause for the high prevalence of CAD in Indians. The findings of genome-wide association studies provide insights on the genetic architecture of coronary artery disease and the first common susceptible locus for CAD was identified at 9p21 [5]. Among the modifiable risk factors, consumption of coconut and its oil contain high amount of saturated fat, thought to be highly atherogenic, but a recent study states that there is no specific role of coconut in the causation of CAD [6].

Recently, an increase in the incidence of CAD was reported from southern states of India and other etiologies, the infectious or inflammatory conditions such as Endomyocardial fibrosis may provide an insight in its analysis and so these cases had been reported.

2. Case Reports

Case 1.

A 65 years old female was admitted with sudden onset of tachycardia as shown in **Figure 1**, which revealed a narrow QRS tachycardia and responded to intravenous adenosine as in **Figure 2**. Echocardiography revealed “egg-shell” pattern of endocardial calcification in left ventricle (LV) as shown in **Figure 3**, suggesting left ventricular EMF (Endomyocardial fibrosis) and M-mode LV study revealed hypokinesia of left ventricular posterior wall with moderate LV dysfunction (EF-41%) as in **Figure 4**. Patient was treated with anticoagulants, antiplatelets, nitrates, statins, amiodarone 100 mg daily with azithromycin 500 mg weekly for 6 months.

Case 2.

A 45-year-old male was admitted with sudden onset of chest discomfort and ECG revealed ST-depression in precordial leads as in **Figure 5**. Blood chemistry revealed normal lipid profile with elevated C-reactive protein (hs (high sensitive)-CRP 6 mg/L (normally not detectable in blood), >10 mg/L indicates acute

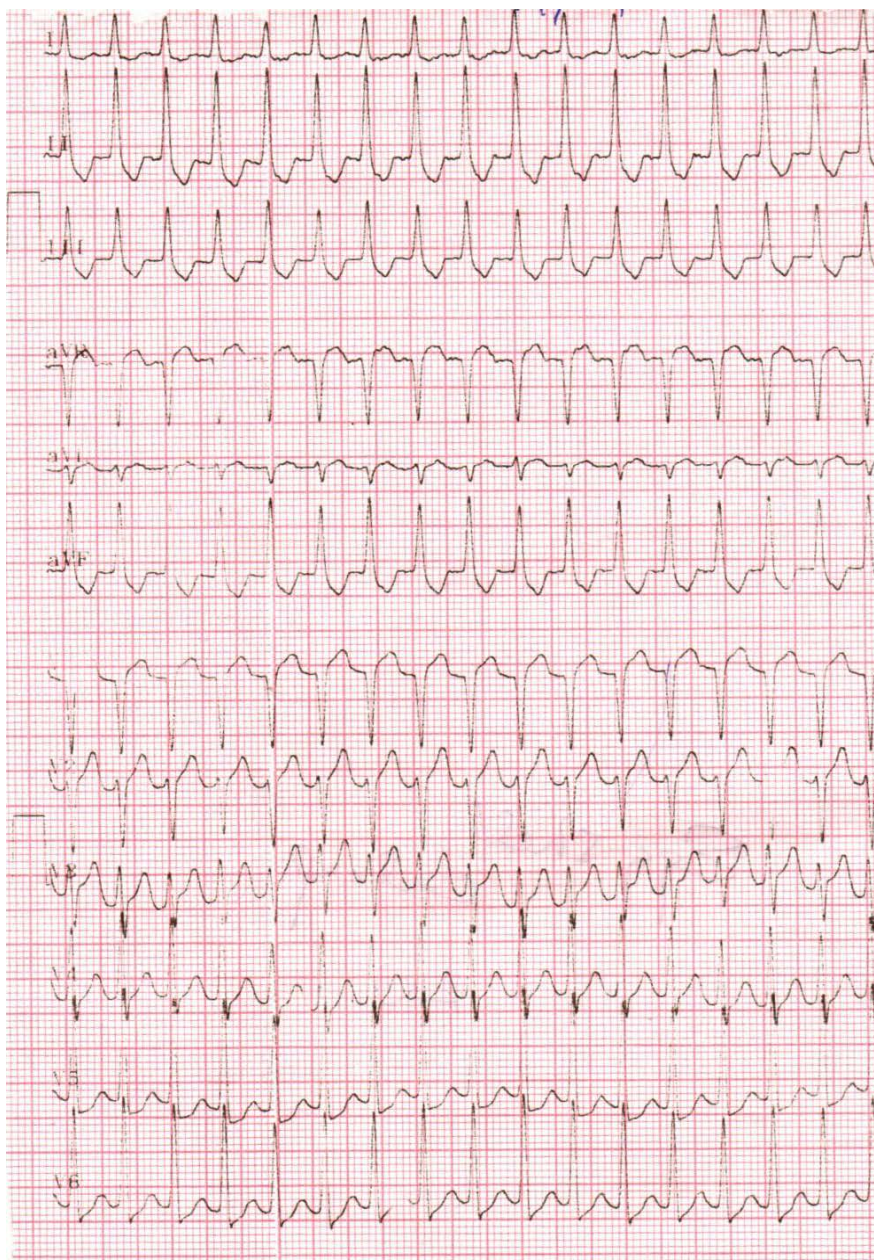


Figure 1. Showing narrow QRS tachycardia.

plaque rupture in CAD cases). Patient was treated with heparin, dual antiplatelet agents (aspirin, clopidogrel), nitrates and statins for 5 days and ECG reverted to normal as in **Figure 6**. Echocardiography revealed calcified fibrous tissue in interventricular septum (IVS) and left ventricular apex as in **Figure 7**. Patient was advised periodic follow up with the continuation of medications.

Case 3.

A 42 years old male was admitted with sudden onset of chest discomfort for 3 hours duration. ECG revealed acute anterior wall infarction as shown in **Figure 8**. The patient was thrombolysed with streptokinase and further treated with anticoagulants, nitrates, antiplatelets and statins for 5 days. The patient remains

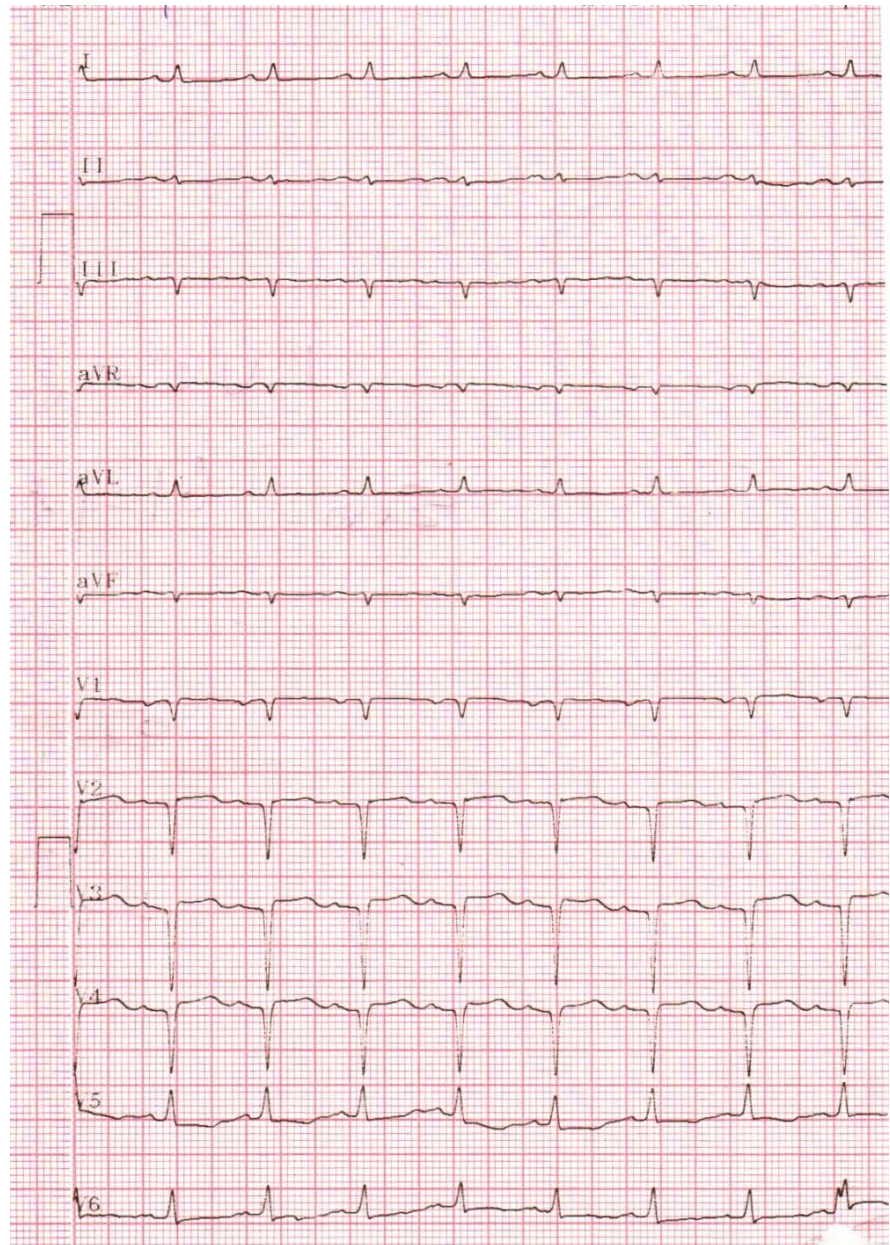


Figure 2. Showing the reverted sinus rhythm with 6 mg intravenous adenosine and a QS pattern in V_1 - V_4 , suggesting an old anterior myocardial infarction.

symptom free and echocardiography revealed RV (right ventricle) apical fibrosis as in **Figure 9** and hypokinesia of interventricular septum as shown in **Figure 10**. The patient was referred for revascularization procedures.

Case 4.

A 4-year-old female child was referred for cardiac evaluation since her pulse rate was <60 bpm. ECG revealed complete heart block as shown in **Figure 11** and it was initially thought of congenital in origin, but echocardiography revealed a plaque like lesion in right ventricular apex as in **Figure 12**. The child was treated with cefotaxime 250 mg three times daily for one week and the heart

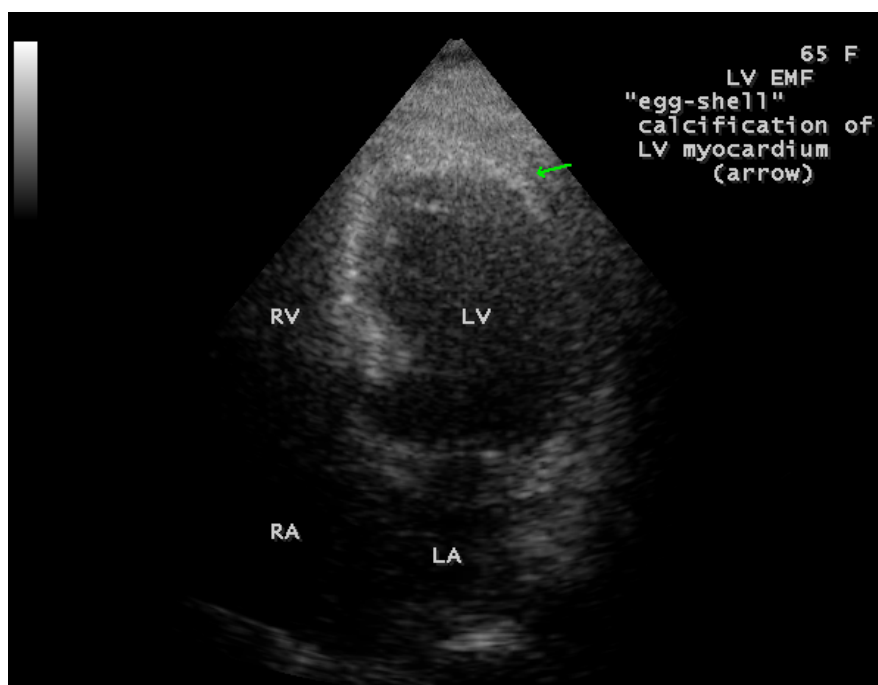


Figure 3. Showing the “egg-shell” calcification of Left ventricle (LV) (arrow), suggesting LV EMF (Endomyocardial fibrosis).

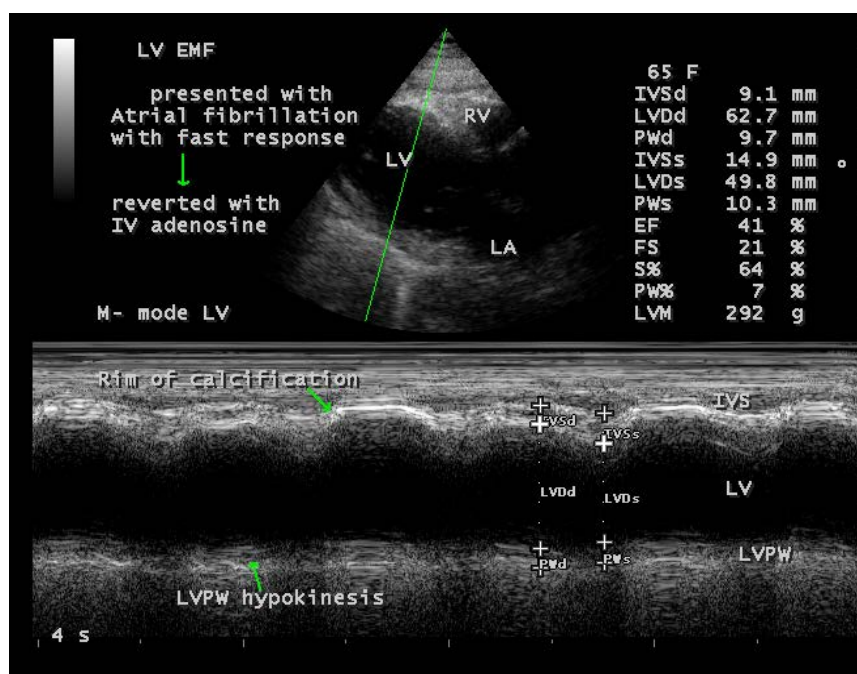


Figure 4. The M-mode LV study (green line) showing the rim of IVS (interventricular septum) calcification (upper arrow) and hypokinesis of LV (left ventricle) posterior wall (lower arrow) with LV dysfunction (EF-41%).

rate seemed to be increased as in **Figure 13**. The child was advised further follow up with a continuation of tablet deriphyllin 100 mg daily to increase the heart rate.

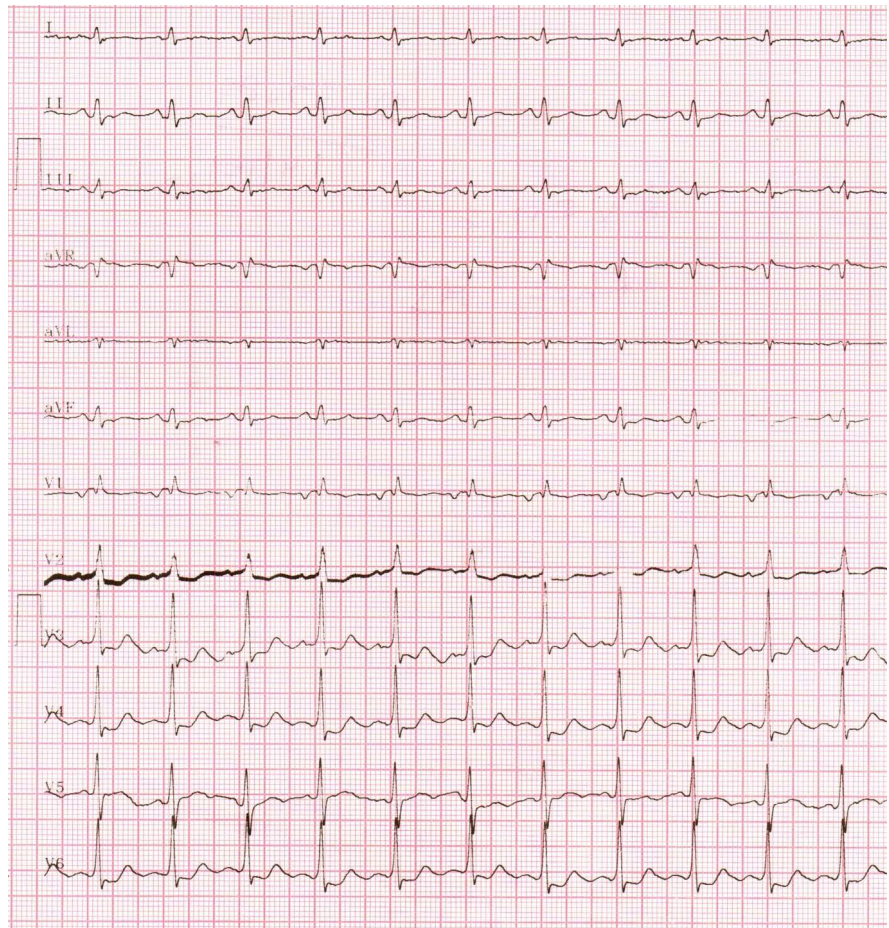


Figure 5. ECG showing ST depression in precordial leads (NSTEMI).

Case 5.

A 15-year-old female was presented with anginal episodes with ECG changes of T-inversion in V_1 - V_3 and echocardiography revealed apical fibrosis in right ventricle suggesting EMF as in **Figure 14**. She was on nitrates, antiplatelet agents, statins and azithromycin 500mg weekly.

Case 6—showing plaque like lesions in IVS (interventricular septum) with ST-T changes in a 78-year-old female as shown in **Figure 15** and advised nitrates, antiplatelet agents, statins and azithromycin 500 mg weekly.

Case 7. A 60-year-old male presented with acute myocardial infarction and echocardiography revealed IVS (interventricular) calcification as in **Figure 16** and revascularized with PCI (percutaneous coronary intervention).

Case 8. 52-year-old male presented with anginal episodes and echocardiography revealed finger-like projections of LV myocardium as in **Figure 17**. The patient was advised blood-thinning medications (low dose aspirin 75 mg daily), statins and nitrates.

Case 9. A 60-year-old female was admitted with sudden onset of tachycardia and echocardiography revealed “egg-shell” calcification of right ventricular myocardium as in **Figure 18**. The patient was treated with verapamil 40 mg

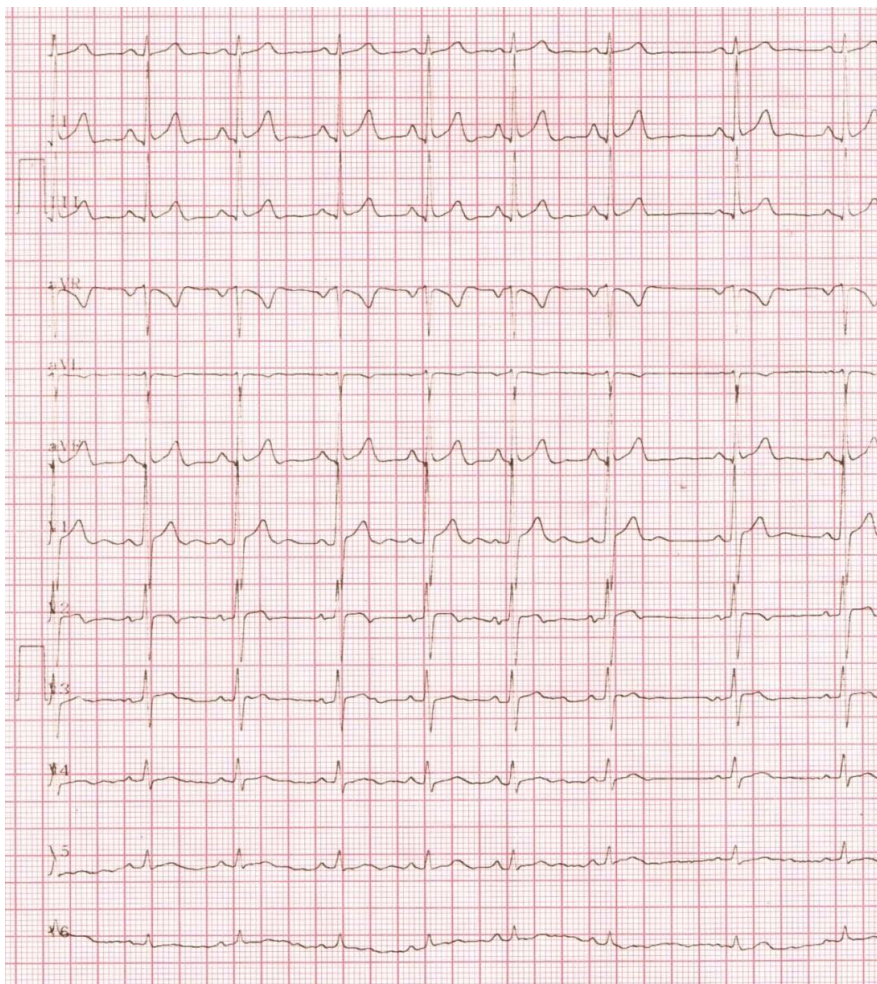


Figure 6. ECG normalizing after 5 days course of heparin therapy.

three times daily and the rhythm was controlled.

Case 10. A 60-year-old male presented with sinus bradycardia revealed endocardial plaques in interventricular septum (IVS) as in **Figure 19**. The patient was treated with amoxicillin and deriphyllin for 10 days and the rhythm was restored to normal.

Case 11. A 28-year-old female having infertility for a period of 5 years revealed interatrial septal (IAS) calcification suggesting EMF as in **Figure 20**.

Case 12. A 25-year-old male presented with anginal episodes, having elevated CK-MB and C-reactive protein levels, but the ECG remain normal and echocardiography revealed RV apical fibrosis as in **Figure 21**.

Case 13. Showing plaque like lesion in a neonate as in **Figure 22**, presented with atrial fibrillation (fast response) and reverted with intravenous adenosine

Case 14. Showing a thrombotic lesion in LV apex in a 55-year old male as in **Figure 23**.

Case 15. A 66-year-old female presented with RV EMF and rheumatic mitral valve involvement as shown in **Figure 24** and **Figure 25** and was advised penicillin prophylaxis with periodic follow up.

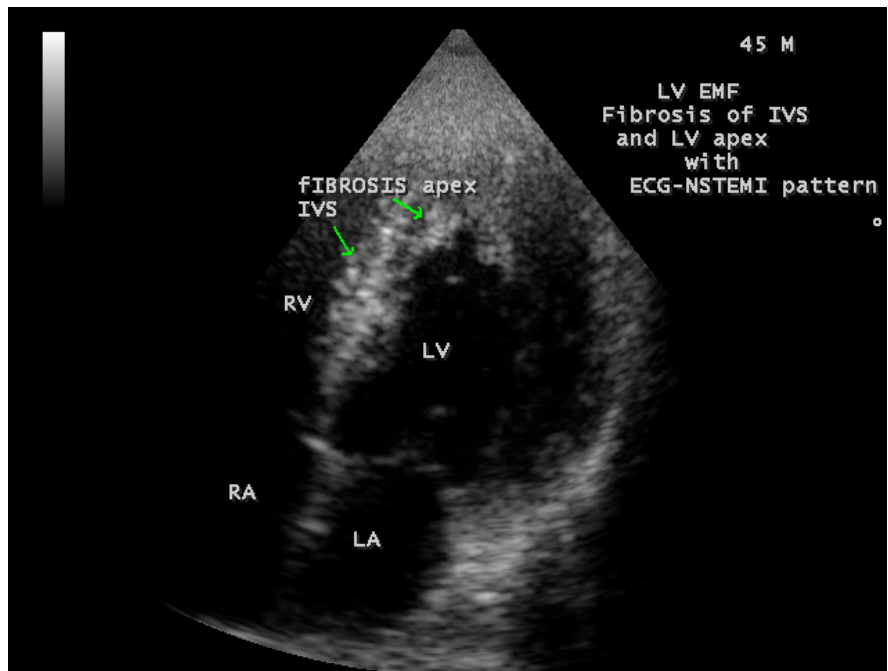


Figure 7. Showing the fibrosis in IVS (interventricular septum) and LV apex (arrows).

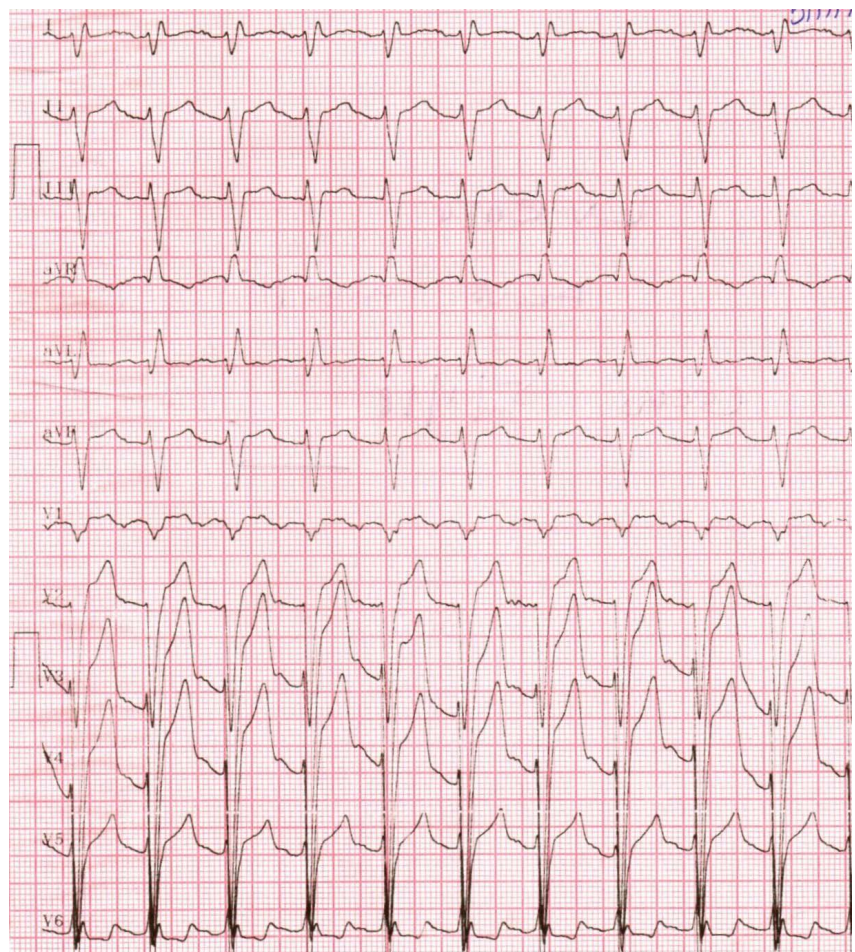


Figure 8. ECG revealed acute anterior wall myocardial infarction.

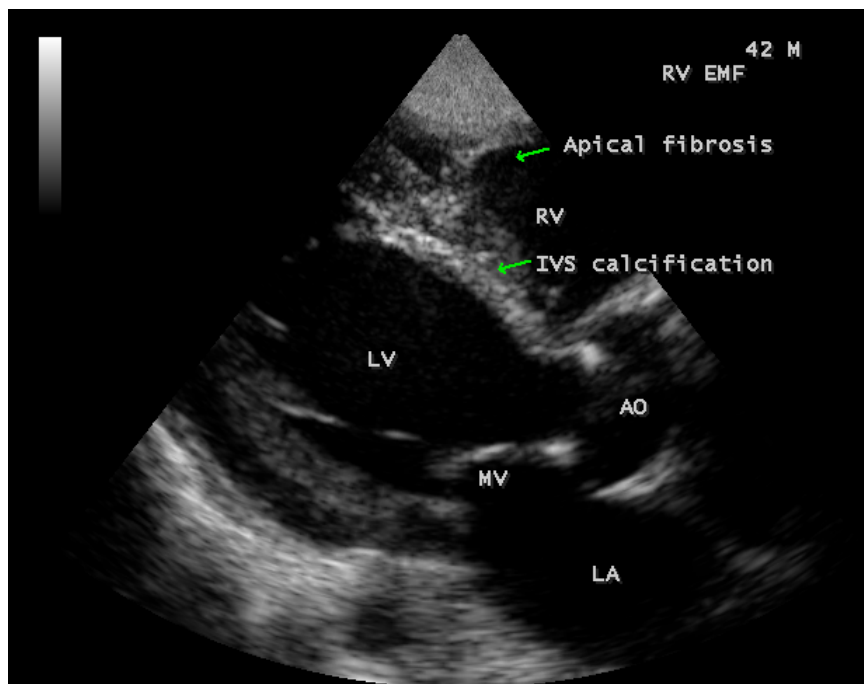


Figure 9. Showing IVS (interventricular septum) calcification (lower arrow) and RV (right ventricle) apical fibrosis (upper arrow).

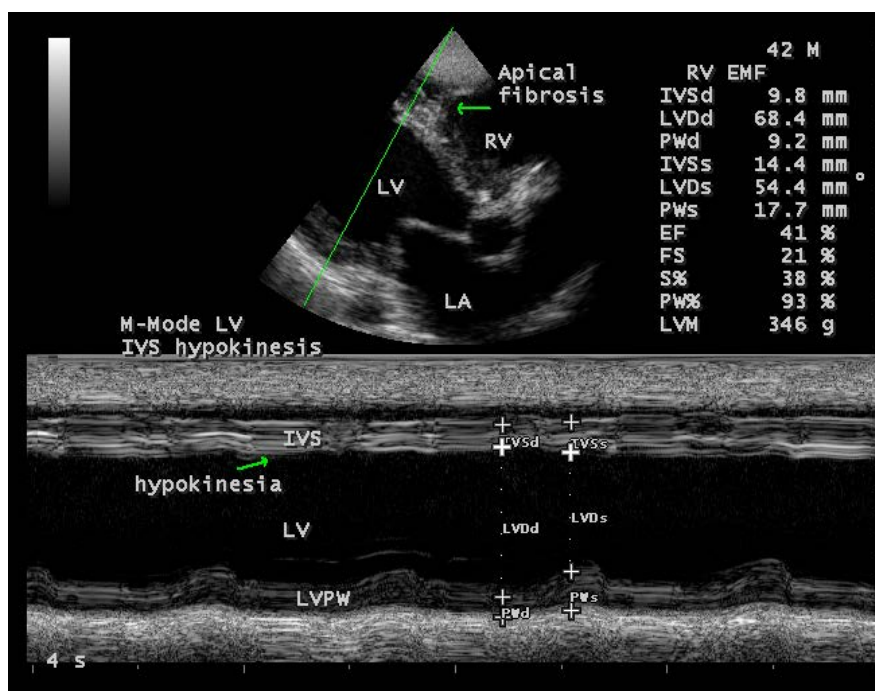


Figure 10. M-mode LV study (green line) showing hypokinesia of IVS (interventricular septum) (lower arrow) with RV apical fibrosis (upper arrow).

3. Discussion

3.1. Review of Literature

It is interesting to note that almost 57 years ago, Allan Charters described a high

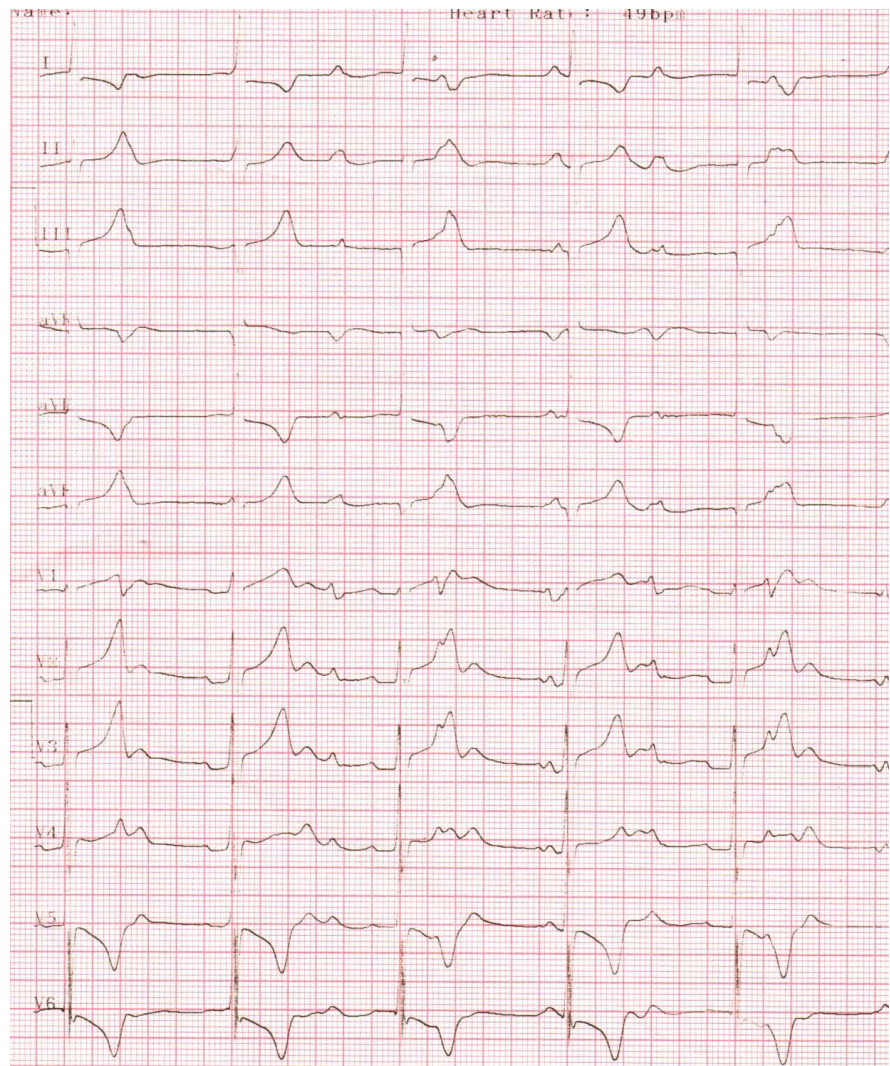


Figure 11. ECG showing complete heart block (heart rate 50 bpm) in a 4-year old female child.

incidence of coronary artery disease among expatriate Indians in Kenya and he believed that the ingestion of animal fat was not an important etiological factor [7] [8]. Virchow, first proposed an association between infection and IHD (ischemic heart disease) > 100 years ago. Cardiotropic viruses were first implicated in the pathogenesis of CAD in 1968 when experimental Coxsackie B₄ virus infection in mice was shown to produce acute coronary arteritis [9]. Other investigators suggest a link between Coxsackie B virus and coronary artery disease, following a report of myocardial infarction, occurring in two normolipidemic male patients due to an unknown viral illness [10].

3.2. Etiopathogenesis

Atherosclerosis is the main pathological process involved in CAD and it provides the first hints of potential infectious cause, with its characteristic inflammatory cell infiltrate in the lipid streaks seen in some children and young adults.

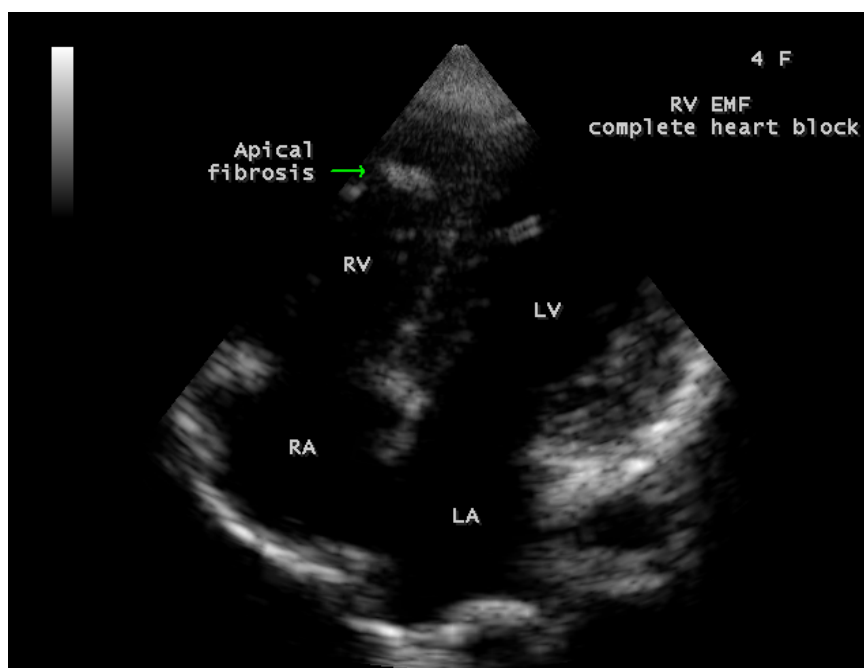


Figure 12. Showing endocardial plaque-like lesion (apical fibrosis) in the RV (right ventricular) apex (arrow) in a 4-year-old female child with complete heart block.

The inflammatory nature of early cellular infiltrate suggest that either infection or autoimmune phenomena with viruses, bacteria and non-viral obligatory intracellular parasites, all being implicated as potential precipitants of the atherosclerotic process. Bacterial infection may lead to molecular sequelae that might have effects on the initiation and maintenance of atherosclerotic process. During infection, plasma clotting factors increases, leading to a hypercoagulable state with an increase in procoagulant activity at the level of vascular endothelium and a shift of prostaglandin metabolism towards thrombosis [11] [12]. Increased addition of circulating leucocytes to the vascular endothelium also occurs. Of particular interest are the changes in lipid metabolism during acute infection as serum triglycerides and VLDL (very low density lipoproteins) levels increase with levels of LDL (low density lipoprotein)-cholesterol and HDL (high density lipoproteins) decreasing concomitantly [13] and the endothelium is damaged directly by lipopolysaccharide [14]. The lipopolysaccharide also affects the circulating and tissue macrophages to produce free radicals, which are known to oxidize the LDL. The oxidized LDL transforms macrophages into “foam cells” and these foamy macrophages are prominent in the early lesions of atherosclerotic process. Viruses such as herpes simplex-II, cytomegalovirus and Epstein-Barr virus exhibit transforming abilities in vascular smooth muscle cells in atherosclerotic plaques [15], leading to smooth muscle proliferation with subsequent intimal thickening, luminal narrowing and endothelial degeneration. The severity of these changes are influenced by factors that include smoking, hypertension, diabetes, dyslipidemia and age, results in varying degrees of ischemic manifestations in coronary vasculature.

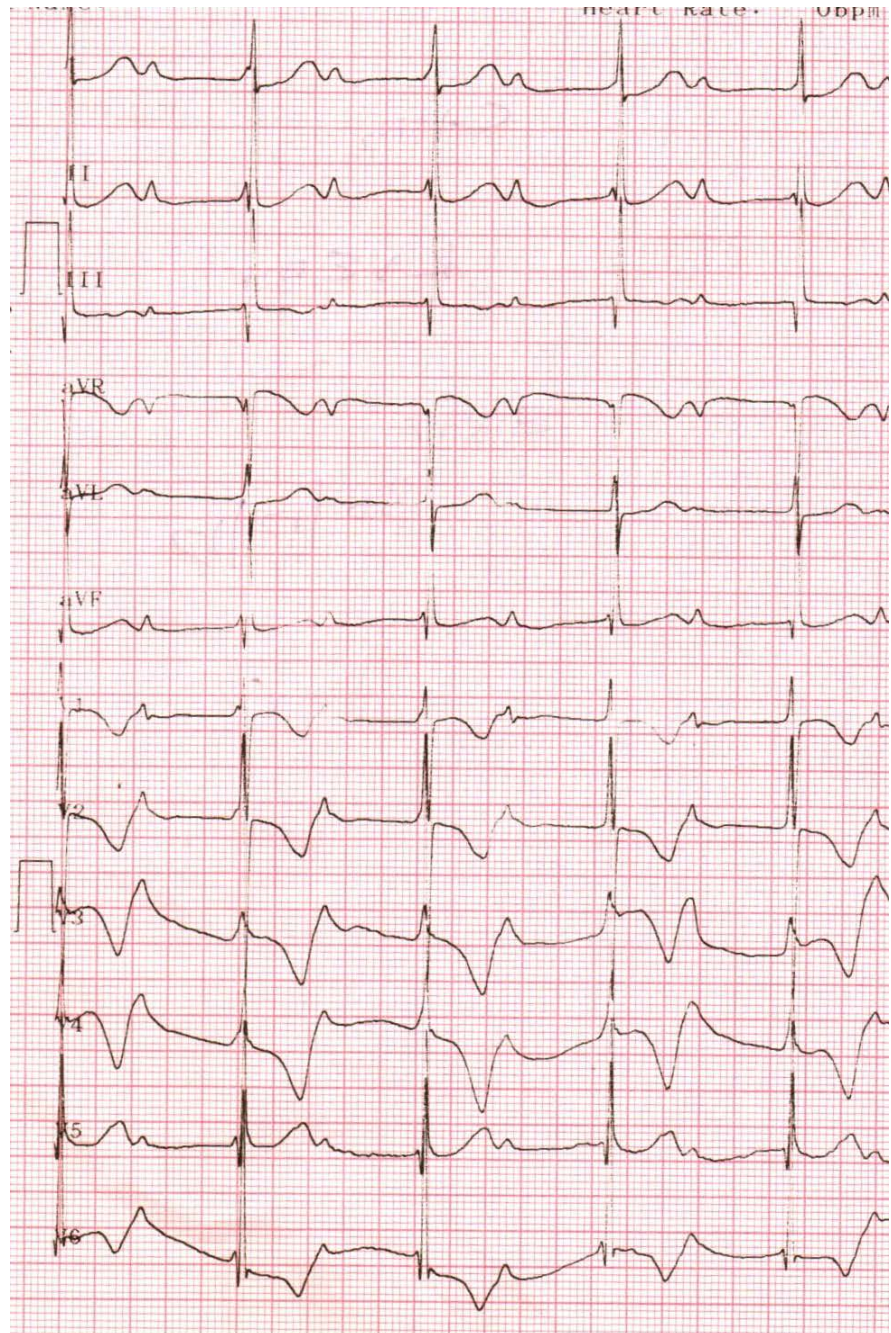


Figure 13. ECG showing the increase in heart rate (60 bpm) after cefotaxime therapy.

Recent febrile illness has been associated significantly with myocardial infarction [16]. The individuals having seropositive for *C. pneumoniae* and *H. pylori*, shown to possess elevated levels of fibrinogen, a risk factor for CAD. C-reactive protein (CRP), an another acute-phase protein, when present at levels approaching the upper limit of normal, is an indirect evidence of CAD [17] and correlate with poor prognosis in unstable angina [18]. However, high levels of acute-phase proteins mean inflammation, but chronically stressed myocardium may also induce an acute inflammatory response.

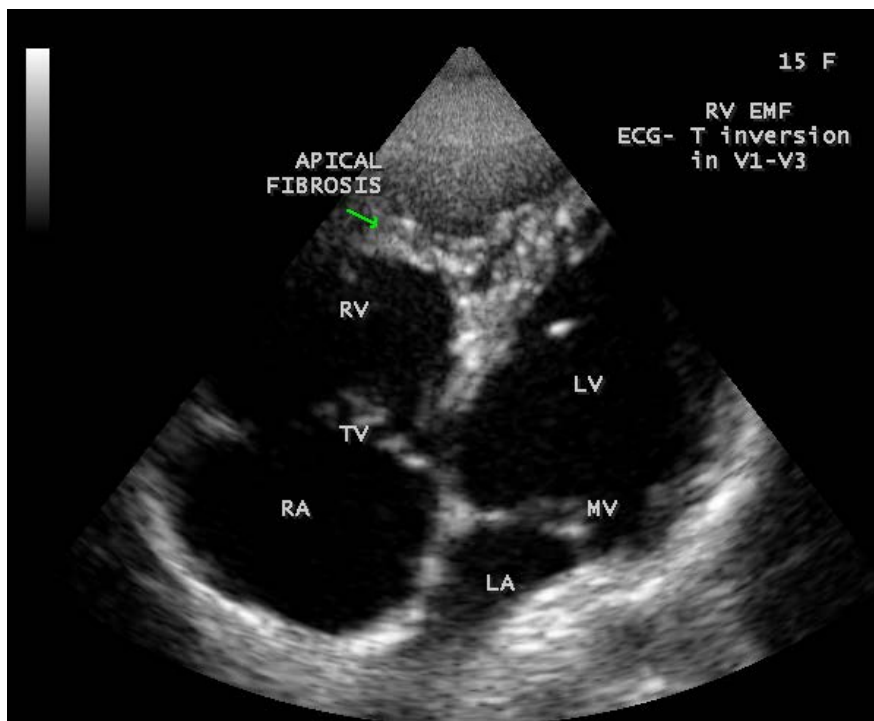


Figure 14. Showing apical fibrosis in the right ventricle (arrow).

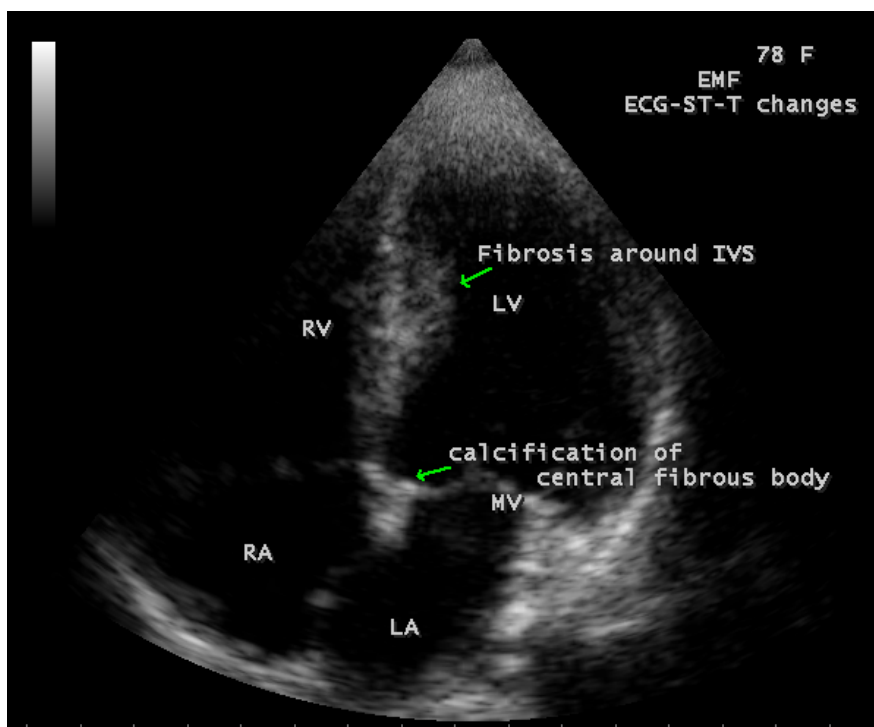


Figure 15. Showing the plaque-like lesion in IVS (interventricular septum) (upper arrow).

Endomyocardial fibrosis is the reaction of endocardium to various insults, mainly of infectious origin and causing damage to the endothelial lining of heart,

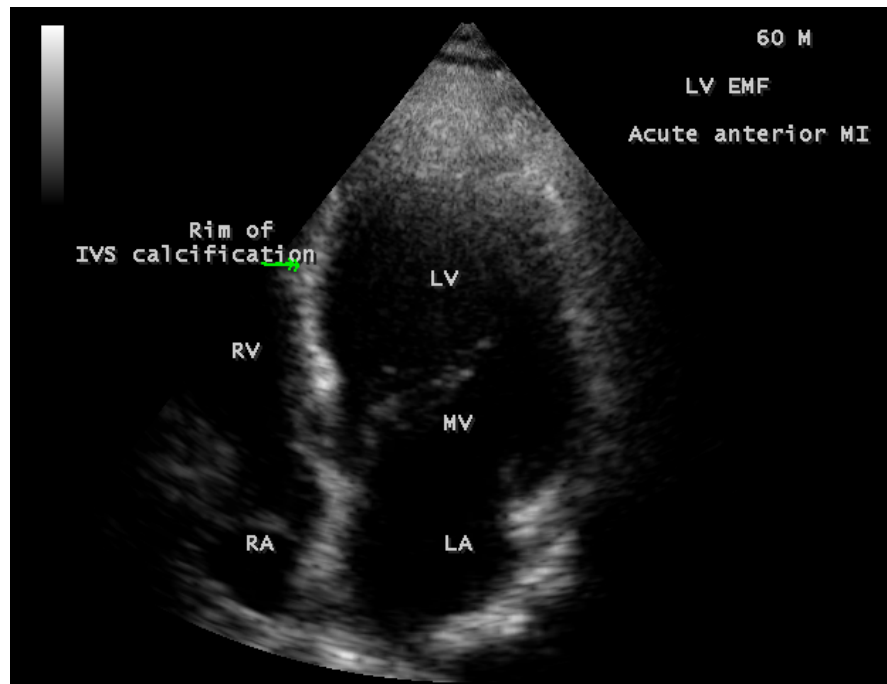


Figure 16. Showing IVS (interventricular septum) calcification (arrow) in a 60-year-old male.

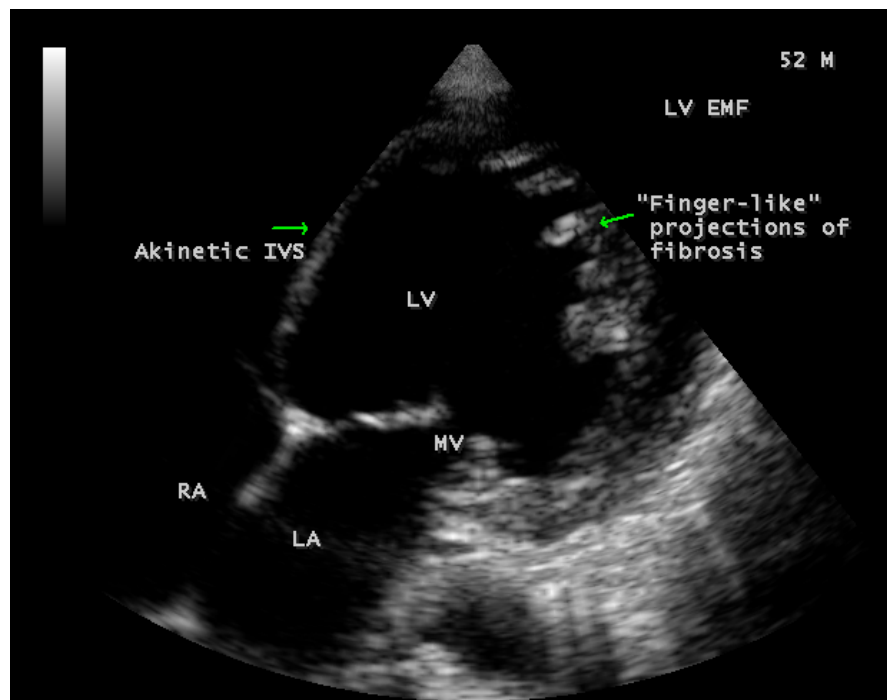


Figure 17. Showing the finger-like projections of fibrosis (left arrow).

blood vessels, serous cavities and it is immunologically mediated similar to rheumatic process, sometimes coexist in the same individual as in **Figure 24** and **Figure 25**. It may leads to replacement of normal cells with fibrous tissue and the distribution of fibrosis in the ventricle varies as shown in **Table 1**.

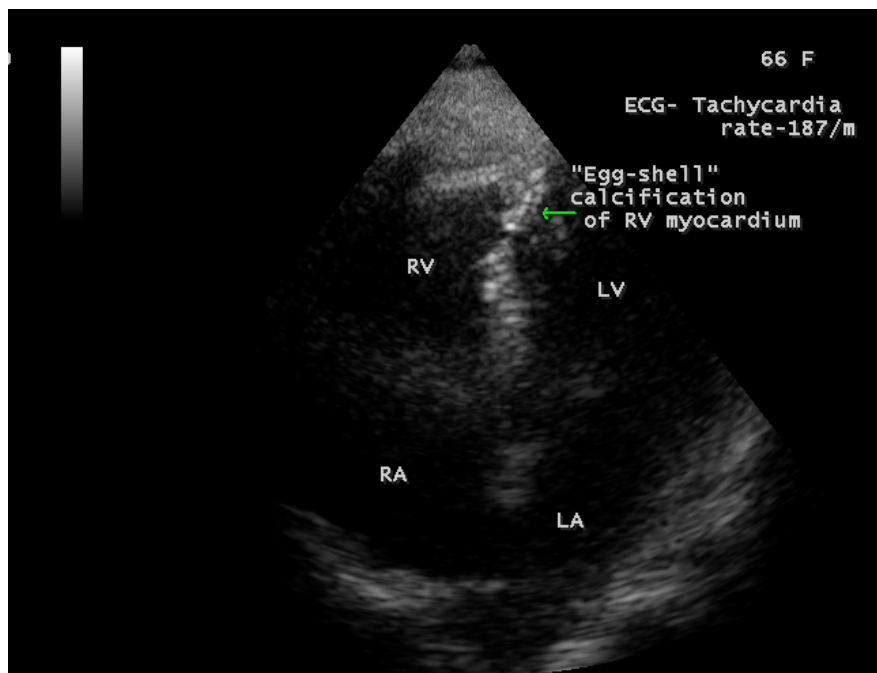


Figure 18. Showing “egg-shell” calcification of RV (right ventricle) myocardium (arrow).

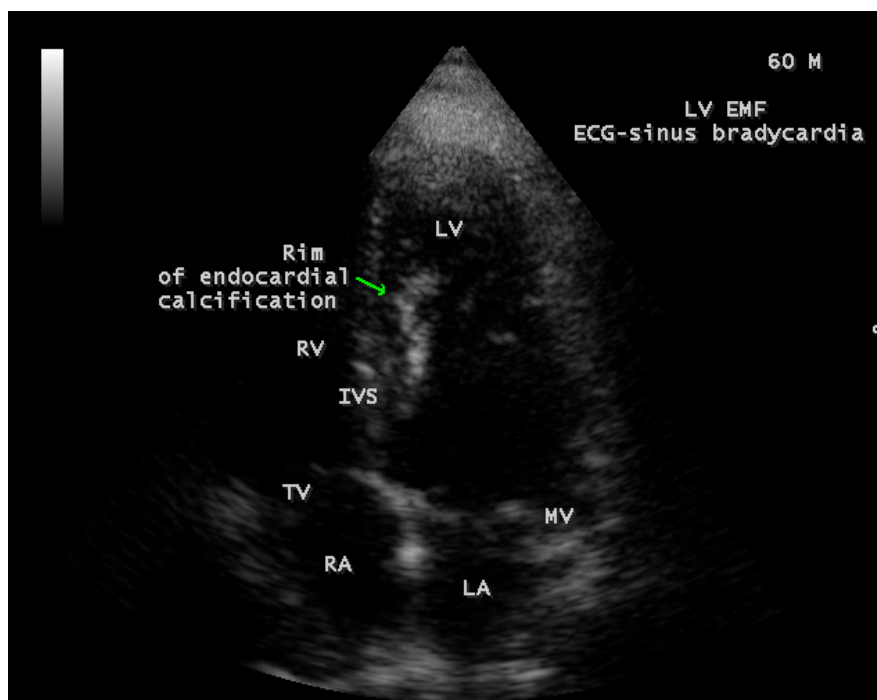


Figure 19. Showing endocardial plaque like lesion in IVS (interventricular septum) (arrow).

The acute phase of Endomyocardial fibrosis (EMF), characterized by generalized allergic/immunological features, starts with a febrile illness associated with “pancarditis” or “myopericarditis”, dyspnea, itching, urticaria, abdominal distension, facial or periorbital swelling (unilateral periorbital swelling (Romanas sign

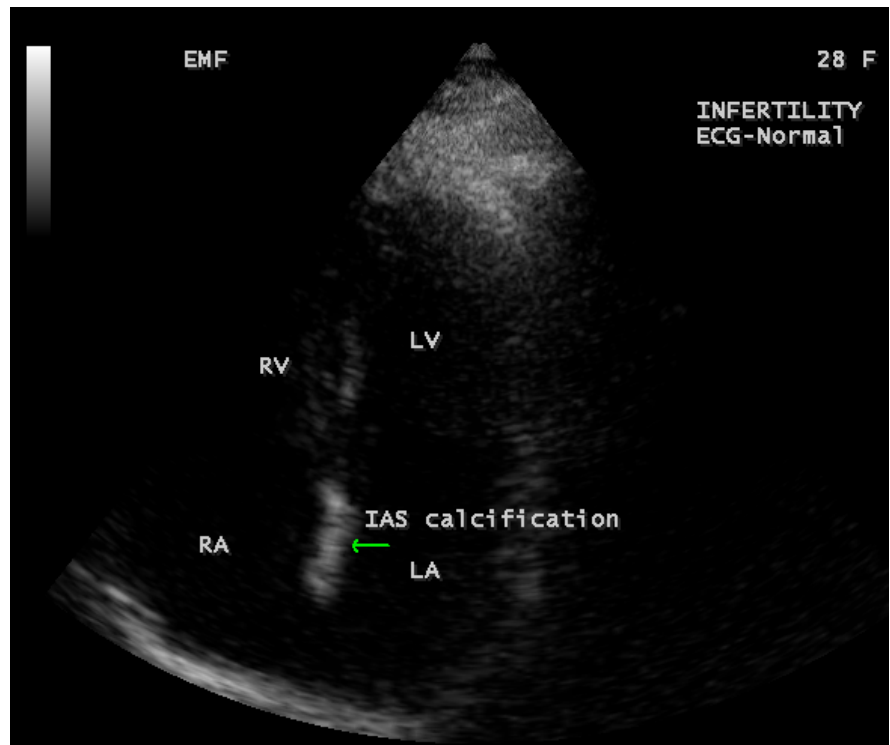


Figure 20. Showing the calcification of interatrial septum (IAS) (arrow) in a 28-year-old female having infertility.

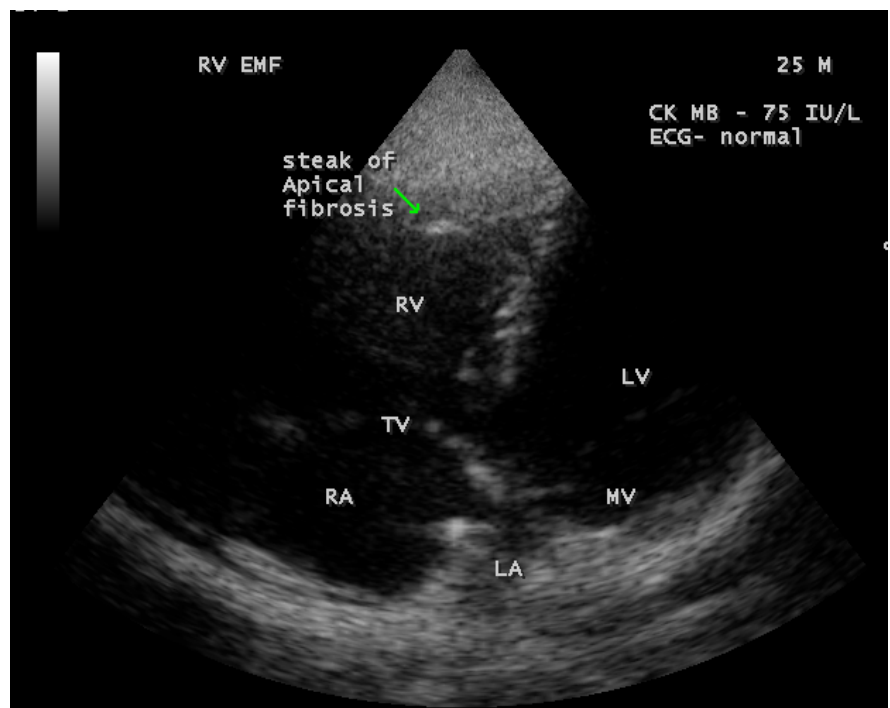


Figure 21. Showing streaks of apical fibrosis in RV apex (arrow) in a 25-year-old male.

characteristic of Chagas disease), parotid involvement and neurological features with increased pigmentation of lips. This “acute inflammation of the heart” [21]

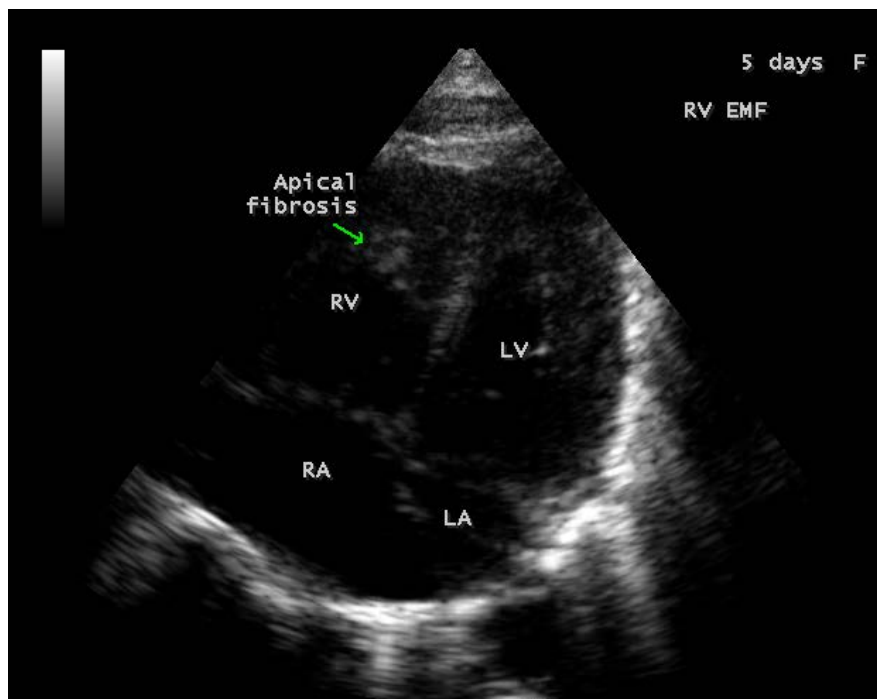


Figure 22. Showing plaque-like lesion in RV apex (arrow) in a neonate.

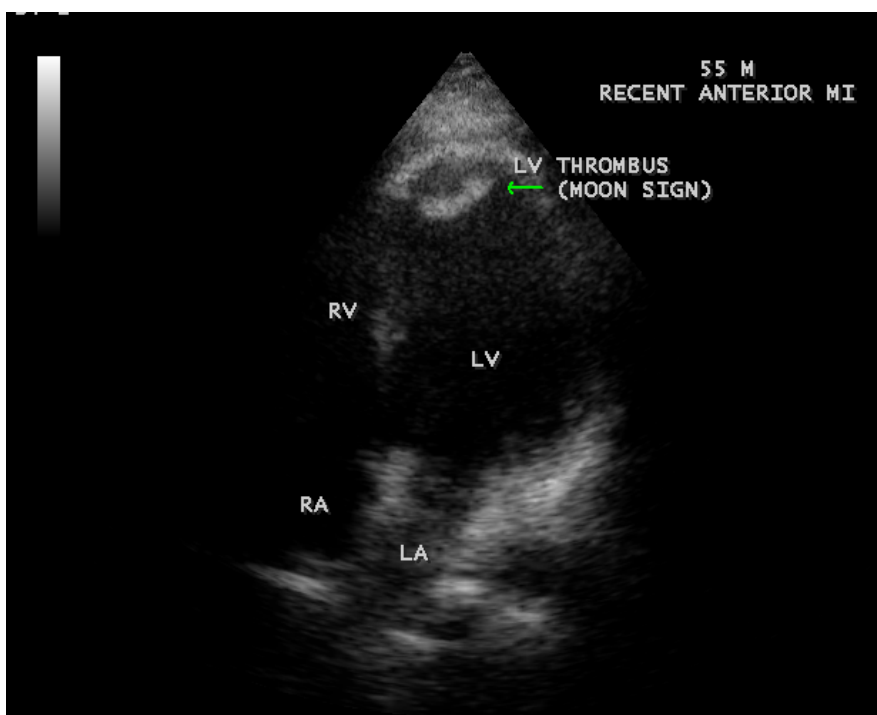


Figure 23. Showing a thrombotic lesion at LV apex (arrow) in a 55-year-old male.

[22] results in myocardial damage, vasculitis with ECG changes of ischemia [23], infarction, conduction disturbances, atrial or ventricular arrhythmias [24] and atrial fibrillation occurs in >30% of cases [25]. This acute phase of EMF is poorly understood, incompletely described and its clinical distinction from rheumatic

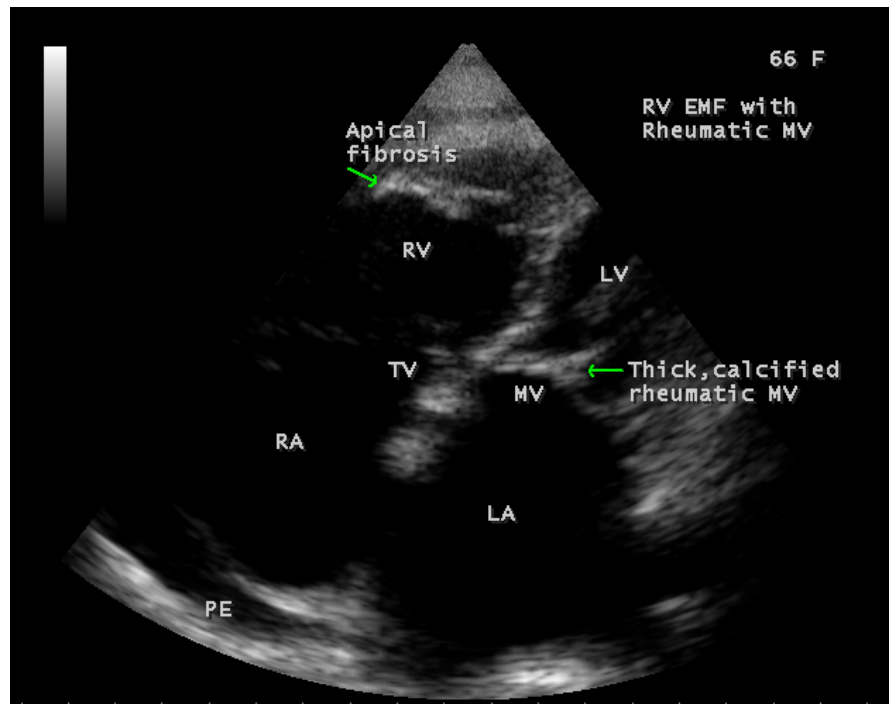


Figure 24. Showing fibrosis of RV apex (upper arrow) and anterior mitral leaflet (lower arrow).

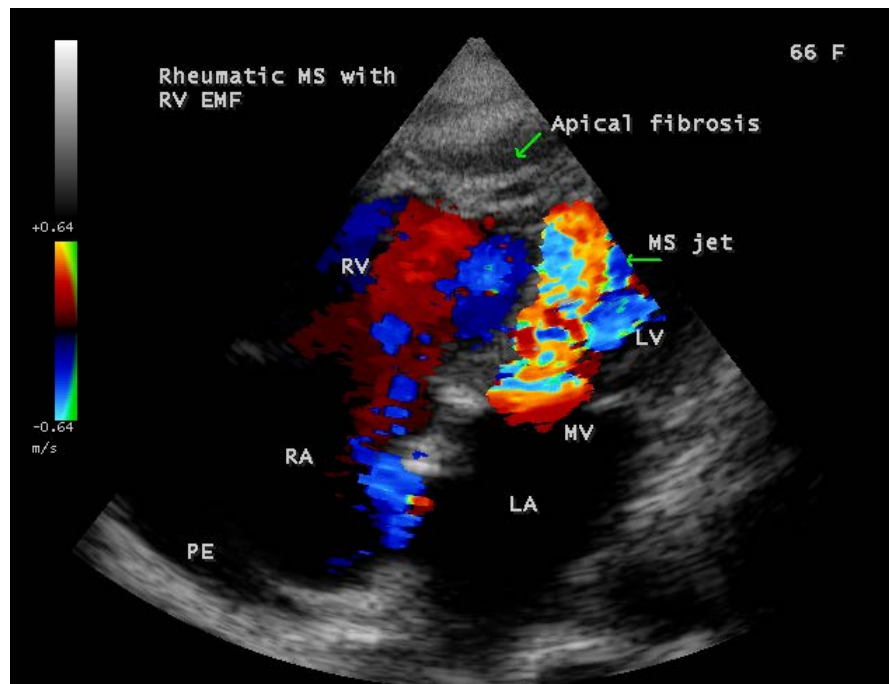


Figure 25. Showing RV apical fibrosis (upper arrow) with rheumatic mitral stenosis (lower arrow).

fever in endemic areas can be challenging [26]. The active phase with recurrent flare-up of inflammation due to repeated insults GAS (Group A β hemolytic streptococci) exposure to RHD (rheumatic heart disease), unclear for EMF

Table 1. Types of distribution of fibrosis in endomyocardial fibrosis [19] [20].

Type 1	fibrosis at the apex only
Type 2	fibrosis at apex extends to valvular area
Type 3	fibrosis at valvular region only
Type 4	isolated lesions of fibrosis at apex and valvular region
Type 5	patchy areas of fibrosis other than the apex and valve

evolving to a chronic phase of cardiac manifestations.

Endocardial thickening is the hallmark of EMF, which corresponds microscopically to an increased number and abnormal stimulation of cardiac fibroblasts in the subendocardium leading to increased collagen synthesis. Inflammatory cell infiltrates composed mainly of lymphocytes are prevalent along the interface between the endocardium and myocardium. Myocardial lesions such as interstitial fibrosis and scar formation are prominent in areas adjacent to subendocardial fibrosis and altered blood vessels, suggesting that they likely occur in response to ischemic injury caused by microvascular changes and there is a lack of vessels in the outer endocardium, in contrast to rheumatic heart disease.

Endomyocardial fibrosis is a multisystem disorder and it also affects the reproductive system, manifested as loss of secondary sexual characters, testicular atrophy, fibrosis of fimbrial ends of fallopian tube, leading to dysfunctional uterine bleeding and infertility as in Case 11, associated with IAS (interatrial septum) calcification. Poor genital hygiene and genital infections play an important role in the causation of EMF in endemic areas. EMF also involve the renalsystem and causes renal failure, occasionally presents with seizures as the initial manifestation with endocardial lesions in cardiac chambers.

3.3. Echocardiographic Features

Echocardiography has become the mainstay of diagnosis of EMF [27]. It has been used as the screening tool at the community level as the diagnosis of EMF can be confirmed at bedside.

In acute cases of EMF, the endocardial lesions are covered with a soft, spongy, greyish-green layer of thrombus as shown in **Figure 23**. Large endocardial plaques are unique echocardiographic feature of EMF as in **Figure 12**, **Figure 14**, **Figure 15**, **Figure 19** and **Figure 22**. EMF is marked by focal or diffuse areas of endocardial calcification, characterized by a white, smooth, and shiny endocardial surface as shown in **Figure 9** and **Figure 16** in interventricular septum (IVS), atrial septum as in **Figure 20** and “egg-shell” calcification of myocardium as in **Figure 3** and **Figure 18**. The restricted movement of fibrotic ventricular apex and its obliteration are accompanied by compensatory contractile mechanism that results in exaggerated and distinctive motion of the basal portion of the ventricle, the so called “Merlon sign” [28] [29].

In early stages of EMF, spontaneous contrast and abnormalities of ventricular regional wall motion [30] [31]. [32] may be observed as in **Figure 4** and **Figure**

10. The presence of a linear calcification, distal to the pericardium along the inner border of myocardium as in **Figure 21**, enhanced density of moderator or other intraventricular bands suggests EMF and the occurrence of endomyocardial calcification spots as in **Figure 7** is usually a marker of “burnt-out” disease [33]. The fibrotic lesions may be >1 cm thick and extend finger-like projections into the myocardium [34] as shown in **Figure 17**.

3.4. Management

3.4.1. Medical Therapy

It has no specific treatment for EMF and carries poor prognosis since most patients present with advanced heart failure. Medical management consists of symptomatic treatment of heart failure with diuretics, angiotensin-converting enzyme inhibitors offered in combination with aspirin or anticoagulants in view of occurrence of coronary artery disease. The response to medical therapy is generally poor and unproven. When combined with rheumatic fever as evidenced by ASO (anti-streptolysin O) positivity, penicillin prophylaxis is a powerful modifier of the disease and causes regression when initiated early [35] in majority of cases.

3.4.2. Investigational Therapy

The fibrosis is a scarring process that over time impacts cardiac structure and function in Endomyocardial fibrosis. Therapies directed at cardiac fibrosis could reduce the progression of the disease. Medications that target the renin-angiotensin system (RAS), transforming growth factor- β and endothelin (ET) are in various stages of development [36]. Biomarkers such as propeptides and telopeptides, released during synthesis and degradation of collagen type 1 and III of extracellular matrix (ECM) [37], the structural component of myocardium, are used to identify fibrosis and to assess the efficacy of medications [38].

3.4.3. RAS Inhibitors

The renin-angiotensin (RAS) system plays a central role in fibroblast activation and it is an important target for drug therapy. It is a complex system with two counterbalancing axes. In addition to familiar ACE/Ang II/AT₁ axis, an ACE₂/Ang-(1-7)/Mas receptor axis has been identified, which has antifibrogenic and antiproliferative effects in heart. Administration of Ang-(1-7) and overexpression of ACE₂ can reduce cardiac fibrosis in animal models [39]. The routine use of RAS inhibiting medications, the ACE inhibitors, angiotensin II receptor blockers (ARBs) and aldosterone antagonists in hypertensive patients have shown to reduce fibrosis in humans.

Vaccines with angiotensin II effects (RAS vaccine) effectively decreased cardiac fibrosis in immunized mice, Ang II signaling was inhibited, and anti-Ang II antibodies increased.

3.4.4. TGF- β Inhibitors

Pirfenidone and tranilast have profound effects in reducing fibrosis, but the liver

and renal dysfunction associated with these agents could impact its use in clinical practice [40].

3.4.5. ET Inhibitors

Bosentan has been demonstrated to inhibit ECM formation, decreased collagen synthesis and increase collagenase suppression [41] in animal models.

3.4.6. HDAC (Histone Deacetylase) Inhibitors

These agents have positive results in reducing cardiac fibrosis as well as Ang II receptor and TGF- β levels in animal models and promising future therapeutic targets [42].

3.4.7. Ivabradine

It is an oral medication that provides selective heart rate reduction by inhibiting the f-channels of the sinoatrial node [43]. It effectively reduces the fibrosis, circulating Ang II and aldosterone levels in animal models.

3.4.8. Imatinib

Inhibition of the protein, FIPILI-PDGFR α_p , a constitutively activated tyrosine kinase by imatinib is a potential therapeutic target for patients with early EMF [44].

3.4.9. Novel Treatment Strategies

1) Stem cell therapy

Transplantation of a variety of stem cells following myocardial infarction has been demonstrated to decrease cardiac fibrosis and cardiac muscle apoptosis [45]. The rationale of therapy is to improve blood supply to the ischemic areas of heart and to promote cardiac cell regeneration by a direct or paracrine factors by stem cells [46] [47].

The stem cells studied in cardiovascular research ranged from bone marrow to adipose tissue to skeletal muscle stem cells. These cells could potentially face rejection and it is possible to reprogram adult cells and transform these into pluripotent cells (similar properties as embryonic stem cells), termed as “induced pluripotent stem cells”, which can be auto-transplanted and therefore would not be rejected.

The bone marrow-derived monoclonal, mesenchymal stem cells are most readily available for transplantation in the body. Following injection of mononuclear stem cells in patients with myocardial infarction, there is improvement in LV ejection fraction within months [48], improve exercise capacity, decrease in scar tissue and a reduction in mortality in a 5-year follow up [49] occurs.

The heart possesses cardiac stem cells that could be responsible for the intrinsic regeneration and turnover throughout adult life [50] and these cells are numerous in apices of the atrium and ventricles [51], but their reparative potential is limited in extensive damage such as myocardial infarction [52] [53]. Cardiac stem cells could be beneficial in chronic ischemic patients [54] and more recent-

ly, there has been an interest to develop and inject multiple stem cells that can communicate with each other termed as “cardiocluster”. These clusters are cocktails of cells that include cardiac progenitor cells, mesenchymal stem cells, endothelial progenitor cells and fibroblasts. They have the potential to promote cardiac cell regeneration in disease states such as CAD (coronary artery disease) when cell function is reduced [55]. Thus, stem cell therapy continues to be a promising treatment modality in both acute and chronic CAD.

2) Nanomedicine

Nanotechnology has led to an interesting and promising direction in the treatment of coronary artery disease. HDL (high density lipoprotein) are thought to have a protective role since they are involved in the transportation of cholesterol away from the peripheral tissues. Nanotechnology has been used in the synthesis of a dimyristoyl phosphatidyl choline, which mimics the surface characteristics of HDL by mediating the removal of cholesterol from the peripheral tissue and transport it to the liver and this agent showed significant reduction in plaque volume and cholesterol content in aorta in animal models [56].

Fumagillin is an antiangiogenic drug that has been shown to promote plaque regression in coronary vasculature, but causes neurocognitive effects at therapeutic effect in high doses.

Several nanoparticle-based antithrombotic agents such as D-phenylalanyl-L-prolyl-Larginyl-Chloromethyl ketone, perfluorocarbon-core nanoparticle, collagen IV nanoparticles, which improve collagen formation while reducing oxidative stress by mimicking Annexin A₁, a glucocorticoid regulatory protein in animal models [57].

Molecular mimicry with genetic predisposition may result in autoimmune damage to endothelial lining of the heart and blood vessels, and treatment with nanobacteria is promising with reversal of calcific deposits within the vasculature.

3) During PCI (percutaneous coronary interventions)

Nanotechnology has shown potential benefits when used in PCI. It has the potential to promote healing by inducing endothelialization of the stent and to reduce restenosis [58]. Endothelial healing and re-endothelialization help to restore the injured vessel. Nano-sized hydroxyapatite coating, carbon nanoparticle coated stents with consistent release of sirolimus, pitavastatin nanoparticle-eluting stents [59], Magnetic silica nanoparticles with rapamycin exhibit endothelialization in vitro-studies. It has been proven that liposome encapsulated alendronate (a biphosphonate) [60], an antimetabolic drug (paclitaxel) in the form of albumin-based nanoparticles with significant antiproliferative effects can reduce restenosis and neointimal hyperplasia in animal models, even when administered systemically [61] and to reduce platelet adhesion [62]. Gene eluting stents can be used to overcome restenosis, in-stent thrombosis and delayed endothelialization [63].

Synthetic alternatives such as electrospun nanosized fibrous scaffolds for coronary artery bypass grafts have been studied in graft procedures [64] [65].

4) Novel oral anticoagulants

This group consists of ximelagatran, dabigatran, rivaroxaban, darexaban and apixaban [66]. Dabigatran is a competitive inhibitor of thrombin and the other agents, edoxaban, rivaroxaban and apixaban are inhibitors of clotting factor Xa. Dabigatran reduces the ischemic events at higher doses (110 and 150 mg), which has a bleeding risk and low dose therapy could be used without significant increase in bleeding risk [67].

5) Alirocumab

It is a monoclonal antibody produced by recombinant DNA technology, known to block the LDL regulator protein (PCSK9-Proprotein Convertase Subtilisin/Kexin Type 9), and reduce the LDL cholesterol to 66-73% when combined with atorvastatin, whereas atorvastatin alone cause reduction by 17% only [68].

6) ARNi (Angiotensin receptor-neprilysin inhibitor)

It is a combination of Sacubitril (neprilysin inhibitor component) and valsartan (Angiotensin II receptor antagonist), commonly referred to as LCZ696 or ARNi [69] [70] and it is more effective in the treatment of heart failure than the traditional ACE (angiotensin converting enzyme) inhibitors [71] [72].

7) Role of antibiotics

Plaque formation in both blood vessels (atherosclerotic/infective) and endocardium (infective) is a process of complexity and infection plays an important role in its pathogenesis. Antibiotic treatment should slow its progress in and early eradication of the organism is important to prevent future cardiovascular events. The *Chlamydia Pneumoniae*, the most studied intracellular pathogen in vascular infections and antibiotics may eliminate the organism from epithelial cells, but difficult to clear it from the circulating monocytes. It is sensitive to macrolides, the azithromycin (approved for sexually transmitted *Chlamydia Trachomatis* infection), roxithromycin, tetracyclines and fluoroquinolones (gatifloxacin) [73]. Azithromycin is readily taken up into atherosclerotic plaques [74], given once weekly in clinical trials since a single dose may require 10 days for elimination and generally well tolerated during long-term prophylaxis, but gastrointestinal symptoms and superinfection by candidiasis may also occur. In ACADEMIC trial [75], there was a reduction in markers of inflammation such as C-reactive protein, TNF- α , IL-1, 6, but antibody titers were unchanged after 6 months of therapy with azithromycin. In ISAR-3 (Intracoronary Stenting And Antibiotic Regimen-3) investigated roxithromycin, an effective anti-chlamydial macrolide for the prevention of restenosis after coronary stent deployment [76] and showed that it was ineffective at lower titers and favoured for patients with high titers (>1:512). These results raise the intriguing possibility that antibiotics might be selectively beneficial in a subgroup of patients with active infection, a more vigorous immune response or both.

Treatment for bacteremia of unknown origin is problematic. Metronidazole is

known to be effective for the treatment of anaerobic organisms and parasites. Additional metronidazole had improved outcome in STAMINA trial [77] when azithromycin is ineffective for Chlamydia Pneumoniae and complete eradication may take 1-year of treatment [78] (long-term therapy) since the organism is resistant to antibiotics when engulfed within the monocytes [79].

Leptospirosis (Weil's disease, first described by Adolf Weil in Heidelberg, Germany in 1886) is a zoonosis, caused by gram negative aerobic spirochete of the genus, leptospira interrogans and it is potentially pathogenic to humans (Leptospira biflexa is not), causing myocarditis and arrhythmic episodes [80], 4 to 30 days after the initial phase (fever with rigors, jaundice, conjunctival suffusion, pharyngitis, muscle tenderness and rigidity). It is immunologically mediated and responds to antibiotics, the ceftriaxone, penicillin, ampicillin, azithromycin and doxycycline 200 mg/week is recommended in high risk areas.

Previous use of sulfonamides, macrolides, penicillin, cephalosporin had no effect on myocardial infarction (MI) risk and vancomycin may cause coronary artery spasm (Kounis syndrome) [81].

Initiation of antibiotics with cefotaxime or amoxicillin provide better outcome in EMF patients in endemic areas. Once allergic stimulus was removed with small doses of chlorpheniramine maleate (avil) and dexamethasone (4mg), the ECG changes may become normalize at early stages of involvement and arrhythmic episodes reverse spontaneously or by specific treatment with adenosine, verapamil, amiodarone and cardioversion in resistant cases.

8) Pinocebrin

Pinocebrin is a major flavonoid derived from propolin, plays a role in the treatment of myocardial ischemia and reperfusion injury through its antioxidant effect, reduction of calcium overload, as well as inhibition of inflammation and myocardial cell apoptosis in animal models [82]. Pinocebrin exerts its antiarrhythmic effect by increasing the activity of Ca^{2+} - Mg^{2+} -ATPase, thereby maintaining cardiac channels and upregulating the expression of cardiomyocyte ligament junction proteins [83], the Cx43 (a gap junction protein, the main connexin of cardiomyocytes), ZO-1 (Claudin-1), Kir 2.1 and suppression of the redistribution of ZO-1 and Cx43, regulated by GJA_1 and KCNJ_2 genes to maintain the synchronization of electrical activity of the body and the development of heart [84].

9) Levosimendan

The clinically used inotropes worsen the reperfusion stunning and provoke arrhythmias by increasing the cytosolic calcium level. Levosimendan is a calcium sensitizer, which increases the myofilament calcium sensitivity without increasing myosin-ATPase activity. It is also a PDE (phosphodiesterase inhibitor) and K_{ATP} channel opener, do not increase the cytosolic calcium when given in low concentrations. It protects the ischemic myocardium while at same time improving reperfusion mechanical function without elevating cytosolic calcium level and thus, it is a cardioprotective inotrope by virtue of its ATPase sparing and K_{ATP} channel opening properties. It also induces changes in cAMP to cGMP

ratio, an increase in cGMP level decrease the increase in cytosolic calcium during ischemia and protects from arrhythmic episodes [85].

10) Antioxidants

Direct induction of lipid peroxidation has arrhythmogenic effect on the heart. The stress affect the Na^+ , K^+ -ATPase activity and accelerates thermodenaturation of this enzyme which plays a key role in maintaining the transmembrane potential and electrical stability of the heart. Antioxidants prevent cardiac fibrillation during acute ischemia and reoxygenation of the heart [86].

11) Surgical therapy

Patients with end-stage EMF may not be suitable for surgery. Surgical management is mainly for relief of complications which are responsible for poor prognosis to medical therapy. Pericardio-peritoneal shunt for massive and recurrent pericardial effusion and in fewer cases, a right atrial to pulmonary arterial shunting and pericardial stripping may improve the outcome. In most cases, a clearly delineated cleavage plane allows for the removal of stiff, fibrotic endocardium (endocardectomy) and improves the ventricular function, however, variable rates of recurrence after surgery have been reported [87].

3.5. Outcome

EMF still causes significant morbidity in specific geographical pockets. Untreated EMF carries very poor prognosis and it represents the second leading cause of pediatric admissions for acquired heart disease after rheumatic heart disease [88]. The long-term outcome in medical treatment for advanced cases carries 75% mortality at 2 years [89]. An unknown number of cases evolve rapidly to heart failure and experienced sudden death caused by ventricular arrhythmias [90].

3.6. Preventive Measures

EMF affects both indigenous and non-indigenous inhabitants, suggests that it is an environmental disease, caused by an infective agent, transmitted to the susceptible individual by a vector which is confined to the tropical and subtropical belts, especially in the hot, humid coastal areas and rain-forest regions. The disease affects the children and young adults in an epidemic fashion in tropical countries and it has remained poorly understood, not appearing in public health agenda of the countries [91].

Investment in research is extremely limited. Improvement in environmental sanitation and hygienic measures may bring this neglected disease under control. Establishment of research stations and health care centers under the direct vision of WHO (World Health Organization) is mandatory in these tropical nations.

3.7. Case Analysis

The sociodemographic and clinical characteristics of patients are shown in **Table 2**.

Table 2. Sociodemographic and clinical features.

	Social factors				Clinical features
	Age (years)	Sex	Rural/urban	Economic status	
Case 1	65	female	rural	poor	Chest discomfort, palpitations
Case 2	45	male	urban	high	Chest discomfort
Case 3	42	male	rural	poor	Sudden onset of chest discomfort
Case 4	4	female	rural	poor	Bradycardia
Case 5	15	female	urban	poor	Anginal episodes
Case 6	78	female	rural	poor	ST-T changes
Case 7	60	male	rural	poor	Acute myocardial infarction
Case 8	52	male	rural	poor	Anginal episodes
Case 9	60	female	rural	poor	Sudden onset of tachycardia
Case 10	60	male	rural	poor	Bradycardia
Case 11	28	female	urban	middle class	Infertility
Case 12	25	male	rural	poor	Anginal episodes, Elevated CKMB Normal ECG
Case 13	Neonate	female	rural	poor	Atrial fibrillation with fast response
Case 14	55	male	urban	middle class	Recent anterior wall infarction
Case 15	66	female	rural		RV EMF with Rheumatic mitral valve disease

The reported cases clearly showing an association between endomyocardial fibrosis and coronary artery disease with arrhythmogenic potentials. Septal calcification of interatrial septum (IAS) and interventricular septum (IVS) is a special feature, more prone to ischemic episodes even before the ECG changes occur. Sudden onset of arrhythmias in children, young adults and older age group herald the lesions of EMF in echocardiography and similarly with infarction episodes.

The patients were advised for sedentary lifestyle recruitment and under periodic check up in cardiology clinic.

4. Conclusion

Endomyocardial fibrosis (EMF) is characterized by extensive fibrosis with calcification and architectural distortion [92] of the heart. It is the disease of rural belts with a high prevalence in south India and appears to have regional variations in endemic countries [93] [94]. The changing pattern of coronary artery disease with characteristic epidemiological features [95] in endemic areas provide the way to create alternate guidelines in the management of acute coronary syndrome and arrhythmogenic episodes in future.

References

- [1] Aggarwal, A., Srivastava, S. and Velmurugan, M. (2016) Newer Perspectives of Co-

- ronary Artery Disease in Young. *World Journal of Cardiology*, **8**, 728-774. <https://doi.org/10.4330/wjc.v8.i12.728>
- [2] Ford, E.S., Ajani, U.A., Croft, J.B., Critchley, J.A., Labarthe, D.R., Kottke, T.E., Giles, W.H. and Capewell, S. (2007) Explaining the Decrease in U.S. Deaths from Coronary Disease, 1980-2000. *New England Journal of Medicine*, **356**, 2388-2398. <https://doi.org/10.1056/NEJMsa053935>
- [3] Shekella, R.B., Shyrock, A.M., Paul, O., *et al.* (1981) Diet, Serum Cholesterol and Death from Coronary Artery Disease. The Western Electric Study. *New England Journal of Medicine*, **304**, 75-80.
- [4] Shaper, A.G. (1996) Reflections on the Seven Countries Study. *Lancet*, **347**, 208. [https://doi.org/10.1016/S0140-6736\(96\)90396-7](https://doi.org/10.1016/S0140-6736(96)90396-7)
- [5] Assimes, T.L. and Herrington, D.M. (2018) Genetic Risk Scores in Premature Coronary Artery Disease. *Circulation: Genomic and Precision Medicine*, **11**, e002006.
- [6] Dileep Kumar, P. (1997) The Role of Coconut and Coconut Oil in Coronary Heart Disease in Kerala, South India. *Tropical Doctor*, **27**, 215-217. <https://doi.org/10.1177/004947559702700409>
- [7] Charters, A.D. and Arya, B.P. (1960) Incidence of Ischemic Heart Disease among Indians in Kenya. *Lancet*, **1**, 288-289. [https://doi.org/10.1016/S0140-6736\(60\)90222-1](https://doi.org/10.1016/S0140-6736(60)90222-1)
- [8] Charters, A.D. (1961) Aetiology of Coronary Heart Disease in Kenya. *The Indian Practitioner*, **15**, 663-667.
- [9] Sohal, R.S., Burch, G.E., Chu, K.C., Leiderman, E. and Colcolough, H.L. (1968) Ultrastructural Changes in Cardiac Capillaries of Coxsackie B₄ Infected Mice. *Laboratory Investigation*, **19**, 399-405.
- [10] Burch, G.E. and Shewey, L.L. (1976) Viral Coronary Arteritis and Myocardial Infarction. *American Heart Journal*, **92**, 11-14. [https://doi.org/10.1016/S0002-8703\(76\)80398-5](https://doi.org/10.1016/S0002-8703(76)80398-5)
- [11] Reines, H.D., Halushka, P.V., Cook, J.A., Wise, W.C. and Rambo, W. (1982) Plasma Thromboxane Concentrations Are Raised in Patients Dying with Septic Shock. *Lancet*, **2**, 174-175. [https://doi.org/10.1016/S0140-6736\(82\)91027-3](https://doi.org/10.1016/S0140-6736(82)91027-3)
- [12] Nieminen, M.S., Mattila, K. and Valtonen, V. (1993) Infection and Inflammation as Risk Factors for Myocardial Infarction. *European Heart Journal*, **14**, 12-16.
- [13] Alvarez, C. and Ramos, A. (1986) Lipids, Lipoproteins, and Apoproteins in Serum during Infection. *Clinical Chemistry*, **32**, 142-145.
- [14] Lopes-Virella, M.F. (1994) Interactions between Bacterial Lipopolysaccharides and Serum Lipoproteins and Their Possible Role in Coronary Heart Disease. *European Heart Journal*, **14**, 118-124.
- [15] Benditt, E.P. and Benditt, J.M. (1973) Evidence for a Monoclonal Origin of Human Atherosclerotic Plaques. *Proceedings of the National Academy of Sciences, USA*, **70**, 1753-1756. <https://doi.org/10.1073/pnas.70.6.1753>
- [16] Spodick, D.H., Flessas, A.P. and Johnson, M.M. (1984) Association of Acute Respiratory Symptoms with Onset of Acute Myocardial Infarction: Prospective Investigation of 150 Consecutive Patients and Matched Control Patients. *American Journal of Cardiology*, **53**, 481-482. [https://doi.org/10.1016/0002-9149\(84\)90016-X](https://doi.org/10.1016/0002-9149(84)90016-X)
- [17] Mendall, M.A., Patel, P., Ballam, L., Strachan, D. and Northfield, T.C. (1996) C-Reactive Protein and Its Relation to Cardiovascular Risk Factors: A Population Based Cross Sectional Study. *BMJ (British Medical Journal)*, **312**, 1061-1065. <https://doi.org/10.1136/bmj.312.7038.1061>

- [18] Liuzzo, G., Biasucci, L.M., Gallimore, J.R., *et al.* (1994) The Prognostic Value of C-Reactive Protein and Serum Amyloid A Protein in Severe Unstable Angina. *New England Journal of Medicine*, **331**, 417-424. <https://doi.org/10.1056/NEJM199408183310701>
- [19] Shaper, A.G. Hutt, M.S. and Coles, R.M. (1968) Necropsy Study of Endomyocardial Fibrosis and Rheumatic Heart Disease in Uganda, 1950-1965. *British Heart Journal*, **30**, 391-401. <https://doi.org/10.1136/hrt.30.3.391>
- [20] Hutt, M.S.R. (1970) Pathology of African Cardiomyopathies. *Pathologia et Microbiologia*, **35**, 37. <https://doi.org/10.1159/000162197>
- [21] Olsen, E.G.J. and Sekiguchi, M. (1990) Cardiomyopathy Update No. 3: Restrictive Cardiomyopathy and Arrhythmias. University of Tokyo Press, Tokyo, 1-7.
- [22] Nwokolo, C. (1962) The Evolution of Endomyocardial Fibrosis. *West African Medical Journal*, **11**, 51-57.
- [23] Mocumbi, A.O. and Falase, A.O. (2013) Recent Advances in the Epidemiology, Diagnosis and Treatment of Endomyocardial Fibrosis in Africa. *Heart*, **99**, 1481-1487. <https://doi.org/10.1136/heartjnl-2012-303193>
- [24] Davies, J., Spry, C.J., Vijayaraghavan, G. and De Souza, J.A. (1983) A Comparison of the Clinical and Cardiological Features of Endomyocardial Disease in Temperate and Tropical Regions. *Postgraduate Medical Journal*, **59**, 179-185. <https://doi.org/10.1136/pgmj.59.689.179>
- [25] Tharakan, J.A. (2011) Electrocardiogram in Endomyocardial Fibrosis. *Indian Pacing and Electrophysiology Journal*, **11**, 129-133.
- [26] Kennedy, N., Miller, P., Adamczick, C. and Molyneux, E. (2012) Endomyocardial Fibrosis: The First Report from Malawi. *Pediatrics and International Child Health*, **32**, 86-88. <https://doi.org/10.1179/1465328111Y.0000000036>
- [27] Mocumbi, A.O., Corrilho, C., Sarathchandra, P., Ferreira, M.B., Yacoub, M. and Burke, M. (2011) Echocardiography Accurately Assesses the Pathological Abnormalities of Chronic Endomyocardial Fibrosis. *International Journal of Cardiovascular Imaging*, **27**, 955-964. <https://doi.org/10.1007/s10554-010-9753-6>
- [28] Berensztein, C.S., Pinero, G., Marcotegui, M., *et al.* (2000) Usefulness of Echocardiography and Doppler Echocardiography in Endomyocardial Fibrosis. *Journal of American Society of Echocardiography*, **13**, 226-230. [https://doi.org/10.1016/S0894-7317\(00\)70008-3](https://doi.org/10.1016/S0894-7317(00)70008-3)
- [29] Vijayaraghavan, G., Davies, J., Sadanandan, S., *et al.* (1983) Echocardiographic Features of Tropical Endomyocardial Disease in South India. *British Heart Journal*, **50**, 450-459. <https://doi.org/10.1136/hrt.50.5.450>
- [30] Mocumbi, A.O. (2012) Endomyocardial Fibrosis: A Form of Endemic Restrictive Cardiomyopathy. *Global Cardiology Science & Practice*, **1**, 11. <https://doi.org/10.5339/gcsp.2012.11>
- [31] Okereke, Q.U.J., Chikwendu, V.C., Ihenacho, H.N.C., *et al.* (1991) Non-Invasive Diagnosis of Endomyocardial Fibrosis in Nigeria Using Two-Dimensional Echocardiography. *Tropical Cardiology*, **17**, 97-105.
- [32] Mady, C., Salemi, V.M.C., Ianni, B.M., *et al.* (2005) Quantitative Assessment of Left Ventricular Regional Wall Motion in Endomyocardial Fibrosis. *Arquivos Brasileiros De Cardiologia*, **84**, 241-244.
- [33] Vijayaraghavan, G. and Sivasankaran, S. (2012) Tropical Endomyocardial Fibrosis in India: A Vanishing Disease! *Indian Journal of Medical Research*, **136**, 729-738.
- [34] NORD (National Organization for Rare Disorders) (2017) Endomyocardial Fibro-

sis.

- [35] Steer, A.C. and Carapetes, J.R. (2009) Prevention and Treatment of Rheumatic Heart Disease in the Developing World. *Nature Reviews Cardiology*, **6**, 689-698. <https://doi.org/10.1038/nrcardio.2009.162>
- [36] Leask, A. (2010) Potential Therapeutic Targets for Cardiac Fibrosis: TGF Beta, Angiotensin, Endothelin, CCN, and PDGF, Partners in Fibroblast Activation. *Circulation Research*, **106**, 1675-1680. <https://doi.org/10.1161/CIRCRESAHA.110.217737>
- [37] Fan, D., Takawale, A., Lee, J. and Kassiri, Z. (2012) Cardiac Fibroblasts, Fibrosis and Extracellular Matrix Remodeling in Heart Disease. *Fibrogenesis Tissue Repair*, **5**, 15. <https://doi.org/10.1186/1755-1536-5-15>
- [38] Roubille, F., Busseuil, D., Merlet, N., *et al.* (2014) Investigational Drugs Targeting Cardiac Fibrosis. *Expert Review of Cardiovascular Therapy*, **12**, 111-125. <https://doi.org/10.1586/14779072.2013.839942>
- [39] Simoes e Silva, A.C., Silveira, K.D., Ferreira, A.J. and Teixeira, M.M. (2013) ACE, Angiotensin-(1-7) and Mas Receptor Axis in Inflammation and Fibrosis. *British Journal of Pharmacology*, **169**, 477-492. <https://doi.org/10.1111/bph.12159>
- [40] Edgley, A.J., Krum, H. and Kelly, D.J. (2012) Targeting Fibrosis for the Treatment of Heart Failure: A Role for Transforming Growth Factor-Beta. *Cardiovascular Therapy*, **30**, e30-e40. <https://doi.org/10.1111/j.1755-5922.2010.00228.x>
- [41] Clozel, M. and Salloukh, H. (2005) Role of Endothelin in Fibrosis and Anti-Fibrotic Potential of Bosentan. *Annals of Medicine*, **37**, 2-12. <https://doi.org/10.1080/07853890410018925>
- [42] Tao, H., Shi, K.H., Yang, J.J., *et al.* (2014) Histone Deacetylases in Cardiac Fibrosis: Current Perspectives for Therapy. *Cell Signaling*, **26**, 521-527. <https://doi.org/10.1016/j.cellsig.2013.11.037>
- [43] Amgen (2014) Ivabradine for the Treatment of Chronic Heart Failure, October, 22.
- [44] Cools, J., DeAngelo, D.J., Gotlib, J., Stover, E.H., Legare, R.D., Cortes, J., Kutok, J., Clark, J., Galinsky, I., Griffin, J.D., Cross, N.C., *et al.* (2003) A Tyrosine Kinase Created by Fusion of the PDGFRA and FIPILI Genes as a Therapeutic Target of Imatinib in Idiopathic Hypereosinophilic Syndrome, *New England Journal of Medicine*, **348**, 1201-1214. <https://doi.org/10.1056/NEJMoa025217>
- [45] Elnakish, M.T., Kuppusamy, P. and Khan, M. (2013) Stem Cell Transplantation as a Therapy for Cardiac Fibrosis. *Journal of Pathology*, **229**, 347-354. <https://doi.org/10.1002/path.4111>
- [46] Kastrup, J. (2010) Gene Therapy and Angiogenesis in Patients with Coronary Artery Disease. *Expert Review of Cardiovascular Therapy*, **8**, 1127-1138. <https://doi.org/10.1586/erc.10.95>
- [47] Kastrup, J. (2011) Stem Cells Therapy for Cardiovascular Repair in Ischemic Heart Disease. How to Predict and Secure Optimal Outcome? *EPMA (European Association for Predictive Preventive & Personalized Medicine) Journal*, **2**, 107-117.
- [48] Stamm, C., Westphal, B., Kleine, H., Petzsch, M., Kittner, C., Klinge, H., Schumichen, C., Nienaber, C., Freund, M. and Steinhoff, P.G. (2003) Autologous Bone-Marrow Stem-Cell Transplantation for Myocardial Regeneration. *Lancet*, **361**, 45-46. [https://doi.org/10.1016/S0140-6736\(03\)12110-1](https://doi.org/10.1016/S0140-6736(03)12110-1)
- [49] Yousef, M., Schannwell, C.M., Kosterling, M., Zeus, T., Brehm, M. and Strauer, B.E. (2009) The BALANCE Study: Clinical Benefit and Long-Term Outcome after Intracoronary Autologous Bone Marrow Cell Transplantation in Patients with Acute Myocardial Infarction. *Journal of American College of Cardiology*, **53**,

- 2262-2269. <https://doi.org/10.1016/j.jacc.2009.02.051>
- [50] Beltrami, A.P., Barlucchi, L., Torella, D., Baker, M., Limana, F., Chimenti, S., Kasahara, H., Rota, M., Musso, E., Urbanek, K., *et al.* (2003) Adult Cardiac Stem Cells Are Multipotent and Support Myocardial Regeneration. *Cell*, **114**, 763-776. [https://doi.org/10.1016/S0092-8674\(03\)00687-1](https://doi.org/10.1016/S0092-8674(03)00687-1)
- [51] Leri, A. (2009) Human Cardiac Stem Cells: The Heart of a Truth. *Circulation*, **120**, 2515-2518. <https://doi.org/10.1161/CIRCULATIONAHA.109.911107>
- [52] Chan, S.S.K., Shueh, Y.Z., Liu, Y.W. and Hsieh, P.C.H. (2009) Harnessing Endogenous Intra-And Extra-Cardiac Stem Cells for Cardiac Regeneration-Hope or Hipe? *Drug Discovery Today. Therapeutic Strategies*, **6**, 127-133. <https://doi.org/10.1016/j.ddstr.2009.06.004>
- [53] Ferreira-Martins, J., Ogorek, B., Cappetta, D., Matsuda, A., Signore, S., *et al.* (2012) Cardiomyogenesis in the Developing Heart Is Regulated by c-kit-Positive Cardiac Stem Cells. *Circulation Research*, **110**, 701-715. <https://doi.org/10.1161/CIRCRESAHA.111.259507>
- [54] Malliaras, K., Makkar, R.R., Smith, R.R., Cheng, K., Wu, E., Bonow, R.O., *et al.* (2014) Intracoronary Cardiosphere-Derived Cells after Myocardial Infarction: Evidence of Therapeutic Regeneration in the Final 1-Year Results of the CADUCEUS Trial (Cardiosphere-Derived Autologous Stem CELLS to Reverse Ventricular Dysfunction). *Journal of American College of Cardiology*, **63**, 110-122. <https://doi.org/10.1016/j.jacc.2013.08.724>
- [55] Nguyen, N. and Sussman, M.A. (2015) Rejuvenating the Senescent Heart. *Current Opinion in Cardiology*, **30**, 235-239. <https://doi.org/10.1097/HCO.0000000000000161>
- [56] Cho, B.H., Park, J.R., Nakamura, M.T., Odinstov, B.M., Wallig, M.A. and Chung, B.H. (2010) Synthetic Dimyristoylphosphatidyl Choline Liposomes Assimilating into High-Density Lipoprotein Promote Regression of Atherosclerotic Lesions in Cholesterol-Fed Rabbits. *Experimental Biology and Medicine*, **235**, 1194-1203. <https://doi.org/10.1258/ebm.2010.009320>
- [57] Fredman, G., Kamaly, N., Spolitu, S., Milton, J., Ghorpade, D., *et al.* (2015) Targeted Nanoparticles Containing the Proresolving Peptide Ac2-26 Protect against Advanced Atherosclerosis in Hypercholesterolemic Mice. *Science Translational Medicine*, **7**, 275ra20. <https://doi.org/10.1126/scitranslmed.aaa1065>
- [58] Rhee, J.W. and Wu, J.C. (2013) Advances in Nanotechnology for the Management of Coronary Artery Disease. *Trends in Cardiovascular Medicine*, **23**, 39-45. <https://doi.org/10.1016/j.tcm.2012.08.009>
- [59] Tsukie, N., Nakano, K., Matoba, T., Masuda, S., Iwata, E., Miyagawa, M., Zhao, G., Meng, W., Kishimoto, J., Sunagawa, K., *et al.* (2013) Pitavastatin-Incorporated Nanoparticle-Eluting Stents Attenuate In-Stent Stenosis Without Delayed Endothelial Healing Effects in a Porcine Coronary Artery Model. *Journal of Atherosclerosis And Thrombosis*, **20**, 32-45. <https://doi.org/10.5551/jat.13862>
- [60] Danenberg, H.D., Golomb, G., Groothuis, A., Gao, J., Epstein, H., Swaminathan, R., V., Seifert, P. and Edelman, E.R. (2003) Liposomal Alendronate Inhibits Systemic Innate Immunity and Reduces In-Stent Neointimal Hyperplasia in Rabbits. *Circulation*, **108**, 2798-2804. <https://doi.org/10.1161/01.CIR.0000097002.69209.CD>
- [61] Margolis, J., McDonald, J., Heuser, R., Klinke, P., Waksman, R., Virmani, R., Desai, N. and Hilton, D. (2007) Systemic Nanoparticle Paclitaxel (Nab-Paclitaxel) for In-Stent Restenosis 1 (SYNAPIST-1): A First-in-Human Safety and Dose-Finding Study. *Clinical Cardiology*, **30**, 165-170. <https://doi.org/10.1002/clc.20066>

- [62] Joo, J.R., Nam, H.Y., Nam, S.H., Baek, I. and Park, J.S. (2009) Thermal Process for Enhancing Mechanical Strength of PLGA Nanoparticle Layers On Coronary Stents, *Bulletin of the Korean Chemical Society*, **30**, 1985-1988. <https://doi.org/10.5012/bkcs.2009.30.9.1985>
- [63] Yin, R.X., Yang, D.Z. and Wu, J.Z. (2014) Nanoparticle Drug- and Gene-Eluting Stents for the Prevention and Treatment of Coronary Restenosis. *Theranostics*, **4**, 175-200. <https://doi.org/10.7150/thno.7210>
- [64] Hashi, C.K., Zhu, Y., Yang, G.Y., Young, W.L., Hsiao, B.S., Wang, K., Chu, B. and Li, S. (2007) Antithrombogenic Property of Bone Marrow Mesenchymal Stem Cells in Nanofibrous Vascular Grafts. *Proceedings of the National Academy of Sciences, USA*, **104**, 11915-11920. <https://doi.org/10.1073/pnas.0704581104>
- [65] Stankus, J.J., Soletti, L., Fujimoto, K., Hong, Y., Vorp, D.A. and Wagner, W.R. (2007) Fabrication of Cell Microintegrated Blood Vessel Constructs through Electrohydrodynamic Atomization. *Biomaterials*, **28**, 2738-2746. <https://doi.org/10.1016/j.biomaterials.2007.02.012>
- [66] McMahon, S.R., Brummel Ziedins, K. and Schneider, D.J. (2016) Novel Oral Anti-coagulants in the Management of Coronary Artery Disease. *Coronary Artery Disease*, **27**, 412-419. <https://doi.org/10.1097/MCA.0000000000000387>
- [67] Oldgren, J., Budaj, A., Granger, C.B., Khder, Y., Roberts, J., *et al.* (2011) Dabigatran vs Placebo in Patients with Acute Coronary Syndrome on Dual Antiplatelet Therapy: A Randomized, Double-Blind, Phase II Trial. *European Heart Journal*, **32**, 2781-2789. <https://doi.org/10.1093/eurheartj/ehr113>
- [68] Della Pepa, G., Bozzetto, L., Annuzzi, G. and Rivellesse, A.A. (2017) Alirocumab for the Treatment of Hypercholesterolaemia. *Expert Review of Clinical Pharmacology*, **10**, 571-582. <https://doi.org/10.1080/17512433.2017.1318063>
- [69] Pham, A.Q., Patel, Y. and Gallagher, B. (2015) LCZ696 (Angiotensin-Nepriylsin Inhibition): The New Kid on the Heart Failure Block? *Journal of Pharmacy Practica*, **28**, 137-145. <https://doi.org/10.1177/0897190014568675>
- [70] Seki, T., Goto, K., Kansui, Y., Ohtsubo, T., Matsumura, K. and Kitazono, T. (2017) Angiotensin II Receptor-Nepriylsin Inhibitor Sacubitril/Valsartan Improves Endothelial Dysfunction in Spontaneously Hypertensive Rats. *Journal of American Heart Association*, **6**, pii: e006617. <https://doi.org/10.1161/JAHA.117.006617>
- [71] Vaduganathan, M. and Desai, A.S. (2016) Angiotensin-Nepriylsin Inhibition as a Paradigm for AII? *Current Cardiology Reports*, **18**, 115. <https://doi.org/10.1007/s11886-016-0784-z>
- [72] McMurray, J.J., Packer, M., Desai, A.S., Gong, J., Lefkowitz, M.P., Rizkala, A.R., *et al.* (2014) Angiotensin-Nepriylsin Inhibition versus Enalapril in Heart Failure. *New England Journal of Medicine*, **371**, 993-1004. <https://doi.org/10.1056/NEJMoal409077>
- [73] Chirgwin, K., Roblin, P.M. and Hammerschlag, M.R. (1989) *In Vitro* Susceptibilities of Chlamydia Pneumoniae (*Chlamydia* sp. Strain TWAR). *Antimicrobial Agents and Chemotherapy*, **33**, 1634-1635. <https://doi.org/10.1128/AAC.33.9.1634>
- [74] Schneider, C.A., Diedrichs, H., Riedel, K.D., Zimmermann, T. and Hopp, H.W. (2000) *In Vivo* Uptake of Azithromycin in Human Coronary Plaques. *American Journal of Cardiology*, **86**, 789-791, A9.
- [75] Anderson, J.L., Muhlestein, J.B., Carlquist, J., Allen, A., Trehan, S., Nielson, C., *et al.* (1999) Randomized Secondary Prevention Trial of Azithromycin in Patients with Coronary Artery Disease and Serological Evidence for Chlamydia Pneumoniae Infection. The Azithromycin in Coronary Artery Disease: Elimination of Myocardial

- Infection with Chlamydia (ACADEMIC) Study. *Circulation*, **99**, 1540-1547. <https://doi.org/10.1161/01.CIR.99.12.1540>
- [76] Neumann, F., Kastrati, A., Miethke, T., Pogatsa-Murray, G., Mehilli, J., Valina, C., *et al.* (2001) Treatment of Chlamydia Pneumoniae Infection with Roxithromycin and Effect on Neointimal Proliferation after Coronary Stent Placement (ISAR-3): A Randomized, Double-Blind, Placebo-Controlled Trial. *Lancet*, **357**, 2085-2089. [https://doi.org/10.1016/S0140-6736\(00\)05181-3](https://doi.org/10.1016/S0140-6736(00)05181-3)
- [77] Stone, A.F., Mendall, M.A., Kaski, J.C., *et al.* (2002) Effect of Treatment for Chlamydia Pneumoniae and Helicobacter Pylori on Markers of Inflammation and Cardiac Events in Patients with Acute Coronary Syndromes: South Thames Trial of Antibiotics in Myocardial Infarction and Unstable Angina (STAMINA). *Circulation*, **106**, 1219-1223. <https://doi.org/10.1161/01.CIR.0000027820.66786.CF>
- [78] Grayston, J.T. (2003) Antibiotic Treatment of Atherosclerotic Cardiovascular Disease. *Circulation*, **107**, 1228-1230. <https://doi.org/10.1161/01.CIR.0000056032.56396.89>
- [79] Cercek, B., Shah, P.K., Noc, M., *et al.* (2003) Effect of Short-Term Treatment with Azithromycin on Recurrent Ischemic Events in Patients with Acute Coronary Syndrome in the Azithromycin in Acute Coronary Syndrome (AZACS) Trial: A Randomised Controlled Trial. *Lancet*, **361**, 809-813. [https://doi.org/10.1016/S0140-6736\(03\)12706-7](https://doi.org/10.1016/S0140-6736(03)12706-7)
- [80] Rajiv, C., Manjuran, R.J., Sudhayakumar, N. and Haneef, M. (1996) Cardiovascular Involvement in Leptospirosis. *Indian Heart Journal*, **48**, 691-694.
- [81] Martinez, E., Sahni, S., Al Cheema, M. and Iftikhar, A. (2018) Vancomycin-Induced Coronary Artery Spasm: A Case of Kounis Syndrome. *British Medical Journal Case Reports*, pii: bcr-2017-222846. <https://doi.org/10.1136/bcr-2017-222846>
- [82] Saad, M.A., Abdel Salam, R.M., Kenawy, S.A. and Attia, A.S. (2015) Pinocembrin Attenuates Hippocampal Inflammation, Oxidative Perturbations and Apoptosis in a Rat Model of Global Cerebral Ischemia Reperfusion. *Pharmacological Reports*, **67**, 115-122. <https://doi.org/10.1016/j.pharep.2014.08.014>
- [83] Zhang, G.-M., Zhao, Z.-Y., Hu, H.-J., Yang, J. and Gu, G.Q. (2018) Effect of Pinocembrin Pre-Treatment on Expressions of Cx43 Protein and Claudin-1 in Myocardial Ischemia Cardiomyocytes of Arrhythmic Rats. *Tropical Journal of Pharmaceutical Research*, **17**, 415-422. <https://doi.org/10.4314/tjpr.v17i3.5>
- [84] Seki, A., Nishii, K. and Hagiwara, N. (2015) Gap Junctional Regulation of Pressure Fluid Force and Electrical Fields in the Epigenetics of Cardiac Morphogenesis and Remodeling. *Life Sciences*, **129**, 27-34. <https://doi.org/10.1016/j.lfs.2014.10.022>
- [85] Du Toit, E.F., Muller, C.A., MCCarthy, J. and Opie, L.H. (1999) Levosimendan: Effects of a Calcium Sensitizer on Function and Arrhythmias and Cyclic Nucleotide Levels during Ischemia/Reperfusion in the Langendorff-Perfused Guinea Pig Heart. *The Journal of Pharmacology and Experimental Therapeutics*, **290**, 505-514.
- [86] Meerson, F.Z., Belkina, L.M., Sazontova, T.G., Saltikova, V.A. and Arkhipenko, Y.V. (1987) The Role of Lipid Peroxidation in Pathogenesis of Arrhythmias and Prevention of Cardiac Fibrillation with Antioxidants. *Basic Research in Cardiology*, **82**, 123-138. <https://doi.org/10.1007/BF01907060>
- [87] Moraes, C.R., Buffolo, E., Moraes Neto, F., Rodrigues, J.V., Gomes, C.A., Branco, J.N. and Aguiar, L. (1996) Recurrence of Fibrosis after Endomyocardial Fibrosis Surgery. *Arquivos Brasileiros De Cardiologia*, **67**, 297-299. [In Portuguese]
- [88] Grimaldi, A., Ammirati, E., Karam, N., Vermi, A.C., *et al.* (2014) Cardiac Surgery For Patients with Heart Failure Due to Structural Heart Disease in Uganda: Access

to Surgery and Outcome. *Cardiovascular Journal of Africa*, **25**, 204-211.

<https://doi.org/10.5830/CVJA-2014-034>

- [89] D'Arbela, P.G., Mutazindwa, T., Patel, A.K. and Somers, K. (1972) Survival after First Presentation with Endomyocardial Fibrosis. *British Heart Journal*, **34**, 403-407. <https://doi.org/10.1136/hrt.34.4.403>
- [90] Mocumbi, A.O., Yacoub, S. and Yacoub, M.H. (2008) Neglected Tropical Cardiomyopathies, II: Endomyocardial Fibrosis: Myocardial Disease. *Heart*, **94**, 384-390. <https://doi.org/10.1136/hrt.2007.136101>
- [91] Mocumbi, A.O. and Ferreira, M.B. (2010) Neglected Cardiovascular Diseases in Africa: Challenges and Opportunities. *Journal of American College of Cardiology*, **55**, 680-687. <https://doi.org/10.1016/j.jacc.2009.09.041>
- [92] Lachaud, M., *et al.* (2018) Tropical Endomyocardial Fibrosis: Perspectives, PubMed. NCBI (National Center for Biotechnology Information).
- [93] Kutty, V.R., Abraham, S. and Kartha, C.C. (1996) Geographical Distribution of Endomyocardial Fibrosis in South Kerala. *International Journal Epidemiology*, **25**, 1202. <https://doi.org/10.1093/ije/25.6.1202>
- [94] Radhakumary, C., Kumari, T.V. and Kartha, C.C. (2001) Endomyocardial Fibrosis Is Associated with Selective Deposition of Type I Collagen. *Indian Heart Journal*, **53**, 486.
- [95] Cogswell, R., Schiller, N.B. and Acquatella, H. (2018) Endomyocardial Fibrosis. *UpToDate*.