

Inflammatory Tinea Manuum due to *Trichophyton erinacei* from an African Hedgehog

Coronado-Aguilar Alejandra¹, Perez-Olivos Mirta de Lourdes²,
Mayorga-Garibaldi Jorge Leonardo², Mayorga-Rodríguez Jorge², Córdova-Martínez Erika³,
Hernandez-Hernandez Francisca^{3*}

¹Private Practice, Guadalajara, Mexico

²Dermatologic Institute of Jalisco “Dr. Jose Barba Rubio”, Mycology Reference Center (CEREMI), Guadalajara, Mexico

³Department of Microbiology and Parasitology, School of Medicine, Nacional Autonomous University of Mexico (UNAM), Mexico City, Mexico

Email: *micoher@hotmail.com

How to cite this paper: Alejandra, C.-A., de Lourdes, P.-O.M., Leonardo, M.-G.J., Jorge, M.-R., Erika, C.-M. and Francisca, H.-H. (2018) Inflammatory Tinea Manuum due to *Trichophyton erinacei* from an African Hedgehog. *Advances in Microbiology*, 8, 1021-1028.

<https://doi.org/10.4236/aim.2018.812069>

Received: November 28, 2018

Accepted: December 25, 2018

Published: December 28, 2018

Copyright © 2018 by authors and Scientific Research Publishing Inc. This work is licensed under the Creative Commons Attribution International License (CC BY 4.0).

<http://creativecommons.org/licenses/by/4.0/>



Open Access

Abstract

The zoophylic dermatophytes, as *Trichophyton erinacei*, frequently cause very inflammatory tinea in the human host. This dermatophyte is carried by some pets, particularly by the terrestrial hedgehog. Herein, we present the case of a 22-year-old male student with an exudative erythematous scaly plaque on his right fifth finger for 1 month. He had a pet African hedgehog (*Atelerix albiventris*). KOH examination demonstrated hyphae compatible with dermatophytes. The culture revealed a white, radiated dusty colony. PCR sequencing of the region ITS1-5.8S-ITS2 identified *T. erinacei*. The final diagnosis was inflammatory tinea manuum due to *T. erinacei*. Clinical and mycological cure was achieved after treatment with oral terbinafine 250 mg/day × 1 month.

Keywords

Trichophyton erinacei, Hedgehog, Tinea, Dermatophytes

1. Introduction

Trichophyton erinacei is a zoophylic dermatophyte, member of the *Trichophyton mentagrophytes* complex, known to cause superficial skin infections in humans. Usually, it is carried by the 17 species of terrestrial hedgehogs, either as an infection or as asymptomatic carriers [1] [2]. Terrestrial hedgehogs (*Atelerix albiventris*) have more often become attractive animals to have as pets, but they

also transmit several zoonosis, including salmonellosis, mycobacteriosis, and protozoan infections like *Cryptosporidium parvum* [3], but mainly dermatophytosis. Mycoses transmitted by hedgehogs include mainly tinea manuum [4], and occasionally tinea capitis, kerion celsi [2], tinea barbae [5], tinea faciei, and tinea corporis [6].

Human infection by *T. erinacei* occurs by direct contact with the hedgehog, or through abrasions or wounds. About 76% of cases involve the extremities, specially hands and wrists [4] [6] [7] [8]. Clinically, it presents as unilateral, erythematous, scaly cutaneous plaques with variable vesicles, pustules, and erosions [2] [4] [8] [9]. These infections occur worldwide. The first case was described in New Zealand [10], followed later by cases from United Kingdom, Western Europe, and more recently, Japan and Korea [7]. In Mexico, a previous case was reported [2]. Herein, we present a case of inflammatory tinea manuum due to *Trichophyton erinacei* from a pet hedgehog.

2. Case Report

A 22 year-old male student complained of a 1-month history of skin lesions on his right hand. The patient does not remember a history of trauma. A general physician treated him with topical antibiotics and steroids with mild temporal improvement.

In the physical examination, there were 3 erythematous scaly exudative plaques measuring between 2×2 cm and 1×1.5 cm on his right 5th finger (**Figure 1**). We suspected an infection and samples were obtained for bacterial, mycobacterial, and fungal cultures. KOH examination revealed hyphae compatible with dermatophytes. The bacterial and mycobacterial cultures were negative. Mycologic culture in Sabouraud Dextrose Agar (SDA) incubated at 28°C grew a flat, white, dusty colony with elevated center. Microscopic examination of the colony sample contrasted with methylene blue showed thin branched filaments, some curved, with multiple sessile, microconidia compatible with *Trichophyton* sp. In a second medical consultation the patient stated that he had a pet African hedgehog (*Atelerix albiventis*). KOH microscopic examination of hedgehog's scales showed abundant hyphae but culture in SDA was negative. With this background the dermatophyte was studied by morphological and molecular techniques.

3. Morphologic Study

A sample from the positive culture was re-cultured in Casamino Acids agar and Borelli agar for microscopic and macroscopic morphologic study (**Figure 2** and **Figure 3**). The urease test was positive after 4 days.

1) Molecular study

A sample from monosporic culture was placed on Dextrose Sabouraud Broth for 5 days at 28°C at 90 rpm. DNA was extracted using the Exgene Plant SV mini kit (GeneAll, Biotechnology, Korea). PCR was performed to amplify the

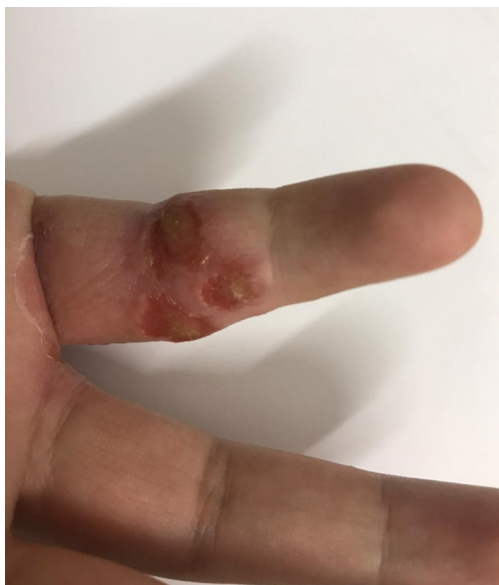

Figure 1. Erythematous pustular and eroded plaque on the 5th right finger caused by *Trichophyton erinacei*, in a male patient infected through contact with his pet hedgehog.

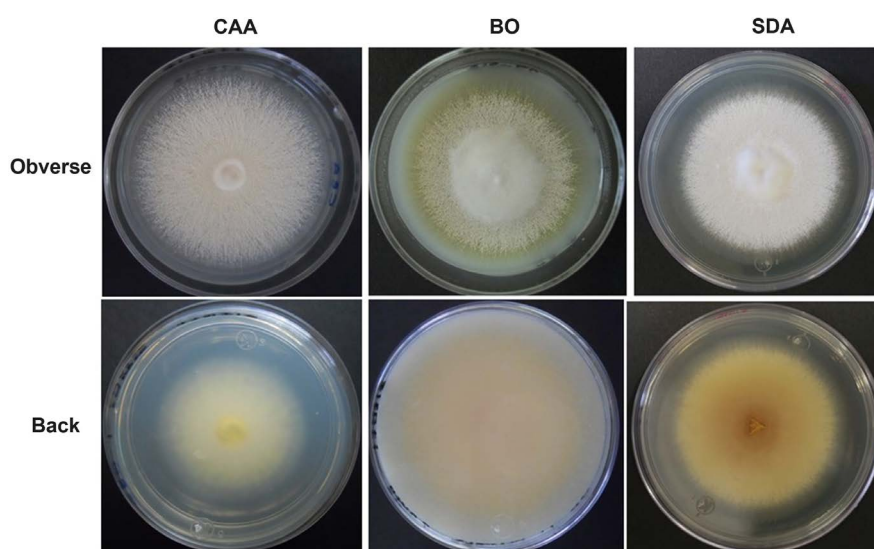


Figure 2. *Trichophyton erinacei* culture in various media after 12 days at 28°C. CAA: Casamino Acids agar. Ivory white granular colony with slight yellow pigment in the reverse. BO: Borelli agar. Granular colony with cotton-like central elevation and remarkable yellow pigment in the reverse. SDA: Sabouraud dextrose agar. White granular colony with elevated center and slight brown pigment in the reverse side.

ITS1-5.8S-ITS2 region of the ribosomal RNA. In a 50 µL final volume, the reaction mixture contained 100 ng of DNA, buffer 1X, Taq DNA polymerase (recombinant) 3.5 U, MgCl₂ 2 mM, dNTPs 0.25 mM (Thermo Fisher Scientific, USA); oligonucleotides ITS1 (5'-TCC GTA GGT GAA CCT GCG G-3') and ITS4 (5'-TCC TCC GCT TAT TGA TAT GC-3') [11] (Merck, Germany). The cycles and temperatures were as follows: one 5-min cycle at 96°C, forty cycles of 94°C, 30 s, 58°C, 30 s and 72°C, 30 s. In addition, a final cycle at 72°C, 5 min.

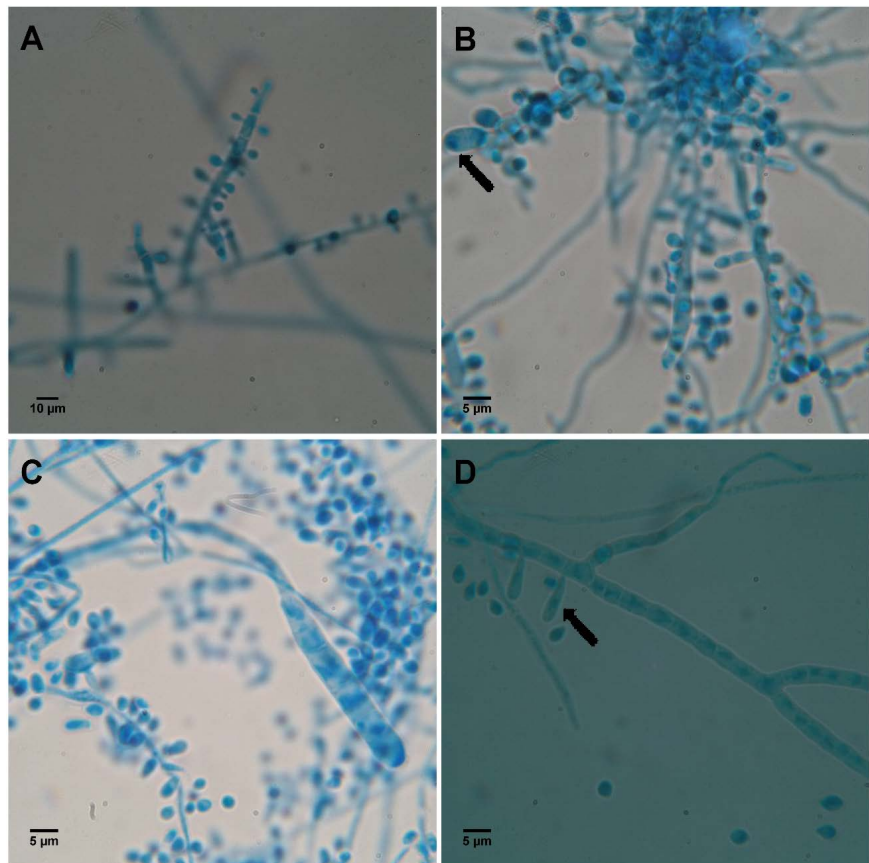


Figure 3. Microscopic aspect of *Trichophyton erinacei* grown in ADS and stained with lactophenol blue. A: Thick and erect hyphae with abundant round conidia. (Scale: 10 µm). B: Smooth and thin wall macroconidium, with several septa (Scale 5 µm). C: Abundant round conidia with thick hyphae and vesicular structures (arrow) (Scale 5 µm). D: Thick hyphae with long pyriform conidia (arrow) (Scale 5 µm).

The resulting amplicon (700 pb) was visualized in 1.5% agarose gel, stained with GelRed (Biotium, USA), and purified with the DNA Clean and Concentrator™-5 kit (Zymo Research, USA) for sequencing. (Figure 4) The resulting sequence was compared with the GenBank (<https://www.ncbi.nlm.nih.gov>; August 13, 2018). Analysis indicated 100% identity with 10 strains of *Trichophyton erinacei*, and 11 of *Arthroderma benhamiae* (sexual form of *T. erinacei*).

After gathering all the clinical, mycologic, and molecular findings, the final diagnosis was inflammatory tinea manuum due to *Trichophyton erinacei* acquired from a pet hedgehog (*Atelerix albiventris*). Clinical and mycologic cure was achieved after treatment with terbinafine 250 mg P.O. daily for 30 days. Only a residual erythematous macule remained (Figure 5).

2) Sensitivity to antifungals

In vitro susceptibility testing using the microdilution broth method according to the M38-A2 guidelines showed resistance to fluconazole and the following MIC levels: itraconazole 0.5 µg/mL, posaconazole 0.03 µg/mL, fluconazole 64 µg/mL, voriconazole 0.06 µg/mL, amphotericin B 4 µg/mL, terbinafine 0.06 µg/mL and ciclopirox olamine 0.25 µg/mL.

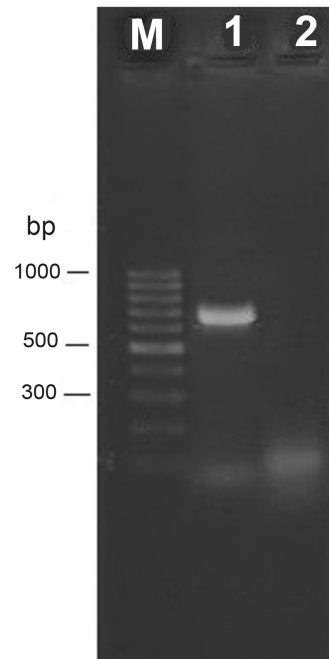


Figure 4. PCR product electrophoresed in a 1.5% agarose gel. The product size is about 700 bp which was purified and sent for sequencing. M: Molecular weight marker 100 bp; 1: *T. erinacei* amplicon; 2: Negative PCR control.

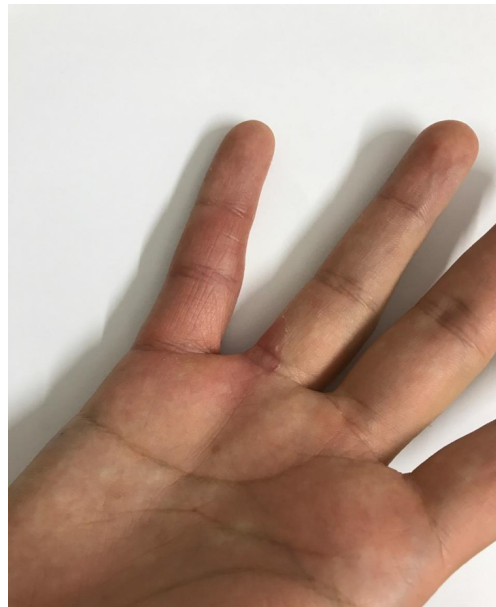

Figure 5. Lesion clinical appearance after treatment with oral terbinafine for 30 days. Residual erythema is only observed.

4. Discussion

Trichophyton erinacei (J.M.B. Sm. & Marples; Quaife 1966) is a zoophilic dermatophyte whose natural host is the hedgehog. The rate of infection in humans is 20% - 47% [12]. A medline and Scopus search up until October 29, 2018, revealed 30 reports (mostly reviews) with 54 cases in humans [6] [8] [13]. The first

case was reported by Smith & Marples in 1963 [10]. Contact with African hedgehogs is a common trait. Of the 54 cases reported in the literature, 58.6% had contact with a hedgehog, and 13.7% with guinea pigs. The remaining cases have been acquired from the soil [6] [8] or humans [5]. In our case, authors consider hedgehog as the infection source, as in the direct examination of scales, many fungal filaments were observed, despite culture was negative. Usually, there are single lesions, but several cases had 2 or 3 separate body areas affected [14] [15]. Some cases have presented as Kerion [14] [16]. In Mexico, Lammoglia *et al.* reported the case of a 31-year-old male with tinea incognito and Majocchi's granuloma by *T. erinacei* from a hedgehog, treated successfully with terbinafine 250 mg P.O. daily for 6 weeks [2]. Herein, we have presented the second case from Mexico.

The differential diagnosis of any inflammatory tinea on hands or feet includes dyshidrotic eczema and contact dermatitis. Molecular testing is necessary to confirm the etiologic diagnosis of tineas, including sequencing the ITS region of ribosomal DNA and morphologic studies [2] [4] [7] [12] [17].

Treatment of extensive lesions (hyperkeratotic, inflammatory, folliculitis) requires systemic terbinafine or itraconazole for 1 - 12 weeks [1] [6] [14] [16]. Topical treatment with imidazoles, allylamines, and morpholines is useful for superficial cases, in pregnant or lactating women, or if significant oral drug interactions exist. Cure rates are approximately 80%. Additionally, topical treatment is given as an adjuvant during oral therapy, and to prevent recurrence after systemic therapy [18] [19]. It is important to treat the hedgehog too, even if it is asymptomatic [20] [21].

In our knowledge there are no reports of *in vitro* antifungal susceptibility studies for *T. erinacei*. In this study a high MIC for amphotericin B (4 µg/mL) and a resistance level for fluconazole (64 µg/mL) were found. Our patient was successfully treated with terbinafine (250 mg/day), a drug that showed a high *in vitro* susceptibility.

The African pygmy hedgehog (*Atelerix albiventris*), member of the family Erinaceidae, is widely known as the four-toed hedgehog. In recent years, these hedgehogs have become popular as domestic pets all over the world. Several studies in these animals have shown the presence of *T. erinacei* in their scales or spines without clinical manifestations, but there are also cases in which severe infectious symptoms caused by this dermatophyte are reported [19].

5. Conclusion

It is increasingly common to have exotic pets in the home, which represent a potential source of zoonotic infection. Here, we present the second Mexican case of an inflammatory tinea of the hand, whose etiology was determined by morphology and PCR-sequencing as *Trichophyton erinacei*. It is important to make a detailed clinical history to support the possible source of infection and etiology of an inflammatory dermatophytosis.

Acknowledgements

We thank Dr. Patricia Manzano-Gayosso for performing susceptibility testing (Department of Microbiology and Parasitology, School of Medicine, National Autonomous University of Mexico), and Dr. Carlos Garcia Rementeria for the translation of the text.

Conflicts of Interest

The authors declare no conflicts of interest regarding the publication of this paper.

References

- [1] Molina de Diego, A. (2011) Aspectos clínicos, diagnósticos y terapéuticos de las dermatofitosis. *Enfermedades Infecciosas y Microbiología Clínica*, **29**, 33-39. [https://doi.org/10.1016/S0213-005X\(11\)70025-8](https://doi.org/10.1016/S0213-005X(11)70025-8)
- [2] Lammoglia-Ordiales, L., Martínez-Herrera, E., Toussaint-Caire, S., Arenas, R. and Moreno-Coutiño, G. (2018) Mexican Case of Tinea Incognita and Granuloma de Majocchi Acquired from a Hedgehog. *Revista Chilena de Infectología*, **35**, 204-206. <https://doi.org/10.4067/s0716-10182018000200204>
- [3] Keymer, I.F., Gibson, E.A. and Reynolds, D.J. (1991) Zoonoses and Other Findings in Hedgehogs (*Erinaceus europaeus*): A Survey of Mortality and Review of the Literature. *The Veterinary Record*, **128**, 245-249. <https://doi.org/10.1136/vr.128.11.245>
- [4] Kromer, C., Nenoff, P., Uhrlaß, S., Apel, A., Schön, M.P. and Lippert, U. (2018) *Trichophyton erinacei* Transmitted to a Pregnant Woman from Her Pet Hedgehogs. *JAMA Dermatology*, **154**, 967-968. <https://doi.org/10.1001/jamadermatol.2018.1124>
- [5] Sidwell, R.U., Chan, I., Francis, N. and Bunker, C.B. (2014) *Trichophyton erinacei* Kerion Barbae from a Hedgehog with Direct Osculatory Transfer to Another Person. *Clinical and Experimental Dermatology*, **39**, 38-40. <https://doi.org/10.1111/ced.12197>
- [6] Concha, M., Nicklas, C., Balcells, E., Guzmán, A.M., Poggi, H., León E. and Fich, F. (2012) The First Case of Tinea Faciei Caused by *Trichophyton mentagrophytes* var. *erinacei* Isolated in Chile. *International Journal of Dermatology*, **51**, 283-285. <https://doi.org/10.1111/j.1365-4632.2011.04995.x>
- [7] Perrier, P. and Monod, M. (2015) Tinea Manuum Caused by *Trichophyton erinacei* First Report in Switzerland. *International Journal of Dermatology*, **54**, 959-960. <https://doi.org/10.1111/ijd.12291>
- [8] Hui, L., Choo, K.J.L., Tan, J.B.X. and Yeo, Y.W. (2017) Inflammatory Tinea manuum due to *Trichophyton erinacei* from a Hedgehog: A Case Report and Review of the Literature. *Journal of Bacteriology and Mycology*, **4**, 1057.
- [9] Nenoff, P., Handrick, W., Krüger, C., Vissiennon, T., Wichmann, K., Gräser, Y. and Tchernev, G. (2012) Dermatomycoses due to Pets and Farm Animals: Neglected Infections? *Hautarzt*, **63**, 848-858. <https://doi.org/10.1007/s00105-012-2379-y>
- [10] Smith, J.M. and Marples, M.J. (1963) *Trichophyton mentagrophytes* var. *erinacei*. *Sabouraudia: Journal of Medical and Veterinary Mycology*, **3**, 1-10.
- [11] Luo, G. and Mitchell, T.G. (2002) Rapid Identification of Pathogenic Fungi Directly from Cultures by Using Multiplex PCR. *Journal of Clinical Microbiology*, **40**,

2860-2865. <https://doi.org/10.1128/JCM.40.8.2860-2865.2002>

- [12] Philpot, C.M. and Bowen, R.G. (1992) Hazards from Hedgehogs: Two Case Reports with a Survey of the Epidemiology of Hedgehog Ringworm. *Clinical and Experimental Dermatology*, **17**, 156-158. <https://doi.org/10.1111/j.1365-2230.1992.tb00193.x>
- [13] Fumeaux, J., Mock, M., Ninet, B., Jan, I., Bontems, O., Léchenne, B., Lew, D., Pannizzon, R.G., Jousson, O. and Monod, M. (2004) First Report of *Arthroderma benhamiae* in Switzerland. *Dermatology*, **208**, 244-250. <https://doi.org/10.1159/000077311>
- [14] Jury, C.S., Lucke, T.W. and Bilsland, D. (1999) *Trichophyton erinacei*: An Unusual Cause of Kerion. *The British Journal of Dermatology*, **141**, 606-607. <https://doi.org/10.1046/j.1365-2133.1999.03092.x>
- [15] Schauder, S., Kirsch-Nietzki, M., Wegener, S., Switzer, E. and Qadripur, S.A. (2007) From Hedgehogs to Men. Zoophilic Dermatophytosis Caused by *Trichophyton erinacei* in Eight Patients. *Hautarzt*, **58**, 62-67. <https://doi.org/10.1007/s00105-006-1100-4>
- [16] Jang, M.S., Park, J.B., Jang, J.Y., Yang, M.H., Kim, J.H., Lee, K.H., Hwangbo, H. and Suh, K.S. (2017) Kerion Celsi Caused by *Trichophyton erinacei* from a Hedgehog Treated with Terbinafine. *The Journal of Dermatology*, **44**, 1070-1071. <https://doi.org/10.1111/1346-8138.13647>
- [17] Lee, D.W., Yang, J.H., Choi, S.J., Won, C.H., Chabg, S.E., Lee, M.W., Choi, J.H., Moon, K.C. and Kim, M.N. (2011) An Unusual Clinical Presentation of Tinea Faciei Caused by *Trichophyton mentagrophytes* var. *erinacei*. *Pediatric Dermatology*, **28**, 210-212. <https://doi.org/10.1111/j.1525-1470.2011.01391.x>
- [18] Del Palacio, A., Garau, M. and Cuétara, M.S. (2002) Current Treatment of Dermatophytosis. *Revista Iberoamericana de Micología*, **19**, 68-71.
- [19] Abarca, M.L., Castellá, G., Martorell, J. and Cabañes, F.J. (2017) *Trichophyton erinacei* in Pet Hedgehogs in Spain: Occurrence and Revision of Its Taxonomic Status. *Medical Mycology*, **55**, 164-172. <https://doi.org/10.1093/mmy/myw057>
- [20] Choi, E., Huang, J., Chew, K.L., Jaffar, H. and Tan, C. (2018) Pustular Tinea Mammum from *Trichophyton erinacei* Infection. *JAAD Case Reports*, **4**, 518-520. <https://doi.org/10.1016/j.jidcr.2018.01.019>
- [21] Bexton, S. and Nelson, H. (2016) Comparison of Two Systemic Antifungal Agents, Itraconazole and Terbinafine, for the Treatment of Dermatophytosis in European Hedgehogs (*Erinaceus europaeus*). *Veterinary Dermatology*, **27**, 500-e133. <https://doi.org/10.1111/vde.12378>