

Clinical Significance of Left Atrial Anatomic Abnormalities Identified by Cardiac Computed Tomography

Ara V. Vehian¹, Brian G. Choi¹, Satinder S. Rekhi², Heather A. Young³, Raman S. Dusaj⁴, Robert K. Zeman²

¹Department of Medicine, George Washington University School of Medicine and Health Sciences, Washington DC, USA

²Department of Radiology, George Washington University School of Medicine and Health Sciences, Washington DC, USA

³Department of Epidemiology and Biostatistics, George Washington University School of Public Health and Health Services, Washington DC, USA

⁴Division of Cardiovascular Medicine, College of Medicine, University of Florida, Gainesville, USA

Email: avehian@mednet.ucla.edu

Received 25 December 2014; accepted 15 January 2015; published 19 January 2015

Copyright © 2015 by authors and Scientific Research Publishing Inc.

This work is licensed under the Creative Commons Attribution International License (CC BY).

<http://creativecommons.org/licenses/by/4.0/>



Open Access

Abstract

Purpose: The clinical significance of newly identified left atrial anatomic abnormalities (LAAA)—accessory appendages, diverticula, septal pouches—by multidetector CT (MDCT) remains unclear. Similar anatomical outpouchings, *i.e.*, the left atrial appendage, have been associated with cardioembolisms and arrhythmia. To test the hypothesis that LAAA are also associated with increased risk of these events, we performed a retrospective analysis to examine the association of LAAA in patients undergoing CT with embolic events and arrhythmia. **Methods:** 242 patients (mean age 56 SD 12 years, 41% female) were selected who had CT coronary angiography performed with 64-row MDCT between 2007 and 2012 if complete clinical history records were available. CT images were independently reviewed for the presence of LAAA. Association of cerebrovascular accident (CVA) or transient ischemic attack (TIA), atrial fibrillation, and palpitations to LAAA was calculated using odds ratios (OR) with 95% confidence interval (CI) and Fisher's exact test. **Results:** After adjusting for age, sex, hypertension, dyslipidemia and diabetes via multiple logistic regression, patients with accessory appendages are more likely to have reported palpitations (OR: 1.80; CI: 1.03 - 3.16). Patients with diverticula and septal pouches are significantly older than those without these abnormalities ($p = 0.01$ and $p = 0.02$, respectively). Septal pouches are associated with diabetes (OR: 2.29; 95%CI: 1.15 - 4.54). **Conclusions:** Accessory left atrial appendages are associated with palpitations. Patients with septal pouches and diverticula are significantly older than those patients without these anatomic abnormalities, suggesting age dependency

of these findings. None of these anatomic abnormalities were associated with thromboembolic events after adjustment for potentially confounding comorbidities.

Keywords

Left Atrium, Anatomic Abnormalities, Accessory Appendage, Diverticula, Septal Pouch

1. Introduction

CT Coronary Angiography (CTCA) has been established as the gold standard for non-invasive definition of coronary anatomy [1] [2]. In addition, electrocardiographically-gated (ECG) multidetector CT (MDCT) scans have allowed for unprecedented three-dimensional spatial resolution for morphologic evaluation of the left atrium [3] [4]. As a result of constant enhancement in MDCT imaging, numerous previously undescribed left atrial anatomic abnormalities (LAAA) including accessory appendages, diverticula and septal pouches have been identified with remarkably high prevalence [3] [5]-[13].

The discovery of these LAAA is relatively new; however, their clinical significance remains unclear. Better understanding of LAAA has the potential to enhance management and reduce their potential complications. Additionally, proper identification of these structures radiographically is essential, as they can often be mistaken for post-ablation injuries rather than anatomic variants. Atrial fibrillation originating from the left atrium has been implicated in cerebrovascular accidents (CVA) and transient ischemic attacks (TIA) [14] [15]. Recently, ectopic fibrillatory activity and thrombus has been described in patients with accessory appendages and diverticula [10] [13] [16] [17]. Septal pouches, given their blind end morphology, have been implicated in case reports of thromboembolic disease as well as arrhythmia [5] [18]-[20].

We performed a blinded retrospective analysis in a series of patients who underwent CTCA to determine the clinical significance of these LAAA with regards to embolic potential and arrhythmogenic burden with the hypothesis that the presence LAAA is associated with these clinical findings. Patients with the presence of LAAA were reviewed for the presence of embolic events as well as occurrence of documented arrhythmia and palpitations and were compared to a control group of scanned patients without LAAA.

2. Methods

2.1. Patient Selection

We conducted a retrospective analysis of 302 consecutive patients who underwent clinically-indicated CTCA for coronary evaluation performed with our current imaging system at the George Washington University Hospital from 2007 to 2012. Patients met selection criteria if they underwent clinically indicated CTCA and had complete clinical histories available for review. A clinical history was determined to be complete if it could be assessed for demographic information, pertinent medical history, and the CTCA indication. Complete clinical histories were available for 242 patients (mean age 56 SD 12 years, 41% female). The team of clinicians analyzing patient charts was blind to the presence or absence of LAAA. Our institutional review board approved the investigation and provided a waiver of informed consent for this retrospective study.

2.2. Image Acquisition

Patients underwent clinically indicated CTCA performed with 64-row MDCT (GE Lightspeed VCT; GE Healthcare, Waukesha, WI) with the use of a test-bolus method for image acquisition timing. All patients were in sinus rhythm and were treated with metoprolol tartrate to achieve a resting heart rate of less than 65 beats/min. Patients were also premedicated with 0.4 mg of sublingual nitroglycerin before image acquisition. Iodixanol or iopamidol contrast was injected through an upper extremity peripheral intravenous catheter with the use of a triphasic administration protocol (mean contrast volume, 115 ± 4 mL; range, 100 - 145 mL). Image acquisition was timed to peak contrast enhancement in the aortic root during end-inspiratory breath-hold. CTCA (0.625-mm collimation) was performed with a tube voltage of 120 kVp and a weight-based determination of milliAmperes. ECG-gating was preferentially prospectively triggered unless significant R-R variability was seen during test

bolus administration, in which case the CTCA was retrospectively gated.

2.3. Image Interpretation

All CT images were retrospectively reviewed by a team of radiologists (authors SR and RKZ). The radiologists interpreting images were blinded to the patients' clinical histories. All abnormal anatomical outpouchings visualized in the left atrium were recorded and detailed according to their morphology: accessory appendage, diverticulum, or septal pouch. Any structure with a discernible ostium at the left atrium with a neck and body that displayed irregular contours suggesting the presence of pectinate muscle was deemed an accessory appendage [6]. An atrial diverticulum was identified if the structure had a saclike or tubiform shape with a broad based ostium and a smooth contour to its body [6] [11]. The interatrial septum was surveyed to assess for completeness of fusion of its components. When fusion was noted only at the caudal limit at the zone of overlap of the interatrial septum, the resulting pouch opening into the left atrium was defined as a septal pouch [5]. Representative images of accessory appendages are shown in **Figure 1**. Presence, absence and number of left atrial accessory appendages, diverticula and septal pouches were documented in each case. The presence or absence of thrombus within each LAAA was also noted.

2.4. Clinical History Analysis

The team of clinicians (authors AVV and BGC) independently reviewing patient charts for pertinent clinical histories was blind to the radiographic findings. Patient charts were reviewed for demographic information including age and sex, history of documented ischemic CVA, TIA, arrhythmia, patient-reported palpitations, medications, and indication for CTCA. A detailed review of confounding variables such as systolic and diastolic blood pressure readings, diabetes, and lipid values was also performed. If multiple recordings were present for any confounding variable, the recordings closest in temporal proximity to each patient's CT were chosen.

2.5. Statistical Analysis

To prevent bias and ensure study blindness, the clinical data and radiographic findings were compiled together by an independent statistician at our institution. Demographic data were summarized by mean \pm standard deviation or by frequency distributions as appropriate. Frequency of LAAA and clinical events were tabulated. The association between clinical events (CVA or TIA, atrial fibrillation, and palpitations) and LAAA were described using odds ratios (OR) and 95% confidence intervals (CI). Fisher's exact test was used to determine the significance of an association between a clinical event and LAAA at a $p < 0.05$ level. Two sample t-tests were used to examine differences in age between those with and without abnormalities and chi-square analysis was used to examine frequency differences between those with and without abnormalities. Multiple logistic regression models analysis was performed for those LAAAs and clinical events that had a significant bivariable association. The multiple logistic regression models included covariates that could potentially confound the association be-

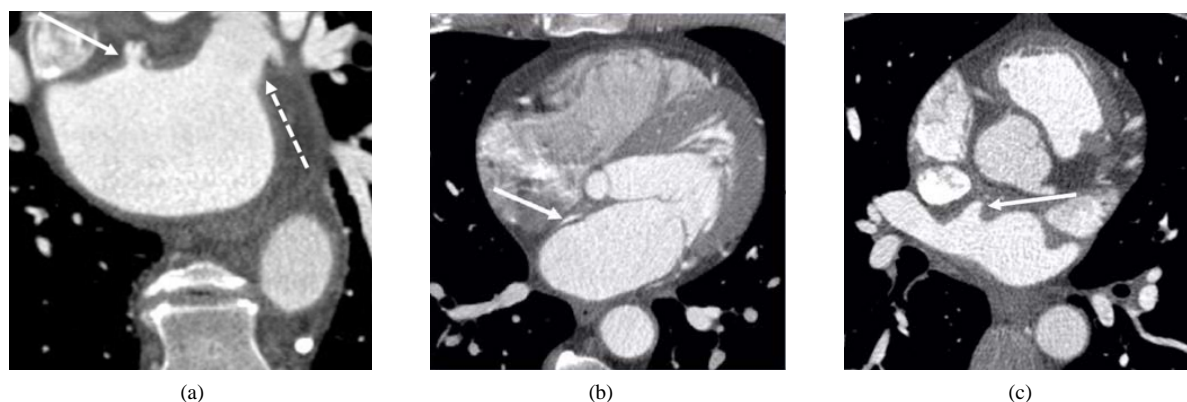


Figure 1. (a) Coronal view of the left atrium. Solid Arrow: accessory appendage with small neck and irre irregular contour, suggesting pectinate muscles. Broken Arrow: left atrial appendage; (b) Axial view of the left atrium. Solid Arrow: septal pouch; (c) Axial view of the left atrium. Solid Arrow: left atrial diverticulum with broad based ostium and smooth contour.

tween LAAA and a clinical event. The multiple logistic regression analysis was adjusted for age as a continuous variable and diabetes, hypertension, dyslipidemia and sex as dichotomous variables. SAS version 9.3 (SAS Institute, Cary, NC) was used to conduct the analysis.

3. Results

Of the 242 patients retrospectively reviewed (144 men and 98 women), mean age was 56 SD 12 years. The most common indication for CTCA was chest pain (70%). Hypertension was present in 133 patients (55%). Forty patients (17%) had a history of diabetes. Ninety patients (37%) had a history of dyslipidemia. Detailed demographic information, medical history and CTCA indications for the study cohort are detailed in **Table 1**.

Among the patients, 68 (28%) demonstrated a total of 76 accessory left atrial appendages. Fifty-three patients (22%) had a combined number of 59 left atrial diverticula. Ninety-three patients (38%) had septal pouches present. The mean age was 56 SD 12 years in patients with accessory left atrial appendages, 60 SD 11 years in patients with diverticula, and 58 SD 11 in patients with septal pouches. Those patients with diverticula and septal pouches were significantly older than those without these abnormalities ($p = 0.01$ and $p = 0.02$, respectively). Patients with septal pouches were more likely to have a documented history of diabetes (OR: 2.29; 95%CI: 1.15 - 4.54) when compared to those without septal pouches. Twenty-nine patients (12%) had a documented embolic history of CVA or TIA. Ninety-five patients (39%) had a documented history of atrial fibrillation or reported palpitations. The proportion of LAAA and clinical events is detailed in **Table 2**. No thrombi were identified in either LAAA or the left atrial appendage in any patient.

Bivariable analysis of each LAAA independently revealed that when compared to patients without the specified abnormality, patients with a demonstrated accessory appendage or septal pouch were 2.46 (CI 1.04 - 5.79) times more likely to have a history of CVA or TIA, patients with accessory appendage were 2.55 (CI 1.43 - 4.55) times more likely to report palpitations, and patients with accessory appendage were 2.02 (CI 1.14 - 3.56) times more likely to have a history of atrial fibrillation or reported palpitations. No statistically significant clinical associations were identified with left atrial diverticula. Complete unadjusted results for the association between LAAA and clinical events are found in **Table 3**. After adjusting for age, sex, hypertension, dyslipidemia and diabetes via multiple logistic regression, the only clinical association retained with LAAA was a history of reported palpitations in patients with accessory appendages (OR: 1.80; CI: 1.03 - 3.16). None of the other associations between LAAA and clinical events were significantly elevated after controlling for the previously mentioned covariates.

Table 1. Demographic and clinical characteristics of patients undergoing CTCA.

Characteristic	All Patients (n = 242)	AA* (n = 68)	Diverticula	SP† (n = 93)
Age, mean (SD‡)	56(12)	56(12)	60 (11)	58 (11)
Female, n (%)	98 (41)	26 (38)	20 (38)	34 (37)
Hypertension, n (%)	133 (55)	32 (47)	28 (53)	54 (58)
Diabetes, n (%)	40 (17)	7 (10)	10 (19)	22 (24)
Dyslipidemia, n (%)	90 (37)	28 (41)	21 (40)	35 (38)
Indication for CTCA	n (%)			
Chest pain	170 (70)			
Arrhythmia	19 (8)			
Dyspnea on exertion	8 (3)			
Abnormal stress test	8 (3)			
Syncope	8 (3)			
Stroke	3 (1)			
Pulmonary htn	3 (1)			
Other	23 (10)			

*AA: accessory appendage; †SP: septal pouch; ‡SD: standard deviation.

Table 2. Proportion of LAAA and clinical events in patients undergoing CTCA (n = 242).

LAAA Type	n (%)
Accessory Appendage	68(28)
Diverticulum	53 (22)
Septal Pouch	93 (39)
Clinical Events	n (%)
CVA or TIA	170 (70)
Atrial Fibrillation	19 (8)
Palpitations	8 (3)

Table 3. Association of LAAA to arrhythmic events and embolic events, odds ratio (95% confidence interval).

LAAA Type	Atrial Fibrillation	Palpitations	Atrial Fibrillation or Palpitations	CVA or TIA
Accessory Appendage	0.25 (0.06, 1.09)	2.55 (1.43, 4.55)	2.02 (1.14, 3.56)	1.17 (0.51, 2.73)
Diverticulum	1.48 (0.54, 4.03)	0.88 (0.46, 1.69)	1.02 (0.55, 1.90)	0.92 (0.35, 2.39)
Septal Pouch	1.22 (0.46, 3.03)	0.80 (0.46, 1.38)	0.83 (0.49, 1.42)	2.17 (0.99, 4.76)
Accessory Appendage or Septal Pouch	0.61 (0.25, 1.50)	1.08 (0.64, 1.85)	0.97 (0.58, 1.63)	2.46 (1.04, 5.79)

4. Discussion

To our knowledge, the present data are the first to show significant associations of accessory left atrial appendages, diverticula, and septal pouches with clinical variables. Our findings are hypothesis generating as they suggest that accessory appendages may be clinically significant and should be considered for additional investigation. In this retrospective study of patients being examined for coronary disease, a higher proportion of patients with LAAA reported palpitations. Our results may hold relevant implications in the evaluation of patients with palpitations if they possess accessory left atrial appendages. In our analysis, left atrial diverticula and septal pouches appear to be benign findings clinically; however, their investigation provides a novel understanding of their associations with patient age and confounding medical history.

We have demonstrated that accessory left atrial appendages are associated in patients with reported palpitations. The prevalence of accessory appendages in our investigation (28%) is in congruence with preceding studies which have shown prevalence between 10% - 28% [6] [7] [9] [12] [21]. Moreover, accessory left atrial appendages have been implicated as the source of ectopy in patients with symptomatic atrial fibrillation refractory to medical treatment [16] [17]. Although some have contended the clinical significance of accessory appendages, describing these structures as anatomic variants as opposed to pathologic findings, the current analysis attempts to elucidate this question [6]. Two recent studies found no difference in prevalence of left atrial accessory appendages and diverticula between patients with atrial fibrillation and patients in sinus rhythm [9] [12]. The present study is novel in its examination of each LAAA as the independent variable in assessing its association with arrhythmia. Palpitations may be associated with arrhythmia; the arrhythmogenicity of accessory left atrial appendages is yet to be established but the found association suggests additional investigation may be warranted.

By definition, the cardinal difference between accessory appendages and diverticula of the left atrium is the composition of their wall structure. Diverticula are smooth walled, can be tubiform, and lack the pectinate muscle which define accessory appendages [6] [11]. Well characterized in the literature, the pectinate-lined left atrial appendage is an anatomic outpouching not only implicated in arrhythmia, but is also a common location for thrombus formation [14] [22]. Interestingly, pectinate muscle of the right atrium has been shown to contribute to wave breakup and fibrillatory activity and has been speculated to act as anchor points for reentry in atrial fibrillation [23]. Thus, it is conceivable that these accessory appendages in the left atrium, with trabeculated walls composed of pectinate, may serve as a nidus for atrially-based arrhythmias when compared to smooth-walled

diverticula. This observation has clinical importance because evidence linking such a prevalent anatomic abnormality to patient-reported palpitations has the potential to provide further insight into the mechanism of arrhythmia.

This study is the first to examine the association between LAAA and embolic events in patients undergoing CTCA. The current analysis shows that association of accessory appendages or septal pouches with CVA or TIA disappears after adjusting for age, sex, hypertension, diabetes and dyslipidemia. This finding is in accord with a recent study by Tugcu *et al.*, which found no association between septal pouches and ischemic strokes in patients evaluated by trans-esophageal echocardiography [24]. The left atrial appendage's role in systemic embolization has been established; however, the pathogenesis of embolic events in patients with LAAA has been a subject of debate. Krishnan *et al.* theorized that septal pouches, which have access to the systemic circulation, comparable to the left atrial appendage, may serve as a site for thrombus formation and embolization especially during low flow states [5]. In fact, thrombi originating from aberrant spaces within the interatrial septum have been implicated in individual case reports of patients with coronary emboli and TIA [18]-[20]. Thrombi within accessory left atrial appendages and diverticula have been described in previous case reports as well [10] [13] [17]. Our findings do not show any association between diverticula and CVA or TIA. Consistent with several prior studies, our image analysis did not show evidence of thrombi within accessory appendages, diverticula or septal pouches [6] [7] [9] [12]. Nevertheless, given the high prevalence of LAAA, consideration of evaluation for thrombi within LAAA prior to electrophysiologic procedures may be useful for clinical management and risk reduction.

In the current study, patients who possess septal pouches and diverticula are statistically older than those patients without these abnormalities; no association with patient age is observed with accessory appendages. Our reported prevalence of septal pouches (38.4%) is within the range described in the literature (29.1% - 39%) [5] [24]. Our analysis has shown that patients with septal pouches are also more likely to be diabetic. The association between diabetes duration diastolic dysfunction has been shown [25]. Further, diastolic dysfunction has been frequently implicated in left atrial remodeling [26], which could explain the formation of septal pouches in older patients with diabetes. A possible explanation for diverticula being associated with increased age is that, similar to diverticula in other tissues, focal weaknesses in the atrial wall may develop over time. Unlike septal pouches and diverticula, no association is seen in the current study between accessory appendages and patient age. This finding provides further support to the several studies which have hypothesized an embryologic origin of these structures [9] [27].

This study is not without its limitations. Although CTCA is useful in distinguishing between the various LAAA, characterization of these structures was unable to be verified histopathologically. This being a retrospective study, ectopic activity was not individually assessed within each LAAA and was therefore determined by clinical history. Although our study was appropriately powered, it was limited by the availability and content of complete clinical histories. LAAA identified in our investigation were studied uniquely in patients undergoing CTCA. As a corollary, current findings may not reflect prevalence in the general population, and the presence of these anomalies in older patients may be due to selection bias. Previous studies have posited a congenital or embryologic origin for LAAA; however, the clinical associations of these structures have only been examined in adults. Their developmental history warrants further elucidation, as this knowledge will be invaluable to the complete clinical understanding of LAAA.

5. Conclusion

Accessory appendages, diverticula and septal pouches are highly prevalent anatomic abnormalities of the left atrium, increasingly identified by MDCT. The pectinate-lined accessory appendages have a high association with palpitations. Despite their blind-end morphology, no LAAA is associated with CVA or TIA. Septal pouches and diverticula are associated with increased patient age and, and septal pouches are additionally associated with a history of diabetes. Left atrial diverticula appear to be clinically benign. Further study of LAAA with larger prospective cohorts is warranted.

Acknowledgements

This study was funded by the Health Services Scholarship, awarded by The George Washington University School of Medicine and Health Sciences to author AVV.

References

- [1] Raff, G.L., Gallagher, M.J., O'Neill, W.W., et al. (2005) Diagnostic Accuracy of Noninvasive Coronary Angiography Using 64-Slice Spiral Computed Tomography. *Journal of the American College of Cardiology*, **46**, 552-557. <http://dx.doi.org/10.1016/j.jacc.2005.05.056>
- [2] Nikolaou, K., Flohr, T., Knez, A., et al. (2004) Advances in Cardiac CT Imaging: 64-Slice Scanner. *The International Journal of Cardiovascular Imaging*, **20**, 535-540. <http://dx.doi.org/10.1007/s10554-004-7015-1>
- [3] Balli, O., Aytemir, K. and Karcaaltincaba, M. (2012) Multidetector CT of Left Atrium. *European Journal of Radiology*, **81**, e37-e46. <http://dx.doi.org/10.1016/j.ejrad.2010.11.017>
- [4] Saremi, F. and Krishnan, S. (2007) Cardiac Conduction System: Anatomic Landmarks Relevant to Interventional Electrophysiologic Techniques Demonstrated with 64-Detector CT. *Radiographics*, **27**, 1539-1565. <http://dx.doi.org/10.1148/rg.276075003>
- [5] Krishnan, S.C. and Salazar, M. (2010) Septal Pouch in the Left Atrium: A New Anatomical Entity with Potential for Embolic Complications. *JACC: Cardiovascular Interventions*, **3**, 98-104. <http://dx.doi.org/10.1016/j.jcin.2009.07.017>
- [6] Abbara, S., Mundo-Sagardia, J.A., Hoffmann, U., et al. (2009) Cardiac CT Assessment of Left Atrial Accessory Appendages and Diverticula. *American Journal of Roentgenology*, **193**, 807-812. <http://dx.doi.org/10.2214/AJR.08.2229>
- [7] Duerinckx, A.J. and Vanovermeire, O. (2008) Accessory Appendages of the Left Atrium as Seen during 64-Slice Coronary CT Angiography. *The International Journal of Cardiovascular Imaging*, **24**, 215-221. <http://dx.doi.org/10.1007/s10554-007-9240-x>
- [8] Hoey, E.T., Nagra, I. and Ganeshan, A. (2011) Cardiac Aneurysms and Diverticula: Magnetic Resonance and Computed Tomography Appearances. *Current Problems in Diagnostic Radiology*, **40**, 72-84. <http://dx.doi.org/10.1067/j.cpradiol.2010.02.001>
- [9] Lazoura, O., Reddy, T., Shriharan, M., et al. (2012) Prevalence of Left Atrial Anatomical Abnormalities in Patients with Recurrent Atrial Fibrillation Compared with Patients in Sinus Rhythm Using Multi-Slice CT. *Journal of Cardiovascular Computed Tomography*, **6**, 268-273. <http://dx.doi.org/10.1016/j.jcct.2012.02.004>
- [10] Lee, W.J., Chen, S.J., Lin, J.L., et al. (2008) Accessory Left Atrial Appendage: A Neglected Anomaly and Potential Cause of Embolic Stroke. *Circulation*, **117**, 1351-1352. <http://dx.doi.org/10.1161/CIRCULATIONAHA.107.744706>
- [11] Wan, Y., He, Z., Zhang, L., Li, B.J., Sun, D.H., Fu, F., et al. (2009) The Anatomical Study of Left Atrium Diverticulum by Multi-Detector Row CT. *Surgical and Radiologic Anatomy*, **31**, 191-198. <http://dx.doi.org/10.1007/s00276-008-0427-1>
- [12] Troupis, J., Crossett, M., Schneider-Kolsky, M. and Nandurkar, D. (2012) Presence of Accessory Left Atrial Appendage/Diverticula in a Population with Atrial Fibrillation Compared with Those in Sinus Rhythm: A Retrospective Review. *The International Journal of Cardiovascular Imaging*, **28**, 375-380. <http://dx.doi.org/10.1007/s10554-011-9815-4>
- [13] Nagai, T., Fujii, A., Nishimura, K., Inoue, K., Suzuki, J., Kido, T., et al. (2011) Large Thrombus Originating from Left Atrial Diverticulum: A New Concern for Catheter Ablation of Atrial Fibrillation. *Circulation*, **124**, 1086-1088. <http://dx.doi.org/10.1161/CIRCULATIONAHA.110.000315>
- [14] Blackshear, J.L. and Odell, J.A. (1996) Appendage Obliteration to Reduce Stroke in Cardiac Surgical Patients with Atrial Fibrillation. *The Annals of Thoracic Surgery*, **61**, 755-759. [http://dx.doi.org/10.1016/0003-4975\(95\)00887-X](http://dx.doi.org/10.1016/0003-4975(95)00887-X)
- [15] Iwasaki, Y.K., Nishida, K., Kato, T. and Nattel, S. (2011) Atrial Fibrillation Pathophysiology: Implications for Management. *Circulation*, **124**, 2264-2274. <http://dx.doi.org/10.1161/CIRCULATIONAHA.111.019893>
- [16] Killeen, R.P., O'Connor, S.A., Keane, D. and Dodd, J.D. (2009) Ectopic Focus in an Accessory Left Atrial Appendage Radiofrequency Ablation of Refractory Atrial Fibrillation. *Circulation*, **120**, e60-e62. <http://dx.doi.org/10.1161/CIRCULATIONAHA.109.855569>
- [17] Naqvi, T.Z. and Zaky, J. (2004) Electric Dissociation within Left Atrial Appendage Diagnosed by Doppler Echocardiography. *Journal of the American Society of Echocardiography*, **17**, 1077-1079. <http://dx.doi.org/10.1016/j.echo.2004.05.008>
- [18] Breithardt, O.A., Papavassiliou, T. and Borggrefe, M. (2006) A Coronary Embolus Originating from the Interatrial Septum. *European Heart Journal*, **27**, 2745. <http://dx.doi.org/10.1093/eurheartj/ehl051>
- [19] Seyfert, H., Bohlscheid, V. and Bauer, B. (2008) Double Atrial Septum with Persistent Interatrial Space and Transient Ischaemic Attack. *European Journal of Echocardiography*, **9**, 707-708. <http://dx.doi.org/10.1093/ejehocard/jen161>
- [20] Gurudevan, S.V., Shah, H., Tolstrup, K., Siegel, R. and Krishnan, S.C. (2010) Septal Thrombus in the Left Atrium: Is the Left Atrial Septal Pouch the Culprit? *JACC: Cardiovascular Imaging*, **3**, 1284-1286. <http://dx.doi.org/10.1016/j.jcmg.2010.10.003>
- [21] Killeen, R.P., Ryan, R., MacErlane, A., Martos, R., Keane, D. and Dodd, J.D. (2010) Accessory Left Atrial Diverticu-

- lae: Contractile Properties Depicted with 64-Slice Cine-Cardiac CT. *The International Journal of Cardiovascular Imaging*, **26**, 241-248. <http://dx.doi.org/10.1007/s10554-009-9511-9>
- [22] Di Biase, L., Burkhardt, J.D., Mohanty, P., Sanchez, J., Mohanty, S., Horton, R., *et al.* (2010) Left Atrial Appendage: An Underrecognized Trigger Site of Atrial Fibrillation. *Circulation*, **122**, 109-118. <http://dx.doi.org/10.1161/CIRCULATIONAHA.109.928903>
- [23] Wu, T.J., Yashima, M., Xie, F., Athill, C.A., Kim, Y.-H., Fishbein, M.C., *et al.* (1998) Role of Pectinate Muscle Bundles in the Generation and Maintenance of Intra-Atrial Reentry: Potential Implications for the Mechanism of Conversion between Atrial Fibrillation and Atrial Flutter. *Circulation Research*, **83**, 448-462. <http://dx.doi.org/10.1161/01.RES.83.4.448>
- [24] Tugcu, A., Okajima, K., Jin, Z.Z., Rundek, T., Homma, S., Sacco, R.L., *et al.* (2010) Septal Pouch in the Left Atrium and Risk of Ischemic Stroke. *JACC: Cardiovascular Imaging*, **3**, 1276-1283. <http://dx.doi.org/10.1016/j.jcmg.2010.11.001>
- [25] From, A.M., Scott, C.G. and Chen, H.H. (2009) Changes in Diastolic Dysfunction in Diabetes Mellitus over Time. *American Journal of Cardiology*, **103**, 1463-1466. <http://dx.doi.org/10.1016/j.amjcard.2009.01.358>
- [26] Pritchett, A.M., Mahoney, D.W., Jacobsen, S.J., Rodeheffer, R.J., Karon, B.L. and Redfield, M.M. (2005) Diastolic Dysfunction and Left Atrial Volume: A Population-Based Study. *Journal of the American College of Cardiology*, **45**, 87-92. <http://dx.doi.org/10.1016/j.jacc.2004.09.054>
- [27] Lee, W.J., Chen, S.J. and Wang, T.D. (2008) Multiple Accessory Left Atrial Appendages along a Semi-Circular Path. *European Heart Journal*, **29**, 2447-2447. <http://dx.doi.org/10.1093/eurheartj/ehn144>

Scientific Research Publishing (SCIRP) is one of the largest Open Access journal publishers. It is currently publishing more than 200 open access, online, peer-reviewed journals covering a wide range of academic disciplines. SCIRP serves the worldwide academic communities and contributes to the progress and application of science with its publication.

Other selected journals from SCIRP are listed as below. Submit your manuscript to us via either submit@scirp.org or **Online Submission Portal**.

