

Protective Activity of Camel's Milk and Urine Mixture (*Camelus dromedarius*) against Ethanol-Induced Hepatotoxicity in Rats

Ahmed E. Elhag^{1,2}, F. Bernard³, Samia M. A. El Badwi^{2*}

¹Department of Preventive Medicine and Clinical Studies, Faculty of Veterinary Sciences, University of Gadarif, Al Gadarif, Sudan

²Department of Pharmacology and Toxicology, Faculty of Veterinary Medicine, University of Khartoum, Khartoum North, Sudan

³CIRAD-ES, Campus International de Baillarguet TA C/dir B, Montpellier, France

Email: *samiaelbadwi@yahoo.com

How to cite this paper: Elhag, A.E., Bernard, F. and El Badwi, S.M.A. (2017) Protective Activity of Camel's Milk and Urine Mixture (*Camelus dromedarius*) against Ethanol-Induced Hepatotoxicity in Rats. *Advances in Bioscience and Biotechnology*, 8, 378-387.

<https://doi.org/10.4236/abb.2017.810027>

Received: August 9, 2017

Accepted: October 13, 2017

Published: October 16, 2017

Copyright © 2017 by authors and Scientific Research Publishing Inc.

This work is licensed under the Creative Commons Attribution International License (CC BY 4.0).

<http://creativecommons.org/licenses/by/4.0/>



Open Access

Abstract

This study was implemented at the University of Khartoum to investigate the protective effect of camel milk mixed with camel urine against alcohol-induced liver damage in Wistar albino rats. The reasons for combining camel milk and urine together are because that in Sudan this combination is used extensively in traditional medicine and they claimed that this combination cures a lot of diseases including liver disease and jaundice; 25 Wister Albino rats of both sexes were brought and divided into 5 groups. Group 1 (control group) received normal saline, group 2 received ethanol 10% at dose of (0.5 g/100g body weight) and group 3 rats received Silymarin (5 mg/100g body weight) plus ethanol 10% (0.5 g/100g). Group 4 received a mixture of camel milk and urine (1:1) at the rate of 2 ml/100g and group 5 rats were administered with the mixture of camel's milk and urine as in group 4 plus ethanol 10% (0.5 g/100g). All treatments given by an oral intubation, experiment lasts for 28 days, rats were euthanized, serum samples and liver sections obtained. Oral administration of 10% ethanol (0.5 g/100g) induced liver damage which was clear in group 2 in a form of generalized necrosis, fatty change and congestion, beside high elevation of serum enzymes (AST, ALT, and ALP). Giving camel's milk and urine mixture to group 5 with ethanol 10% (0.5 g/100g), resulted in significant reduction of levels of serum enzymes (AST, ALT, and ALP) and in stabilization of serum metabolites (total protein, albumin and bilirubin). The degree of reduction was lower when significantly compared to (Silymarin + ethanol) group, and all results were verified by the histopathological changes. Hepatoprotective effects of camel's milk and urine mixture were recorded and this could be attributed to antioxidant activity or to its chelate effects on toxicants. Drinking raw camel milk and urine mixture,

it was used extensively in traditional medicine in Sudan and it was found safe without any ill effect.

Keywords

Camel Milk and Urine, Ethanol, Hepatoprotection, Rats

1. Introduction

Liver is the first organ to metabolize all foreign compounds and hence it's susceptible to many different disorders [1]. Among the compounds provoking such disorders, alcohol is one of the main causes of end-stage liver damage in a form of cellular necrosis and it is the second most common reason for liver transplantation in the United States [2]. Both acute and chronic ethanol consumption leads to formation of cytokines, especially TNF-alpha by hepatic Kupffer cells, the increase in tissue lipid peroxidation and the depletion in the tissue glutathione (GSH) [3], all this elements contributing to significant liver injury [4]. Moreover, alcoholic liver damages are related to the increase of serum levels of many biochemical markers like aspartate transaminase (AST), alanine transaminase (ALT), serum alkaline phosphatase (ALP), triglycerides, cholesterol and bilirubin [5].

In a context of low efficiency of available medical treatments for the liver protection from damage or help to regenerate hepatic cells, there is urgent need, therefore, for effective drugs to replace and supplement those in current use [6] [7] [8]. In spite of lack of clinical studies, camel milk and urine are regarded traditionally as a high quality drink and since ancient times people use them for curing a number of diseases [9] [10]. It has been reported that, the camel's milk and urine has been used to cure diseases caused by chronic imbalance of the liver [11] [12].

In-vivo, designed series of experiments in which mixture of camel urine and milk was given to Albino mice showed no effects on the normal liver and stomach [13], this indicated the biological effect of the mixture is safe product. Therefore, the aims of this study were to evaluate the protective effect of the mixture of camel's milk and urine on alcohol-induced hepatotoxicity in rats and to make more considerable pharmacological and clinical investigation on the therapeutic activity of this mixture.

2. Materials and Methods

2.1. Experimental Animals

25 Wistar albino rats of both sexes weighing 85 - 105 g were used. They were obtained from the Animal House of the Veterinary Research Institute, Animal Resources Research Corporation, Soba, Khartoum. Rats kept within the premises of the Department of Pharmacology and Toxicology, Faculty of Veterinary

Medicine, University of Khartoum. After one week adaptation period, housed in cages, maintained in a light room under normal environmental conditions with temperature ($28^{\circ}\text{C} \pm 2^{\circ}\text{C}$) plus relative humidity (61%), with free access to water and food, they were divided into 5 groups. All rats were apparently healthy and identified by color tail marks. The research was carried out according to the rules governing the use of laboratory animals as acceptable international.

2.2. Collection of Camel's Milk and Urine

Fresh milk was collected from female camels of different ages and lactation periods during early morning milking time, while fresh urine from young female camels (Bekra) (6 month up to 3 years old) was collected early morning during normal urination from Camel Research Centre, University of Khartoum, this was done daily for 28 days during all experiment period.

2.3. Experimental Design

The rats were divided into 5 groups of 5 rats each:

- 1) Control rats (group 1) received normal saline orally;
- 2) Ethanol group (group 2) received orally ethanol 10% only at a dose of 0.5 g/100g body weight as single dose/day;
- 3) Ethanol plus Silymarin rats (group 3) received orally Silymarin as a hepatoprotective drug (5 mg/100g body weight), and after 3 hours received ethanol 10% (0.5 g/100g body weight);
- 4) Mixture of Camel's milk and Camel's urine (CMCU) rats (group 4) received camel's milk (CM) and urine (CU) (1:1) at the rate of 2 ml/100g by an oral intubation;
- 5) Ethanol plus CMCU rats (group 5) were administered with the mixture of camel's milk and urine as same in group 4 and after 3 hours received orally ethanol 10% (0.5 g/100g).

All treatments were continued for 28 days.

2.4. Serum Enzymes and Serum Metabolites

Blood samples were collected from the orbital plexus of rats on days zero, 15 and 29 of the experiment. The markers of liver damages as aspartate aminotransferase (AST), alanine amino transferase (ALT) and alkaline phosphatase (ALP) were determined [14]. In addition, serum total protein, albumin and bilirubin concentrations were also determined [15]. All samples were analyzed by using commercial kits (Randox Laboratories Ltd., U.K.).

2.5. Histopathological Methods

Clinical signs were recorded and the postmortem examination was carried after slaughtering of the rats at day 29. Then 25 livers specimens were collected and fixed in 10% buffered formal saline, and transported to laboratory for histopathological processing and investigations. Specimens embedded in paraffin wax

sectioned at 5 μm and stained routinely with Hematoxylin and Eosin (H & E) using Mayer's Hemalum.

2.6. Statistical Analysis

Data were entered and analyzed using SAS statistical package. Numerical data were expressed as means and standard errors. Significance of difference between means were tested by one-way ANOVA, depending on the number of compared groups; with a p value of ≤ 0.05 considered statistically significant [16].

3. Results

3.1. Clinical Signs

There were no abnormal clinical signs in all groups except Ethanol rats (group 2) where the rats presented depression and general unthriftiness from day 13 throughout.

3.2. Postmortem Findings

Regarding the pathological lesions of liver, the rats from Ethanol group showed fatty changes, slight congestion and adhesion in lobes, while in group 4 (CMCU group) and Ethanol plus CMCU group, no postmortem changes were observed. A slight fatty change of liver with grey spots was observed in Ethanol plus Silymarin group.

3.3. Changes in Serum Enzymes

Table 1, demonstrated the changes in serum enzymes as; in intoxicated rats (group 2), the activities of enzymes AST, ALT and ALP were significantly increased when compared to the untreated control groups while the administration of camel's milk and urine CMCU to intoxicated rats (group 5) resulted in significant amelioration of the levels of the enzymes AST, ALT, and ALP, when compared to the group treated with ethanol (group 2). Moreover, this improvement is higher in Ethanol plus CMCU rats (group 5) than in rats treated with Silymarin and ethanol (group 3).

3.4. Changes in Serum Metabolites Parameters

Table 2 showed the changes in serum metabolites in treated groups which revealed that, in rats treated with ethanol only (group 2) the concentration of total protein, albumin and bilirubin were significantly increased when compared to the untreated control group 1. Administration of camel milk and urine CMCU to intoxicated rats (group 4) resulted in significant fall in the concentration of total protein, albumin and bilirubin, when compared to the group treated with ethanol (group 2) even more than Ethanol plus Silymarin rats (group 3).

3.5. Histopathological Changes

As showed in **Figures 1(a)-(d)**, no pathological changes were observed in con-

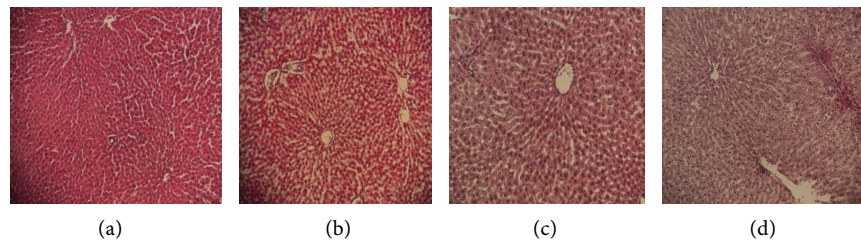


Figure 1. Histopathological changes in livers of rats treated with ethanol, camel milk and urine plus Silymarin (Arrows indicate the followings): (a) = Section of liver cells of Ethanol rats (Group 2) (10% ethanol at 5 g/kg), showing centrilobular necrosis and lymphocytic infiltration; (b) = Section of liver cells of CMCU rats (Group 4) treated with mixture of camel milk and urine at “2 ml/100gm B. W.”, showing almost normal architecture; (c) = Section of liver cells of Ethanol/CMCU rats (Group 5) which treated with mixture of camel milk & urine at “2 ml/100gm”. + 10% ethanol 5 g/kg, showing slight fatty change & lymphocytic infiltration; (d) = Section of liver cells of Ethanol/Silymarin rats (Group 3) treated with Silymarin at 50 mg/kg + 10% ethanol at 5 g/kg, showing generalized fatty change.

Table 1. Changes in serum enzymes in rats treated with mixture of camel milk and urine against ethanol induced-liver damage.

Groups	AST (SGOT) U/I (Means \pm S.E)		
	Day Zero	Day 15	Day 29
Control rats (Group 1)	39.34 \pm 1.23 a	37.26 \pm 1.15 c	38.4 \pm 0.98 c
Ethanol rats (Group 2)	38.02 \pm 1.71ab	63.8 \pm 3.02 a	62.6 \pm 2.01 a
Ethanol/Silymarin rats (Group 3)	35.34 \pm 0.83 b	53.2 \pm 1.98 b	54.2 \pm 2.27 b
CMCU rats (Group 4)	36.02 \pm 0.68ab	38.08 \pm 1.37 c	37.4 \pm 0.87 c
Ethanol/CMCU rats (Group 5)	35.34 \pm 0.83b	51.8 \pm 2.06 b	50.4 \pm 1.69 b
Groups	ALT (SGPT) U/I (Means \pm S.E)		
	Day Zero	Day 15	Day 29
Control rats (Group 1)	5 \pm 1.14 a	6 \pm 0.71 c	6.4 \pm 0.51 c
Ethanol rats (Group 2)	4.6 \pm 0.75 a	15.4 \pm 0.87 a	16.8 \pm 0.86 a
Ethanol/Silymarin rats (Group 3)	3.4 \pm 0.68 a	14.8 \pm 0.37 a	16.2 \pm 0.37 a
CMCU rats (Group 4)	4.6 \pm 0.74 a	5.4 \pm 0.93 c	5.6 \pm 0.51 c
Ethanol/CMCU rats (Group 5)	2.6 \pm 0.24 a	12.6 \pm 0.68 b	14.2 \pm 0.37 b
Groups	(ALP) U/I (Means \pm S.E)		
	Day Zero	Day 15	Day 29
Control rats (Group 1)	80.4 \pm 2.06 a	76.2 \pm 1.39 bc	76.2 \pm 1.24 b
Ethanol rats (Group 2)	79.2 \pm 1.16 a	79.4 \pm 0.51 a	79.8 \pm 0.66 a
Ethanol/Silymarin rats (Group 3)	79.8 \pm 1.16 a	78 \pm 0.70 ab	77.8 \pm 0.37 ab
CMCU rats (Group 4)	78.4 \pm 1.44 a	77 \pm 0.71 abc	76.8 \pm 0.58 b
Ethanol/CMCU rats (Group 5)	77.6 \pm 0.93 a	74.8 \pm 0.37 c	76.2 \pm 0.37 b

Group 1 (Control); Group 2 (10% Ethanol at 5 g/kg); Group 3 (Silymarin at 50 mg/kg + 10% Ethanol at 5 g/kg); Group 4 (1:1 mixture of camel milk and urine at “2 ml/100gm B. W.”); Group 5 (1:1 mixture of camel milk and urine at “2 ml/100gm B. W.” + 10% Ethanol at 5 g/kg). Values are means \pm standard errors. Means in the same column with the same letters are not significantly different. ($P < 0.05$).

Table 2. Changes in serum metabolites concentration of rats treated with mixture of camel milk and urine against ethanol induced-liver damage.

Groups	Total protein g/dl (Means \pm S.E)		
	Day zero	Day 15	Day 29
Control rats (Group 1)	5.5 \pm 0.17 a	5.26 \pm 0.14 b	5.26 \pm 0.15 c
Ethanol rats (Group 2)	5.46 \pm 0.12 a	5.66 \pm 0.09 a	5.7 \pm 0.07 a
Ethanol/Silymarin rats (Group 3)	5.58 \pm 0.09 a	5.66 \pm 0.09 a	5.6 \pm 0.05 ab
CMCU rats (Group 4)	5.58 \pm 0.10 a	5.36 \pm 0.10 ab	5.36 \pm 0.05 bc
Ethanol/CMCU rats (Group 5)	5.6 \pm 0.05 a	5.5 \pm 0.07 ab	5.42 \pm 0.06 bc

Groups	Albumin g/dl (Means \pm S.E)		
	Day Zero	Day 15	Day 29
Control rats (Group 1)	2.78 \pm 0.10 a	2.34 \pm 0.15 b	2.48 \pm 0.14 bc
Ethanol rats (Group 2)	2.58 \pm 0.13 a	2.74 \pm 0.07 a	2.76 \pm 0.05 a
Ethanol/Silymarin rats (Group 3)	2.6 \pm 0.07 a	2.72 \pm 0.07 a	2.7 \pm 0.05 ab
CMCU rats (Group 4)	2.68 \pm 0.10 a	2.5 \pm 0.12 ab	2.42 \pm 0.06 c
Ethanol/CMCU rats (Group 5)	2.6 \pm 0.05 a	2.6 \pm 0.07 ab	2.5 \pm 0.05 bc

Groups	Billirubin mg/dl (Means \pm S.E)		
	Day Zero	Day 15	Day 29
Control rats (Group 1)	0.58 \pm 0.13 a	0.3 \pm 0.07 b	0.22 \pm 0.04 c
Ethanol rats (Group 2)	0.4 \pm 0.15 ab	0.54 \pm 0.05 a	0.56 \pm 0.05 a
Ethanol/Silymarin rats (Group 3)	0.28 \pm 0.13 ab	0.38 \pm 0.04 b	0.46 \pm 0.05 ab
CMCU rats (Group 4)	0.14 \pm 0.02 b	0.3 \pm 0.04 b	0.28 \pm 0.04 c
Ethanol/CMCU rats (Group 5)	0.32 \pm 0.15 ab	0.32 \pm 0.04 b	0.34 \pm 0.02 bc

Group 1 (Control); Group 2 (10% Ethanol at 5 g/kg); Group 3 (Silymarin at 50 mg/kg + 10% Ethanol at 5 g/kg); Group 4 (1:1 mixture of camel milk and urine at "2 ml/100gm B. W."); Group 5 (1:1 mixture of camel milk and urine at "2 ml/100gm B. W." + 10% Ethanol at 5 g/kg). Values are means \pm standard errors. Means in the same column with the same letters are not significantly different. ($P < 0.05$).

trol group while liver damage was seen in a form of centrilobular necrosis and lymphocytic infiltration in Ethanol groups. In CMCU rats there was almost normal architecture. In Ethanol plus CMCU group, there was slight fatty change and lymphocytic infiltration, while in Ethanol plus Silymarin group there was generalized fatty change.

4. Discussion

In the current study in which we used the ethanol as a model for chronic hepatotoxicity in rats, a high increase in serum activities of liver enzymes AST, ALT, ALP and metabolites as total protein, albumin and bilirubin in rats treated with ethanol 10%, was recorded indicating that the dose of 0.5 g/100g can produce chronic liver toxicity, this finding was confirmed by histopathological finding as centrilobular necrosis and lymphocytic infiltration (**Figure 1(a)**). Our results

were similarly consistent with the findings of many authors who reported that, alcohol (10% ethanol) intoxication significantly increased AST and ALT besides arising of the histopathology of hepatic injury [17]. Also, they indicated that exposure of hepatocytes to ethanol alters the membrane structure and functions by increasing the leakage of enzymes into the circulation [18]. On the other hand, some of them reported that, excess alcohol consumption has been linked with altered liver metabolism and liver damage [19]. At reverse, the results obtained by others found a decrease in serum total proteins and albumin in ethanol administered rats [20]. They suggested that this decrease was due to a reduction in the functional ability of liver by ethanol.

In our study treated rats showed, a decrease in serum activities of liver enzymes AST, ALT, ALP besides fall in levels of serum total protein, albumin and bilirubin, maintained near the normal range, especially in rats treated with camel's milk and urine plus alcohol. The degree of reduction was much lower than Ethanol plus Silymarin group. This could indicate improvement of liver function and protection from alcohol toxicity. The same results were reached by using camel's milk only as protection against CCL4 liver damage protocol instead of using alcohol [21]. Our findings were confirmed by detection of necrosis, apoptosis, fatty accumulation and inflammatory cells infiltration on histological findings in ethanol treated group, and clearly alleviated in protected rats by camel's milk and urine CMCU (groups 4) while there were no pathological changes in group 5. These results were in agreement with those who suggested that camel's milk intake may play an important role in ameliorating alcoholic liver injury after using ethanol 56% at a dose of 6 g/kg/day [22], and also with the others who investigated the effects of camel's milk on improving the hepatic biochemical and cellular alterations induced by a high-fat, cholesterol-rich diet [23]. The same findings were obtained from our previous study with camel's urine alone against alcohol induced liver damage in rats [24]. Protection of the liver from chemical injuries was produced by different agents such as herbs as it was reported by many authors who found that if the rats pre-treated with some herbal extracts against CCL4 or paracetamol instead of camel's milk and urine against ethanol 10%, that will significantly controlled the changes in the biochemical parameters, and exhibited a sharp decrease of the levels in the serum enzymes indicators of suffering liver [25]-[30]. Also similar results obtained by using montelukast sodium (Cysteinyl-leukotriene type 1 selective receptor antagonist) as hepatoprotective instead of camel's milk and urine [31].

The hepatoprotective effects of camel's milk and urine could be attributed to its possible chelating effects on toxicants specially alcohol [32], or to the high levels of Vitamins C, B2, E, magnesium and other trace elements on camel's milk and urine which may play a major role as antioxidants [33] and found to be useful in preventing the tissues injury caused by toxic agent [34]. The biological function of camel urine was supported in literature by many researchers [35] [36] [37] [38].

5. Conclusion

The oral administration of ethanol by a dose of 0.5 g/100g induced chronic damage of liver cells which was manifested biochemically in rats. Camel's milk and urine CMCU induced significant decreases in serum enzymes, indicators of liver suffering, testifying of a certain hepato-protective effect against chronic toxicity induced by ethanol even higher than using the reference drug (Silymarin). However, further studies are necessary, especially clinical investigations in order to confirm the potential effect of camel's milk mixed with urine as beneficial drink for the prevention of chronic liver toxicity. We recommend for future work purifying the macromolecules involved in the protective activity of camel milk and urine mixture, and test the protective effect for the purified portion.

Conflict of Interest

The authors declare that there are no conflicts of interest.

Authors' Contributions

Ahmed E. Elhag and Samia M. A. El Badwi carried out the whole experiment including the lab, and data analysis in Sudan, Bernard Faye contributed in writing the manuscript and publication process. All authors critically reviewed the data and the manuscript.

References

- [1] Sarkar, M.K., Sarkar, K., Bhattacharjee, R., Chatterjee, M. and Sil, P.C. (2005) Curative Role of the Aqueous Extract of the Herb, *Phyllanthus niruri*, against Nimesulide Induced Oxidative Stress in Murine Liver. *Biomedical Research*, **16**, 171-176.
- [2] Mandayam, S., Jamal, M.M. and Morgan, T.R. (2004) Epidemiology of Alcoholic Liver Disease. *Seminars in Liver Disease Journal*, **24**, 217-232. <https://doi.org/10.1055/s-2004-832936>
- [3] Sandy, O. and Ben, H.C. (1998) The Effects of Glutathione Glycoside in Acetaminophen-Induced Liver Cell Necrosis. *Experimental and Molecular Pathology Journal*, **65**, 15-24. <https://doi.org/10.1006/exmp.1998.2221>
- [4] Zakhari, S. and Li, T.K. (2007) Determinants of Alcohol Use and Abuse: Impact of Quantity and Frequency Patterns on Liver Disease. *Hepatology Journal*, **46**, 2032-2039. <https://doi.org/10.1002/hep.22010>
- [5] Lu, Y. and Cederbaum, A.I. (2008) CYP2E1 and Oxidative Liver Injury by Alcohol. *Free Radical Biology and Medicine Journal*, **44**, 723-738. <https://doi.org/10.1016/j.freeradbiomed.2007.11.004>
- [6] Lee, C.H., Park, S.W., Kim, Y.S., Kang, S.S., Kim, J.A., Lee, S.H. and lee, S.M. (2007) Protective Mechanism of Glycyrrhizin on Acute Liver Injury Induced by Carbon Tetra Chloride in Mice. *Biological and Pharmaceutical Bulletin Journal*, **30**, 1898-1904. <https://doi.org/10.1248/bpb.30.1898>
- [7] Chattopadhyay, R.R. (2003) Possible Mechanism of Hepatoprotective Activity of *Azadirachta indica* Leaf Extract: Part II. *Journal of Ethnopharmacology*, **89**, 217-219. <https://doi.org/10.1016/j.jep.2003.08.006>
- [8] Adewusi, E.A. and Afolayan, A.J. (2010) A Review of Natural Products with Hepa-

toprotective Activity. *Journal of Medicinal Plants Research*, **4**, 1318-1334.

- [9] Shabo, Y., Barzel, R., Margoulis, M. and Yagil R. (2005) Camel Milk for Food Allergies in Children. *Israel Medical Association Journal*, **7**, 796-259.
- [10] Redwan, R.M. and Tabll, A. (2007) Camel Lactoferrin Markedly Inhibits Hepatitis C Virus Genotype 4 Infection of Human Peripheral Blood Leucocytes. *Journal of Immunoassay Immunochemistry*, **28**, 267-277.
<https://doi.org/10.1080/15321810701454839>
- [11] Haddad, G.F. (2006) Camel's Milk and Urine Hadiths.
- [12] AL-Hashem, F. (2009) Camel Milk Protects against Aluminum Chloride-Induced Toxicity in the Liver and Kidney of White Albino Rats. *American Journal of Biochemistry and Biotechnology*, **5**, 98-108. <https://doi.org/10.3844/ajbbsp.2009.98.108>
- [13] EL-Elyani, R.A. and Khalifa, S.A.M. (2006) Histological Studies on the Effect of Camel's Urine and Milk on Stomach of Albino Mice. *Saudi Journal of Biological Sciences*, **13**, 2.
- [14] Young, D.S. (1990) Effects of Drugs on Clinical Laboratory Tests. 3rd Edition, AACC Press, Washington DC, 6-12.
- [15] Stein, E.A. (1986) Text Book of Clinical Chemistry. Tietz, N.W., Ed., W.B. Saunders Company, Philadelphia, 879-886.
- [16] Mendenhall, W. (1971) Introduction to Probability and Statistics. 3rd Edition, Wadsworth Publishing Company, Belmont, California, 35-38.
- [17] Yoo, J.-H., Kang, K., Yun, J.H., Kim, M.A. and Nho, C.W. (2014) *Crepidiastrum denticulatum* Extract Protects the Liver against Chronic Alcohol-Induced Damage and Fat Accumulation in Rats. *Journal of Medicinal Food*, **17**, 432-438.
<https://doi.org/10.1089/jmf.2013.2799>
- [18] Rajakrishnan, V. and Menon, V.P. (2001) Potential Role of Antioxidants during Ethanol Induced Changes in the Fatty Acid Composition and Arachidonic Acid Metabolites in Male Wistar Rats. *Cell Biology and Toxicology Journal*, **17**, 11-22.
<https://doi.org/10.1023/A:1010998929785>
- [19] Das, D., Mukherjee, M.M., Das, A.S. and Mitra, C. (2005) Aqueous Extract of Black Tea *Camellia sinensis* Prevents Chronic Ethanol Toxicity. *Current Science Journal*, **88**, 952-961.
- [20] Ahmed, B., Alam, T., Varshney, M. and Khan, S.A. (2002) Hepatoprotective Activity of Tow Plants Belonging to the *Apiaceae* and the *Euphorbiaceae* Family. *Journal of Ethnopharmacology*, **79**, 313-316.
[https://doi.org/10.1016/S0378-8741\(01\)00392-0](https://doi.org/10.1016/S0378-8741(01)00392-0)
- [21] Khan, A.A. and Alzohairy, M.A. (2011) Hepatoprotective Effects of Camel Milk against CCL4 Induced Hepatotoxicity in Rats. *Asian Journal of Biochemistry*, **6**, 171-180. <https://doi.org/10.3923/ajb.2011.171.180>
- [22] Darwish, H.A., Abd Raboh, N.R. and Mahdy, A. (2012) Camel's Milk Alleviates Alcohol-Induced Liver Injury in Rats. *Food and Chemical Toxicology*, **50**, 1377-1383.
<https://doi.org/10.1016/j.fct.2012.01.016>
- [23] Korish, A. and Arafah, M. (2013) Camel Milk Ameliorates Steatohepatitis, Insulin Resistance and Lipid Peroxidation in Experimental Non-Alcoholic Fatty Liver Disease. *BMC Complementary and Alternative Medicine*, **13**, 264-276.
<https://doi.org/10.1186/1472-6882-13-264>
- [24] Elhag, A.E., El Badwi, S.M.A. and Mustafa, A.B. (2016) Hepatoprotective Effect of Urine of One-Humped Camel (*Camelus dromedarius*) against Ethanol Induced Liver Damage in Rats. *International Journal of Pharmaceutical Chemistry*, **5**, 1-8.

- [25] Kumar, S.S., Kumar, B.R. and Mohan, G.K. (2009) Hepatoprotective Effect of *Trichosanthes cucumerina* Var *cucumerina* L. on Carbon Tetrachloride Induced Liver Damage in Rats. *Journal of Ethnopharmacology*, **123**, 347-350. <https://doi.org/10.1016/j.jep.2009.02.023>
- [26] Shen, X., Tang, Y., Yang, R., Yu, L., Fang, T. and Duan, J.A. (2009) The Protective Effect of *Zizyphus jujube* Fruit on Carbon Tetrachloride-Induced Hepatic Injury in Mice by Anti-Oxidant Activities. *Journal of Ethnopharmacology*, **122**, 555-560. <https://doi.org/10.1016/j.jep.2009.01.027>
- [27] Elhag, R.A.M., El Badwi, S.M.A., Bakhiet, A.O. and Galal, M. (2011) Hepatoprotective Activity of *Solanum nigrum* Extracts on Chemically Induced Liver Damage in Rats. *Journal of Veterinary Medicine and Animal Health*, **3**, 45-50
- [28] Ali, S.A.M., El Badwi, S.M.A., Idris, T.M. and Osman, K.M. (2011). Hepatoprotective Activity of Aqueous Extract of *Khaya senegalensis* Bark in Rats. *Journal of Medicinal Plant Research*, **5**, 5863-5866.
- [29] El Badwi, S.M.A., El Bagir, N.M. and Amin, A.E. (2013) Protective Effect of Ethanol Extract of *Tamarindus indica* against CCl₄ Induced Liver Damage in Rats. *Australian Journal of Basic and Applied Sciences*, **7**, 813-818.
- [30] Mohamed, H.S.A.A., Abdelgadir, W.S. and El Badwi, S.M.A. (2015) Hepatoprotective Activity of the Ethanol Extract of *Cassia obtusifolia* Seeds Against Paracetamol-Induced Liver Damage in Rats. *European Journal of Pharmaceutical and Medical Research*, **1**, 277-289.
- [31] Cuciureanu, M., Caruntu, I.D., Paduraru, O., Stoica, B., Jerca, L., Crauciuc, E. and Nechifor, M. (2009) The Protective Effect of *Montelukast sodium* on Carbon Tetrachloride Induced Hepatopathy in Rats. *Prostaglandins Other Lipid Mediat*, **88**, 82-88. <https://doi.org/10.1016/j.prostaglandins.2008.10.004>
- [32] Zhang, H., Yao, J., Zhao, D., Liu, H., Li, J. and Guo, M. (2005) Changes in Chemical Composition of Alxa Bactrian Camel Milk during Lactation. *Journal of Dairy Science*, **88**, 3402-3410. [https://doi.org/10.3168/jds.S0022-0302\(05\)73024-1](https://doi.org/10.3168/jds.S0022-0302(05)73024-1)
- [33] AL-Humaid, A.I., Mousa, H.M., El-Mergawi, R.A. and Abdel-Salam, A.M. (2010) Chemical Composition and Antioxidant Activity of Dates and Camel Milk Mixtures as a Protective Meal against Lipid Peroxidation in Rats. *American Journal of Food Technology*, **5**, 98-108. <https://doi.org/10.3923/ajft.2010.22.30>
- [34] Knoess, K.H. (1979) Milk Production of the Dromedary. *Proceeding of the IFS Symposium on Camels*, Khartoum, 18-20 December 1979, 201-214.
- [35] Al-Yousef, N., Gaafar, A., Al-Otaibi, B., Al-Jammaz, I., Al-Hussein, K. and Abousekhra, A. (2012) Camel Urine Components Display Anti-Cancer Properties *in Vitro*. *Journal of Ethnopharmacology*, **143**, 819-825. <https://doi.org/10.1016/j.jep.2012.07.042>
- [36] Alhaider, A.A., Abdel Gader, A.M. and Mousa, S.A. (2011) The Antiplateletive Properties of Camel Urine. *The Journal of Alternative and Complementary Medicine*, **17**, 803e808.
- [37] Alhaider, A.A., Abel Gader, A.G.M., Almeshal, N. and Saraswati, S. (2014) Camel Urine Inhibits Inflammatory Angiogenesis in Murine Sponge Implant Angiogenesis Model. *Biomed Aging Pathology*, **4**, 9-16. <https://doi.org/10.1016/j.biomag.2013.10.003>
- [38] Alhaider, A.A., El Gendy, M.A., Korashy, H.M. and El-Kadi, A.O. (2011) Camel Urine Inhibits the Cytochrome P450 1a1 Gene Expression through an AhR-Dependent Mechanism in Hepa 1c1c7 Cell Line. *Journal of Ethnopharmacology*, **133**, 184-190. <https://doi.org/10.1016/j.jep.2010.09.012>